



Isavuconazole shortens the QTc interval

Sibylle C. Mellinshoff^{1,2}  | Matteo Bassetti³ | Daniela Dörfel^{4,5} | Stefan Hagel⁶  |
Nicola Lehnert⁷  | Andrzej Plis⁸ | Enrico Schalk⁹  | Antonio Vena³  |
Oliver A. Cornely^{1,2,10} 

¹Cologne Excellence Cluster on Cellular Stress Responses in Aging-Associated Diseases (CECAD), University of Cologne, Cologne, Germany

²Department I of Internal Medicine, German Centre for Infection Research (DZIF), University of Cologne, Cologne, Germany

³Infectious Diseases Division, Santa Maria Misericordia University Hospital, Udine, Italy

⁴Department of Medical Oncology, Hematology, Immunology, Rheumatology and Pulmology, University Hospital Tübingen, Tübingen, Germany

⁵Clinical Collaboration Unit Translational Immunology, German Cancer Consortium (DKTK) and German Cancer Research Center (DKFZ), Partner site Tübingen, Tübingen, Germany

⁶Centre for Infectious Diseases and Infection Control, Jena University Hospital, Jena, Germany

⁷Department V of Internal Medicine, University Hospital Heidelberg, Heidelberg, Germany

⁸Department of Haematology, Oncology, Palliative Medicine and Transplantation Centre, University Hospital in Greifswald, Greifswald, Germany

⁹Department of Haematology and Oncology, Medical Centre, Otto-von-Guericke University Magdeburg, Magdeburg, Germany

¹⁰Clinical Trials Centre Cologne (ZKS Köln), University of Cologne, Cologne, Germany

Correspondence

Sibylle C. Mellinshoff, MD, Department I for Internal Medicine, University Hospital of Cologne, Cologne, Germany.
Email: sibylle.mellinshoff@uk-koeln.de

Summary

Isavuconazole is a novel antifungal drug approved for the treatment of adults with invasive aspergillosis and mucormycosis. While azoles as a class effect are known to prolong QTc interval, clinical trials have shown that isavuconazole administration may cause shortening in a dose-related manner. Here, we assessed the effects of isavuconazole on the length of QTc interval. The objective of the study was to describe changes in the QTc interval induced by isavuconazole treatment. A total of 26 adult patients from 7 hospitals were included. Patients received isavuconazole for the treatment of invasive fungal infection and, in 1 case, for prophylaxis due to QTc prolongation under fluconazole. Twelve-channel electrocardiograms (ECGs) were performed before and during treatment. Out of 26 patients, 24 showed shortening of QTc interval. In patients with QTc shortening, QTc during isavuconazole treatment showed a mean decrease of $7.4 \pm 5.8\%$ (36.5 ± 38.8 ms, range 7-202; $P = .004$), compared to pre-isavuconazole ECG. One patient with available long-term follow-up showed further decrease in QTc on days 55 and 110. Apart from 1 case report, these are the first data outside controlled clinical trials showing QTc shortening. Knowledge about cardiac effects of isavuconazole will serve to better manage the use of concomitant medications.

KEYWORDS

corrected QT, electrocardiogram, invasive fungal disease, isavuconazole

1 | INTRODUCTION

Isavuconazole is a novel antifungal drug used for the treatment of invasive aspergillosis and mucormycosis in adults. The drug has been approved by the US and the European regulatory agencies in 2016. While azoles as a class effect are known to prolong QTc interval,¹⁻³ clinical trials have shown that isavuconazole administration may shorten QTc interval in a dose-related manner.^{4,5}

The QT interval is a measure of time in electrocardiograms (ECGs) and describes the duration of the cellular action potential.⁶ Due to its variation with heart rate, the QT interval must be corrected before interpretation. Bazett's formula is most commonly applied for this purpose: the QT interval is divided by square root of the RR interval. The upper limit of normal corrected QT (QTc) interval by Bazett is 480 ms for both males and females.⁷ QTc increases with age, health status, for example, epilepsy⁸ and diabetes mellitus,⁹ and electrolyte abnormalities,¹⁰ putting patients at risk of arrhythmia, most notably torsade de pointes tachycardia.

Here, we assessed the effect of isavuconazole on the QTc interval in 26 patients with invasive fungal diseases.

2 | PATIENTS AND METHODS

We observed 26 adult patients from 7 academic hospitals of maximum care (6 German, 1 Italian). Patients received isavuconazole for the treatment of invasive fungal infection (IFI) and, in 1 case, for prophylaxis due to QTc prolongation under fluconazole. Twelve-channel ECGs were performed before and during treatment.

Data on IFI, underlying disease, co-medication and electrolytes were obtained from electronic health records. Determining the QT interval adjusted to heart rate (QTc), the Bazett's correction formula ($QTc = QT/\sqrt{RR}$) was used for all calculations.⁶

Patients received isavuconazole according to the manufacturer's instruction. One ECG was performed before isavuconazole treatment initiation; a second ECG was performed in median 10 days (range 1-46 days) after start of treatment. One patient was followed up in the long term, that is, on days 19, 55 and 110.

The Student's *t* test was used to test whether the means in each set of values differed significantly, assuming 2 possible tails as well as unequal variance. A $P < .05$ was defined as statistically significant. Values depict the means \pm standard deviation.

3 | RESULTS

A total of 26 patients treated with isavuconazole were observed. Underlying conditions of the patients included haematological malignancies (acute and chronic leukaemia, lymphoma, myelodysplastic syndrome), prior allogeneic haematopoietic stem cell or solid organ transplantation (lung) and other non-malignant chronic diseases, that is, diabetes and chronic obstructive pulmonary disease. Two patients did not have any underlying disease. Four patients had

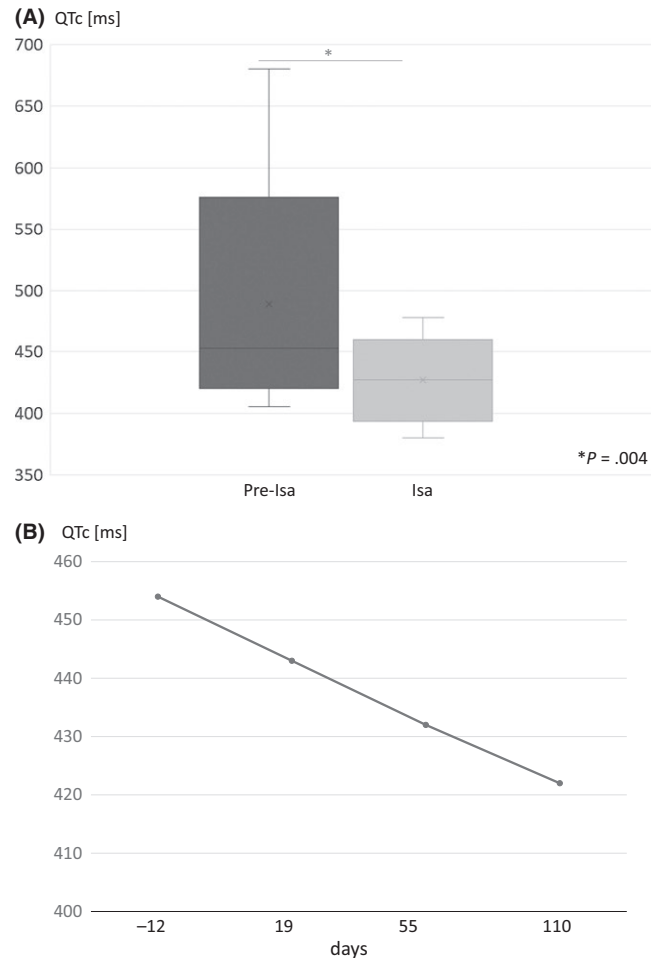


FIGURE 1 QTc pre- and under isavuconazole administration. A, QTc changes in 26 patients before (pre-Isa) and under treatment with isavuconazole (Isa). B, QTc intervals in a patient with long-term isavuconazole treatment

proven mucormycosis, 14 patients had proven/probable pulmonary invasive aspergillosis, 1 patient had an aspergilloma, 3 patients had a suspected pulmonary IFI without mycological evidence, 1 had IFI of the central nervous system and 2 patients were treated for candidiasis.

While 24 out of 26 patients showed a shortening of the QTc interval, no changes were found in 2 patients. In those patients with QTc shortening, QTc during isavuconazole treatment showed a mean decrease of $7.4 \pm 5.8\%$ (36.5 ± 38.8 ms, range 7-202 ms; $P = .004$), compared to pre-isavuconazole ECG (Figure 1). One patient, followed up in the long term, showed further decrease in QTc on days 55 and day 110 (Figure 2).

All patients received several drugs as co-medication, whereas only 7 received co-medication known to influence the QTc in terms of prolongation (amiodarone, pentamidine, tacrolimus). Except for 1 case, patients received the drugs continuously before as well as under treatment with isavuconazole. In this single case, treatment with tacrolimus was initiated for graft-vs-host disease at day 50 following allogeneic haematopoietic stem cell transplantation. Eight

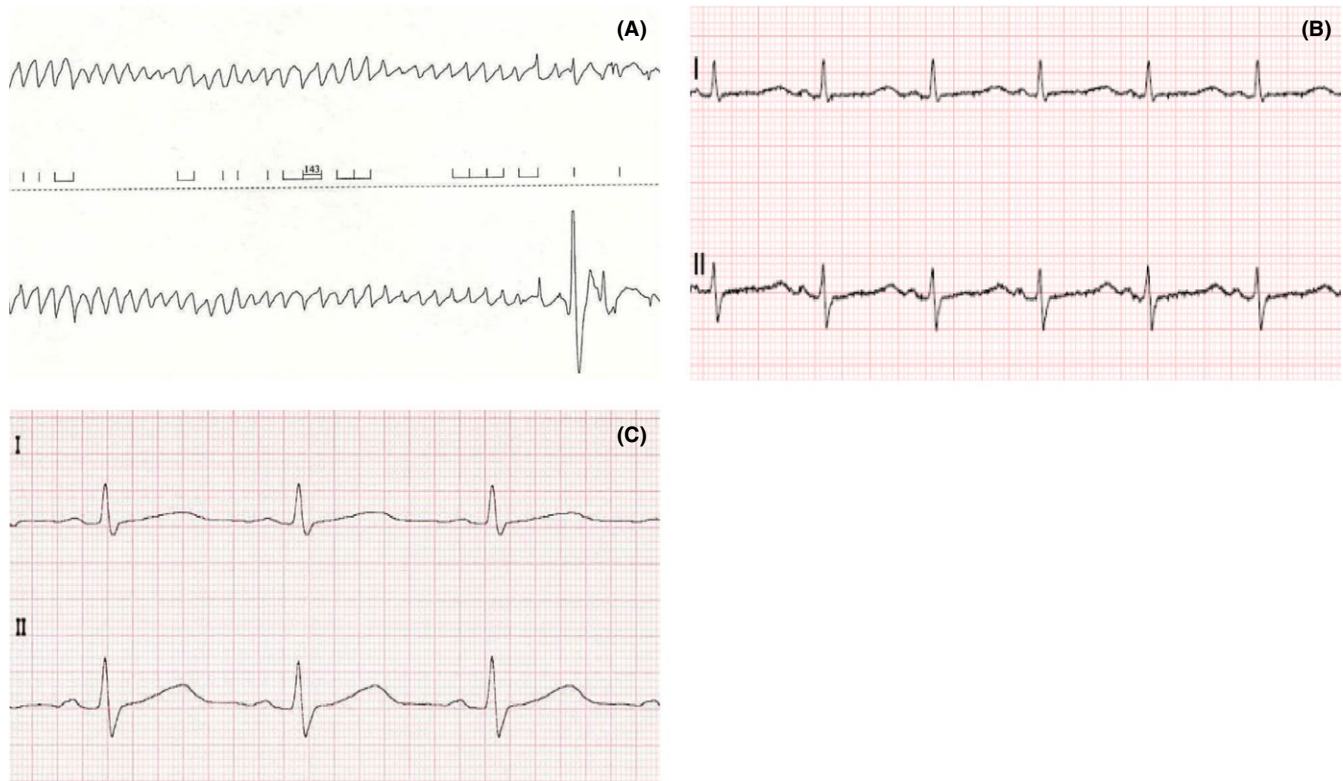


FIGURE 2 Electrocardiograms (ECG) of a patient before (A) and under treatment (B, C) with isavuconazole. Twelve-channel ECG (A/B: 25 and C: 50 mm/s paper speed) of a patient treated with isavuconazole. A, d0 before treatment: torsade de pointes tachycardia. B, d0 after defibrillation and magnesium administration: sinus rhythm, heart rate 79 bpm, QT 409 ms, QTc 469 ms. C, d8 of isavuconazole treatment: sinus rhythm, heart rate 69 bpm, QT 445 ms, QTc 477 ms

patients showed electrolyte abnormalities, mainly hypo- or hypercalcaemia. No differences of QTc changes could be found in patients with electrolyte abnormalities compared to those with normal electrolytes.

Only 1 patient had cardiac symptoms at the time of ECG performance, that is, torsade de pointes tachycardia. He was first successfully treated with magnesium and defibrillation. Thereafter, he was switched to isavuconazole to reduce drug-induced long QT to avoid further occurrence of torsade de pointes. Isavuconazole led to normalisation of symptoms and ECG findings.

4 | DISCUSSION

Isavuconazole is a second-generation azole antifungal approved for the treatment of invasive aspergillosis and mucormycosis. We here report on its capability of QTc shortening. Apart from one recent case report, these are the first data outside controlled clinical trials showing this effect. A contraindication for isavuconazole is thus a known familial short QT syndrome (SQTS),¹¹ a very rare autosomal dominant inherited channelopathy; published data include only a small number of families.¹²

In a phase I randomised, double-blind trial, 148 healthy individuals received isavuconazole 400 and 600 mg (after 2-day loading dose). Isavuconazole shortened the QTc interval in dose-related and plasma

concentration-related manner. Isavuconazole plasma concentration and QTc showed a negative correlation: the predicted mean decrease in QTc at the mean plasma drug concentration (C_{max}) of 200 and of 600 mg doses were 11.19 and -17.68 ms, respectively. Trang et al report on 1 case of QTc shortening of 145 ms (613-468 ms).¹³ Our data confirm these observations.

The QT interval is influenced by physiological and metabolic state of the patient. Changes may be induced by diverse clinical conditions such as diabetes,⁹ perioperative anaesthetics¹⁴ and multiple arrhythmogenic medications, for example, different azole antifungals.¹⁻³ Isavuconazole is both a substrate and a moderate inhibitor of the CYP3A4 isoenzyme.^{15,16} This should be considered during administration of co-medication.

In our patient cohort, QT prolonging co-medications were mostly administered continuously before as well as during treatment with isavuconazole. QTc decreased when isavuconazole was given. One patient received tacrolimus for graft-vs-host disease following allogeneic haematopoietic stem cell transplantation from day 50 on. However, he showed a further decrease in QTc while on tacrolimus treatment (432-422 ms). Isavuconazole may often replace other triazoles, typically prolonging QT, due to microbiological failure or intolerable side effects; such switch within the azole class may enhance the observed effect of QTc shortening. However, we could not see differences in patients with or without prior treatment with azoles or other QT prolonging co-medication regarding QTc shortening by isavuconazole. We

conclude that QTc shortening occurred despite ongoing treatment with QT prolonging medication and independently of prior medication with other triazoles. Due to a high number of concomitant drugs, further assessment of the influence of co-medication is precluded in our small patient cohort. Drug-drug interactions always need attention in critically ill patients who often receive a wide range of drugs.

Electrolyte abnormalities affect the QT interval. Imbalances of potassium, calcium and magnesium influence de- and repolarisation phases of the cardiac action potential in altering the potentials across myocyte cellular membranes. In particular, hypercalcaemia may shorten, while hypocalcaemia and hypokalaemia prolong the QT interval.¹⁰ Some of the observed patients showed alterations in calcium and potassium levels. No differences could be found in patients with electrolyte abnormalities compared to those with normal electrolytes. On the other hand, 1 of the 2 patients without changes in QTc had hypokalaemia on the day of his second ECG, possibly prolonging QTc and thus explaining missing QTc shortening by isavuconazole. No other patient had hypokalaemia at the time of his second ECG. The impact of electrolyte abnormalities on QTc changes remains uncertain.

The second patient without QTc changes did not have electrolyte abnormalities at the time of ECG under isavuconazole treatment. Regarding co-medication, amlodipine (calcium channel blocker) and valsartan (AT II antagonist) were newly prescribed in the time span of first and second ECG. While AT II antagonists do not impact cardiac de- and repolarisation,¹⁷ this is not finally resolved for calcium channel blockers.^{18,19}

Limitations of this study are the small number of patients as well as the ranges in timing of ECGs during isavuconazole treatment in the different patients. Long-term follow-up was only performed in a single patient and showed further decrease in QTc under continued isavuconazole medication. Taking into account its use for severe IFI entailing sustained treatment, subsequent studies should assess long-term effects of isavuconazole on QTc. However, our findings confirm the observation from controlled clinical trials in a real-life setting.

Among triazole antifungal agents, QTc shortening by isavuconazole is unique and so far has not been associated with untoward cardiovascular events. Knowledge about cardiac effects of isavuconazole will serve to better manage the use of concomitant medications. Consideration of SQTS is of minor importance as both SQTS and isavuconazole prescription are extremely rare issues.

ACKNOWLEDGMENTS

The authors thank the study coordinators Larisa Idrizovic, Stefan Körfggen, Tatjana Lammertz and Susanna Proske at the Infectious Diseases Clinical Trial Unit, Cologne, Germany for technical support.

CONFLICT OF INTEREST

OAC is supported by the German Federal Ministry of Research and Education and the European Commission and has received research

grants from, is an advisor to or received lecture honoraria from Achaogen, Actelion, Amplyx, Anacor, Arsanis, Astellas, AstraZeneca, Basilea, Bayer, Cidara, Da Volterra, F2G, Gilead, GSK, Janssen, Matinas, MedPace, Melinta, Menarini, Merck/MSD, Miltenyi, Paratek, Pfizer, Rempex, Roche, Sanofi Pasteur, Scynexis, Seres, Summit, Tetrphase, Medicines Company and Vical. SH is supported by the German Federal Ministry of Research and Education and is an advisor to or received lecture honoraria from Pfizer, Merck/MSD, InfectoPharm, Astra Zeneca, Ophardt, Spectranetics and Falk Foundation. All remaining authors have declared no conflicts of interest.

ORCID

Sibylle C. Mellinghoff  <http://orcid.org/0000-0003-3928-2503>

Stefan Hage  <http://orcid.org/0000-0003-2999-6131>

Nicola Lehnert  <http://orcid.org/0000-0002-9615-2564>

Enrico Schalk  <http://orcid.org/0000-0003-1892-5098>

Antonio Vena  <http://orcid.org/0000-0002-0697-3992>

Oliver A. Cornely  <http://orcid.org/0000-0001-9599-3137>

REFERENCES

1. Wassmann S, Nickenig G, Bohm M. Long QT syndrome and torsade de pointes in a patient receiving fluconazole. *Ann Intern Med.* 1999;131:797.
2. Brown JD, Lim LL, Koning S. Voriconazole associated torsades de pointes in two adult patients with haematological malignancies. *Med Mycol Case Rep.* 2014;4:23-25.
3. Panos G, Velissaris D, Karamouzos V, Matzaroglou C, Tyllianakis M. Long QT syndrome leading to multiple cardiac arrests after posaconazole administration in an immune-compromised patient with sepsis: an unusual case report. *Am J Case Rep.* 2016;17:295-300.
4. Keirns J, Desai A, Kowalski D, et al. QT interval shortening with isavuconazole. In vitro and in vivo effects on cardiac repolarization. *Clin Pharmacol Ther.* 2017;101:782-790.
5. Maertens JA, Raad II, Marr KA, et al. Isavuconazole versus voriconazole for primary treatment of invasive mould disease caused by *Aspergillus* and other filamentous fungi (SECURE): a phase 3, randomised-controlled, non-inferiority trial. *Lancet.* 2016;387:760-769.
6. Bazett HC. An analysis of the time-relations of electrocardiograms. *Ann Noninvasive Electrocardiol.* 1997;2:177-194.
7. Priori SG, Blomstrom-Lundqvist C, Mazzanti A, et al. 2015 ESC Guidelines for the management of patients with ventricular arrhythmias and the prevention of sudden cardiac death: The Task Force for the Management of Patients with Ventricular Arrhythmias and the Prevention of Sudden Cardiac Death of the European Society of Cardiology (ESC). Endorsed by: Association for European Paediatric and Congenital Cardiology (AEPC). *Eur Heart J.* 2015;36:2793-2867.
8. Surges R, Taggart P, Sander JW, Walker MC. Too long or too short? New insights into abnormal cardiac repolarization in people with chronic epilepsy and its potential role in sudden unexpected death. *Epilepsia.* 2010;51:738-744.
9. Veglio M, Borra M, Stevens LK, Fuller JH, Perin PC. The relation between QTc interval prolongation and diabetic complications. The EURODIAB IDDM complication study group. *Diabetologia.* 1999;42:68-75.
10. Diercks DB, Shumaik GM, Harrigan RA, Brady WJ, Chan TC. Electrocardiographic manifestations: electrolyte abnormalities. *J Emerg Med.* 2004;27:153-160.

11. Astellas Pharma US & Inc. CRESEMBA® (isavuconazonium sulfate) prescribing information. https://www.accessdata.fda.gov/drugsatfda_docs/label/2015/207500Orig1s000lbl.pdf. Accessed April 4, 2017.
12. Giustetto C, Di Monte F, Wolpert C, et al. Short QT syndrome: clinical findings and diagnostic-therapeutic implications. *Eur Heart J*. 2006;27:2440-2447.
13. Trang TP, Hanretty AM, Langelier C, Yang K. Use of isavuconazole in a patient with voriconazole-induced QTc prolongation. *Transpl Infect Dis*. 2017;19. <https://doi.org/10.1111/tid.12712>.
14. Wilton NCT, Hantler CB. Congenital long QT syndrome: changes in QT interval during anesthesia with thiopental, vecuronium, fentanyl, and isoflurane. *Anesth Analg*. 1987;66:357-360.
15. Groll AH, Desai A, Han D, et al. Pharmacokinetic assessment of drug-drug interactions of isavuconazole with the immunosuppressants cyclosporine, mycophenolic acid, prednisolone, sirolimus, and tacrolimus in healthy adults. *Clin Pharmacol Drug Dev*. 2017;6:76-85.
16. Townsend R, Dietz A, Hale C, et al. Pharmacokinetic evaluation of CYP3A4-mediated drug-drug interactions of isavuconazole with rifampin, ketoconazole, midazolam, and ethinyl estradiol/norethindrone in healthy adults. *Clin Pharmacol Drug Dev*. 2017;6:44-53.
17. Langenickel TH, Jordaan P, Petruck J, et al. Single therapeutic and supratherapeutic doses of sacubitril/valsartan (LCZ696) do not affect cardiac repolarization. *Eur J Clin Pharmacol*. 2016;72:917-924.
18. Alday A, Alonso H, Gallego M, et al. Ionic channels underlying the ventricular action potential in zebrafish embryo. *Pharmacol Res*. 2014;84:26-31.
19. Klimas J, Vaja V, Vercinska M, Kyselovic J, Krenek P. Discrepant regulation of QT (QTc) interval duration by calcium channel blockade and angiotensin converting enzyme inhibition in experimental hypertension. *Basic Clin Pharmacol Toxicol*. 2012;111:279-288.

How to cite this article: Mellinghoff SC, Bassetti M, Dörfel D, et al. Isavuconazole shortens the QTc interval. *Mycoses*. 2018;61:256–260. <https://doi.org/10.1111/myc.12731>