

OPEN

The 2023 new European guidelines on infective endocarditis: main novelties and implications for clinical practice

Massimo Imazio^{a,b}

The 2023 European Society of Cardiology (ESC) guidelines for the management of infective endocarditis update the previous 2015 guidelines with main novelties in five areas: (1) antibiotic prevention for high-risk patients, and prevention measures for intermediate-risk and high-risk patients; (2) diagnosis with emphasis on multimodality imaging to assess cardiac lesions of infective endocarditis; (3) antibiotic therapy allowing an outpatient antibiotic treatment for stabilized, uncomplicated cases; (4) cardiac surgery with an emphasis on early intervention without delay for complicated cases; and (5) shared management decision by the endocarditis team. Most evidence came from observational studies and expert opinions. The guidelines strongly support a patient-centred approach with a shared decision process by a multidisciplinary team that should be implemented either in tertiary referral centres, becoming heart valve centres, and referral

centres. A continuous sharing of data is warranted in the hospitals' network between heart valve centres, which are used for referrals for complicated cases of infective endocarditis, and referral centres, which should be able to manage uncomplicated cases of infective endocarditis.

J Cardiovasc Med 2024, 25:1–9

Keywords: antibiotic therapy, cardiac surgery, heart team, infective endocarditis, prevention

^aDepartment of Medicine (DMED), University of Udine and ^bCardiothoracic Department, University Hospital Santa Maria della Misericordia, ASUFC, Udine, Italy

Correspondence to Professor Massimo Imazio, MD, FESC, FHFA, Cardiothoracic Department, University Hospital Santa Maria della Misericordia, ASUFC, Udine, Italy
E-mail: massimo.imazio@uniud.it

Received 1 April 2024 Revised 13 May 2024
Accepted 19 May 2024

Introduction

The 2023 European guidelines for the management of infective endocarditis¹ update the old 2015 guidelines² providing new important novelties in five main areas: prevention of infective endocarditis; diagnosis with multimodality imaging; antibiotic therapy and possibility of outpatient antibiotic therapy for stabilized, uncomplicated cases; timing of cardiac surgery; and role of the endocarditis team with a network of heart centres and referral centres (Fig. 1).

This review is focused on the main novelties of the new guidelines and how they can impact daily clinical practice revising the evidence to support the new recommendations.

Prevention of infective endocarditis

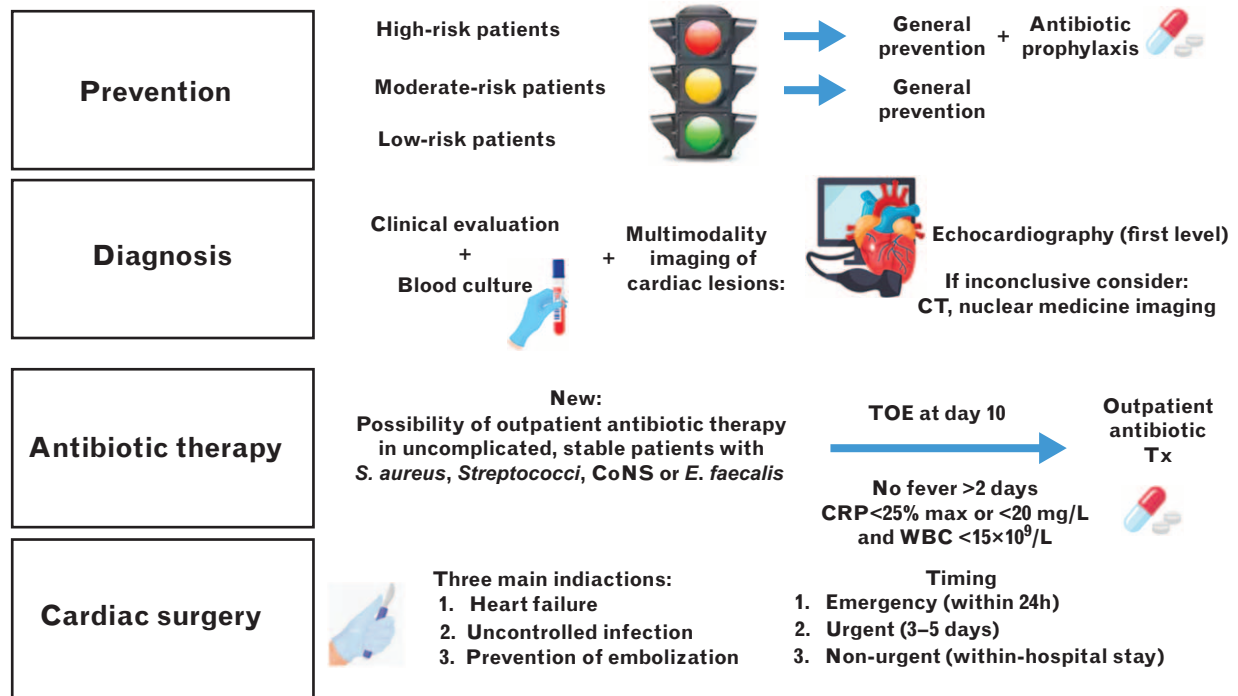
Infective endocarditis represents a rare disease but with a high morbidity and mortality.^{3,4} Prevention and early diagnosis are essential tools to prevent a complicated course and mortality. The ageing of the population, the increased availability of interventional and surgical options for the treatment of diseases, not only cardiovascular ones but also the increasing antibiotic resistance, and the increased use of diagnostic tools for the diagnosis of infective endocarditis have contributed to an increased incidence of the disease. It is unknown if changes in preventive measures, especially a reduced emphasis

on antibiotic prophylaxis based on previous guidelines, have also contributed to this increase in the incidence of infective endocarditis.^{1,5,6}

The development of infective endocarditis requires a predisposing condition, pathogens entering the bloodstream (from oral cavity, skin, gastrointestinal or genitourinary tract), and host's immune response with a reduced capacity for clearance of the infectious agent. The role of predisposing risk factors has been recently evaluated,⁷ and current guidelines identify three classes of populations at risk: high risk, intermediate risk, and low risk (Table 1).¹ Individuals at high risk for infective endocarditis must receive antibiotic prophylaxis before at-risk dental procedures including dental extractions, oral surgery procedures, and dental procedures involving manipulation of the gingival and periapical region of the teeth (upgraded indication from IIa to I). Furthermore, for high-risk patients, the latest guidelines have reintroduced the possibility of antibiotic prophylaxis for invasive diagnostic or therapeutic nondental procedures, such as those on the respiratory, gastrointestinal, genitourinary tract, skin, and musculoskeletal system (Class IIb recommendation).

For patients at high or intermediate risk of infective endocarditis, it is also recommended to follow general prevention measures (Table 2).

Fig. 1



Highlights of major novelties of the 2023 ESC guidelines on the management of infective endocarditis. Novelties are in four areas: prevention, diagnosis with multimodality imaging, antibiotic therapy, and cardiac surgery.

Percutaneous interventional techniques are increasing because of improvement in interventions for older patients, when traditional cardiac surgery is contraindicated or not feasible, such as for transcatheter aortic valve implantation (TAVI). The new 2023 guidelines recommend antibiotic prophylaxis (covering for common skin flora including *Enterococcus* spp. and *Staphylococcus aureus*) before TAVI and other transcatheter valvular procedures (Class IIa recommendation). This recommendation has a significant impact on clinical practice, also considering the diffusion of these procedures.

In conclusion, the 2023 European Society of Cardiology (ESC) guidelines strongly endorse antibiotic prophylaxis before invasive dental procedures for high-risk patients, elevating their recommendation to Class I, and increasing awareness of the potential utility of antibiotic prophylaxis in specific interventional conditions, considering also the risk profile of the patient. The 2021 American Heart Association (AHA) guidelines are also aligned with this view.⁸ In contrast, the UK's National Institute for Health and Care Excellence (NICE) recommends against routine use of antibiotic prophylaxis. On this basis, it is probably time for a review of the NICE guidance because of considerable new evidence since 2015.⁶

Diagnosis with multimodality imaging

The diagnosis of infective endocarditis is based on a clinical suspicion supported by microbiological data and the documentation of cardiac lesions by imaging techniques. The 2023 ESC guidelines for the management of infective endocarditis introduce the importance of multimodality imaging to detect cardiac lesions of infective endocarditis (imaging positive for infective endocarditis) as a major criterion, as when prosthetic material is present [prosthetic valve endocarditis (PVE), aortic grafts, cardiac devices, congenital heart disease (CHD)], echocardiography is normal or inconclusive in up to 30% of cases, even when infective endocarditis is present.^{9–12} Moreover, specific algorithms are introduced to support decision-making [native valve endocarditis (NVE), PVE, cardiac-device-related infective endocarditis, CIED]. The definition of three different diagnostic algorithms for PVE, NVE and infective endocarditis associated with CIED (all three based on clinical suspicion, microbiological evidence of infective endocarditis and demonstration of valvular lesions on imaging) is a novelty of the latest guidelines that can help to guide clinical choices.

Positive blood cultures remain essential for the diagnosis of infective endocarditis and provide bacteria for identification and antibiotic susceptibility tests. At least three sets

Table 1 Populations at risk of infective endocarditis

Risk of IE	Population
High risk	Patients with previous IE Patients with surgically implanted prosthetic valve and any material used for cardiac valve repair ^a Patients with congenital heart disease (CHD) at high risk for IE: untreated CHD, ^b and those treated with prosthetic material Patients with ventricular assist devices as destination therapy
Intermediate risk	Patients with rheumatic heart diseases Patients with nonrheumatic degenerative valve disease Patients with congenital valve abnormalities, including bicuspid aortic valve Patients with implanted electronic devices (CIEDs) Patients with hypertrophic cardiomyopathy
Low risk	All other patients

IE, infective endocarditis. ^aIn case of transcatheter mitral and tricuspid valve repair, the antibiotic prophylaxis is a Class IIa recommendation, because the data on the risk of IE are limited in this setting. ^bNot including isolated congenital valve abnormalities.

of blood cultures should be obtained at 30-min intervals prior to antibiotic therapy, each containing 10 ml of blood to be incubated in both aerobic and anaerobic atmospheres.⁹ Sampling should be obtained from a peripheral vein. At present, the gold standard for susceptibility testing is the determination of the minimal inhibitory concentrations (MICs) to select appropriate antibiotic therapy.⁹ Blood culture-negative infective endocarditis is most commonly related to previous antibiotic therapy, but it can also be caused by fungi or fastidious bacteria. In this setting, systematic serology for *Coxiella burnetii*, *Bartonella* spp., *Aspergillus* spp., *Mycoplasma pneumoniae*, *Brucella* spp. and *Legionella pneumophila* should be proposed.¹³

Table 2 General prevention measures for patients at high or moderate risk of infective endocarditis

Tooth cleaning twice daily with dental cleaning twice yearly for high-risk patients and once yearly for intermediate-risk patients Strict cutaneous hygiene Disinfection of wounds Curative antibiotic therapy for any focus of bacterial infection but with avoidance of self-medication with antibiotics Strict infection control measures for any at-risk procedure Discouragement of piercing and tattooing Limitation of infusion catheters and invasive procedures whenever possible and strict care of bundles for central and peripheral i.v. infusions

i.v., intravenous.

Detection of cardiac lesions is a major diagnostic criterion for infective endocarditis. Echocardiography remains the first-level imaging technique with either transthoracic echocardiography (TTE) or transoesophageal echocardiography (TOE), but a multimodality imaging approach is strongly enforced, including computed tomography (CT), nuclear imaging, and MRI, in order to confirm or exclude the diagnosis, to better characterize the extent of cardiac lesions, and to diagnose extracardiac complications.^{14,15}

When evaluating infective endocarditis, TTE has a low sensitivity and a good specificity as compared with TOE.¹⁶ TOE has now a Class I indication, even in the case of positive TTE in order to better evaluate perivalvular complications and small vegetations, except in isolated right-sided native valve infective endocarditis with good-quality TTE and unequivocal findings. TOE is also indicated in uncomplicated infective endocarditis before switching from intravenous to oral antibiotic therapy (Class I, see also antibiotic therapy).

Repeated TTE and TOE should be considered during follow-up of uncomplicated cases in order to detect new silent complications and monitor vegetations. In the case of a normal or inconclusive echocardiogram, it must be repeated after 5–7 days in cases with a high clinical suspicion of infective endocarditis. Although scoring systems have been developed to help in the appropriate indication for echocardiography in cases with blood stream infections,^{17–20} it should be underlined that echocardiography has a Class I indication in suspected infective endocarditis (recommendation IB).^{16,21}

The indications for CT, MRI, and nuclear imaging in patients with suspected or diagnosed infective endocarditis are summarized in Table 3. CT is more accurate than TOE for the diagnosis of perivalvular and periprosthetic complications.^{22,23} Echocardiography is superior to CT for the detection of small vegetations (<10 mm), leaflet perforations, and fistulae.^{22,23} CT angiography can detect mycotic aneurysms in almost any site of the vascular tree.^{24,25}

MRI is superior to CT for the diagnosis of neurological complications, but CT is more feasible also in the emergency setting with a sensitivity of 90% and a specificity of 86% in the diagnosis of ischaemic and haemorrhagic lesions.²⁶ Additional indications for CT include the preoperative evaluation of coronary anatomy before cardiac surgery as an alternative to coronary angiography,²⁷ and the evaluation of possible alternative diagnoses to infective endocarditis, although nuclear imaging is superior for this task.²⁸

MRI is particularly helpful in the detection of neurological complications of infective endocarditis. Patients with infective endocarditis have neurological lesions in up to

Table 3 Indications for computed tomography, MRI, and nuclear medicine imaging in diagnosed or suspected infective endocarditis according to the 2023 ESC guidelines for the management of infective endocarditis

Imaging	Indications
Computed tomography (CT)	Diagnosis of IE and perivalvular and periprosthetic complications (abscesses, pseudoaneurysms, and fistulae) Detection of distant lesions and sources of bacteraemia Preoperative assessment of coronary anatomy Evaluation of alternative diagnoses
MRI	Diagnosis of IE and its cardiac complications Diagnosis of neurological complications of IE Diagnosis of spine lesions
Nuclear imaging [18F] FDG-PET/CT and WBC SPECT/CT	Diagnosis of IE and its cardiac complications Detection of distant lesions and sources of bacteraemia Monitoring response to antimicrobial treatment

IE, infective endocarditis.

60–80% of cases,²⁹ mostly ischaemic (50–80% of patients) and asymptomatic with a limited impact on the subsequent management.³⁰ Although the direct clinical impact of asymptomatic ischaemic lesions is minimal, the new guidelines underline that the presence of embolic lesions (even asymptomatic) may represent an indication for urgent surgery in some cases.

Parenchymal and subarachnoid haemorrhages, abscesses and mycotic aneurysm are found in less than 10% and may have important implications for the management of infective endocarditis.^{31,32}

Nuclear imaging techniques for the diagnosis of infective endocarditis include [18F]FDG-PET/CT and white blood cell (WBC) single photon emission computed tomography (SPECT)/CT and that are recommended in suspected PVE when echocardiography is inconclusive. Such techniques have a sensitivity and specificity of about 85% for the diagnosis of PVE.³³ In NVE, the sensitivity of nuclear imaging techniques is low (about 30%) but with a higher specificity (about 98%) because, in this setting, vegetations prevail on paravalvular involvement, thus reducing the inflammatory response detected by nuclear imaging.³⁴

Enterococcus faecalis is now acknowledged as a typical infective endocarditis bacterium, significantly increasing the sensitivity to correctly identify definite infective endocarditis.³⁵

Antibiotic therapy

Empiric antibiotic therapy for NVE and late PVE should be targeted at staphylococci, streptococci, and enterococci. Early PVE and healthcare-associated infective endocarditis regimens should cover methicillin-resistant staphylococci, enterococci, and non-*Haemophilus*, *Aggregatibacter* (previously *Actinobacillus*), *Cardiobacterium*, *Eikenella*, *Kingella* Gram-negative pathogens (Table 4). Coagulase-negative staphylococci (CoNS) should be empirically covered in PVE. Once the causative pathogen is identified, the antibiotic therapy should be better targeted also considering its antibiotic susceptibility.

Emerging problems with antibiotic therapy for infective endocarditis include the development of antibiotic resistance and tolerance. Bacterial antibiotic tolerance is reported for bacteria that are still susceptible to an antibiotic but are able to escape drug-killing and may restart growing after the antibiotic withdrawal. Slow-growing bacteria may develop vegetations and biofilms that require prolonged therapies; this is especially common for PVE.³⁶ Bactericidal drug combinations remain preferred to monotherapies, especially in the case of antibiotic tolerance, and drug treatment of PVE should last longer (>6 weeks) compared with a shorter duration of antibiotic therapy for NVE (4–6 weeks).

For antibiotic therapy, the main novelty of these guidelines is the introduction of the possibility of outpatient antibiotic therapy in stable patients with infective endocarditis after an initial phase of intravenous antibiotic therapy mainly based on the results of the POET trial.³⁷ In the POET trial, patients with left-sided infective endocarditis related to *Streptococcus*, *E. faecalis*, *S. aureus*, or CoNS were treated with intravenous antibiotics for at least 10 days and then randomized to continue intravenous treatment (199 patients) or to switch to oral antibiotic treatment with outpatient treatment, if feasible (201 patients). The primary outcome was a composite of all-cause mortality, unplanned cardiac surgery, embolic events, or relapse of bacteraemia with the primary pathogen, from the time of randomization until 6 months after antibiotic treatment was completed. In this trial, changing to oral antibiotic treatment was noninferior to continued intravenous antibiotic treatment, and the primary composite outcome occurred in 12.1% of cases in the intravenously treated group and in 9% of cases in the orally treated group (between-group difference, 3.1%; 95% confidence interval, –3.4 to 9.6; $P=0.40$). The 5-year outcomes of the POET trial confirmed the effectiveness of the oral antibiotic therapy.³⁸ Outpatient parenteral or oral antibiotic therapy can be considered if the patient is clinically stable; the home environment is stable, preferably with a cohabitant caregiver; the patient is self-reliant or home healthcare can be provided. Contraindications to oral antibiotic therapy

Table 4 Recommendations for empiric antibiotic therapy in infective endocarditis for adult patients

Setting and recommendation	Class	Level
Community-acquired NVE or late PVE (≥ 12 months after cardiac surgery) (targeted at staphylococci, streptococci, and enterococci): ampicillin with ceftriaxone or (flu)cloxacillin and gentamicin Ampicillin 12 g/day iv in four to six doses Ceftriaxone 4 g/day i.v. or i.m. in two doses (Flu)cloxacillin 12g/day i.v. in four to six doses Gentamicin 3 mg/kg/day i.v. or i.m. once daily	IIa	C
Early PVE (< 12 months before cardiac surgery) or healthcare-associated (targeted at methicillin-resistant staphylococci, enterococci, and non-HACEK Gram-negative pathogens): vancomycin or daptomycin combined with gentamicin and rifampicin Vancomycin 30 mg/kg/day i.v. in two doses Daptomycin 10 mg/kg/day i.v. once daily Gentamicin 3 mg/kg/day i.v. or i.m. once daily Rifampin 900–1200 mg i.v. or orally in two to three doses	IIb	C
Allergy to beta-lactams: Community-acquired NVE or late PVE (≥ 12 months after cardiac surgery) (targeted at staphylococci, streptococci, and enterococci): ceftazolin or vancomycin in combination with gentamicin Ceftazolin 6 g/day i.v. in three doses Vancomycin 30 mg/kg/day i.v. in two doses Gentamicin 3 mg/kg/day i.v. or i.m. once daily	IIb	C

i.m., intramuscular; i.v., intravenous; NVE, native valve endocarditis; PVE, prosthetic valve endocarditis.

(OPAT) are represented by heart failure; severe valvular regurgitation; vegetations greater than 10 mm; progression, or local complications; presence of neurological involvement; renal impairment; malabsorption and drug or substance intravenous users.

On this basis, the 2023 ESC guidelines on infective endocarditis management propose a first phase of intravenous antibiotic therapy with possible removal of infected cardiac device, cardiac surgery if needed and draining of abscesses. In the stable patient, a TOE should be performed to exclude complications at day 10 (recommendation Class I), and then the stable uncomplicated patient can be considered for antibiotic therapy on an outpatient basis, if feasible from day 10 after starting intravenous antibiotics or day 7 postsurgery (Fig. 1). Outpatient parenteral or OPAT patients are treated with the same combinations of antibiotics as in the hospital, or a step-down outpatient oral therapy. Patients and caregivers should be educated in the disease and its monitoring (e.g. monitor signs of infection, daily temperature). A regular post-discharge follow-up is warranted (nurse once daily, physician visit one to three times per week). Complicated cases should be maintained on intravenous antibiotic therapy and remain hospitalized.

It should be, however, acknowledged that the study was conducted in Denmark and that antibiotic resistance may be higher in other epidemiological settings, such as Southern Europe and Italy, for instance. On this basis, the evaluation of the single case is mandatory within the Endocarditis team to assess the real feasibility of this strategy in the single patient.

Cardiac surgery

Infective endocarditis may be associated with complications that can be only treated with cardiac surgery. In these cases, surgical therapy saves lives with a survival advantage of up to 20%.^{39,40} There are three main indications for cardiac surgery: heart failure, uncontrolled infection and prevention of septic embolization. The timing of cardiac surgery may be defined as: emergency (within 24 h), urgent (3–5 days) and nonurgent (within the same hospital admission). For stable patients with residual heart valve dysfunction and cured infective endocarditis, the timing of subsequent cardiac surgery follows the guidelines for heart valve diseases.⁴¹

Although scores that predict mortality in infective endocarditis have been developed,⁴² none is commonly used in clinical practice, beyond general scores commonly used in cardiac surgery for noninfective endocarditis cardiac surgery.^{43,44} The 2023 ESC guidelines on infective endocarditis strongly advise having a shared multidisciplinary decision within the Endocarditis team¹ taking into account the single patient with his/her risk/benefit ratio.^{44,45}

The main key messages on surgical therapy for infective endocarditis according to the 2023 ESC guidelines are: shared management decisions with the Endocarditis team; no delay for cardiac surgery when needed also after neurological complications, such as ischaemic stroke and haemorrhagic stroke (earlier intervention is better); surgery is recommended for early PVE and more liberal use of cardiac surgery for prevention of embolism.

Heart failure

Heart failure remains the most common complication and indication for cardiac surgery on an urgent or emergency basis.⁴⁶ Risk factors for the development of heart failure are advanced age, NVE with aortic valve disease and comorbidities.⁴⁷ For patients with infective endocarditis complicated with heart failure, cardiac surgery is the only effective treatment associated with improved survival.^{46–49} The greatest survival benefit is noted in the worst patients with New York Heart Association (NYHA) Class III–IV symptoms.⁴⁷

Uncontrolled infection

This is the second most common indication for cardiac surgery in patients with infective endocarditis, and it is usually an indication for urgent surgery within 3–5 days. Uncontrolled infection occurs with persistently positive blood cultures for more than 1 week despite appropriate antibiotic therapy or with resistant and virulent organisms. Signs of locally uncontrolled infection include increasing vegetations, abscess and pseudoaneurysm and/or fistula formation, and new atrioventricular blocks. Higher incidence of perivalvular complications is recorded in PVE.⁵⁰

Prevention of septic embolization

The prevention of infective endocarditis embolism is another important indication for cardiac surgery. Embolic risk is high in patients with infective endocarditis affecting 20–50% of cases, often in an asymptomatic way (up to 50% of cases).²⁸ In left-sided infective endocarditis, the brain and spleen are the most common sites of embolization, whereas the lungs are affected in right-sided infective endocarditis. Risk factors for embolization include: age, vegetation length (high risk of neurological complications with a size >10 mm and especially >30 mm) and mobility, previous embolization before antibiotics, *S. aureus* infection, atrial fibrillation and diabetes.⁵¹ Early surgery is associated with a reduced risk of embolization, whereas initial conservative therapy is associated with increased mortality.⁵² The 2023 ESC guidelines suggest considering urgent cardiac surgery starting from a vegetation length of 10 mm (Class I recommendation) and considering a stronger level of evidence (LOE) with previous embolic episodes (LOE B), or other indications for surgery (LOE C). Preventive cardiac surgery may be considered in the absence of other indications and with a low operative risk with a vegetation length of at least 10 mm (Class IIb recommendation).

Neurological complications are common in patients with infective endocarditis and occur as symptomatic forms in one-third of cases but are asymptomatic in up to 80%.³² The 2023 ESC guidelines on infective endocarditis management support early surgery for patients with infective

endocarditis, a cardiac surgery indication and ischaemic stroke, as the risk of haemorrhagic conversion of the ischaemic lesion (risk of 2–7%) is lower than the risk of recurrent embolism.¹ A nondelayed (urgent) approach is supported by several pieces of observational data, unless the neurological status is poor.^{53,54} There are some retrospective data supporting the possible benefits of early surgery within 2 weeks after haemorrhagic stroke.⁵⁵ In patients with significant preoperative haemorrhagic stroke, guidelines generally recommend a delay in operative management of more than 4 weeks. In any case, it is crucial that the multidisciplinary team evaluate the case with neurology and neurosurgical specialists.¹

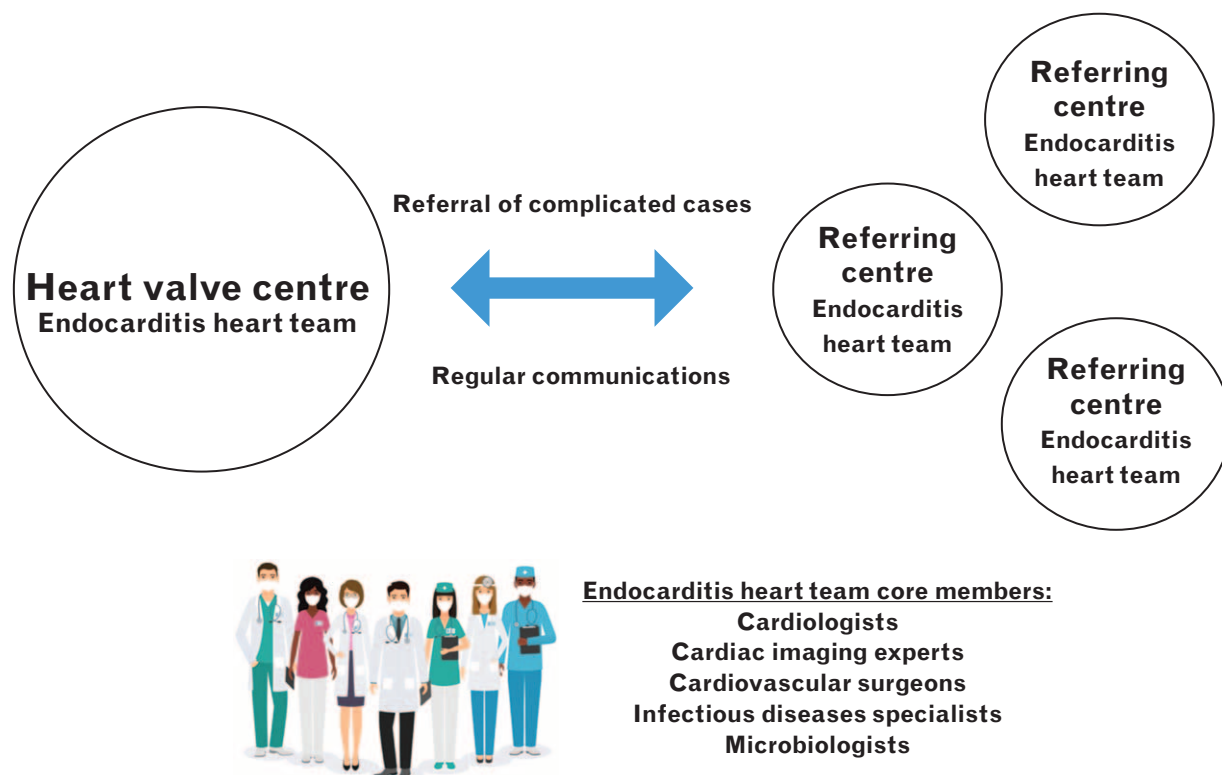
The new guidelines on infective endocarditis also recommend immediate epicardial pacemaker implantation in patients undergoing surgery for valvular infective endocarditis and complete atrio-ventricular block (AVB) in cases of preoperative conduction abnormality, *S. aureus* infection, aortic root abscess, tricuspid valve involvement, or previous valvular surgery, which are all predictors of persistent AVB (Class IIa recommendation).

Complete CIED removal is warranted for all patients with confirmed infection of the leads suggesting reimplantation at a distant site, if needed, with a delay until signs and symptoms of infection have abated and blood cultures are negative for at least 72 h in the absence of vegetations, and for at least 2 weeks if vegetations were present. The new guidelines underline the need for complete CIED extraction in the case of valvular infective endocarditis, even in the absence of manifest lead involvement, taking into account the identified pathogens (*Staphylococcus* spp. infections may be more prone to seeding the CIED), procedure risk and indication for valve surgery. Complete device extraction should be considered even in the absence of vegetations in the setting of persistent or relapsing Gram-positive bacteraemia or fungaemia after a course of appropriate antibiotic therapy, if there is no other identified source. For all lead extractions, procedural risk should be carefully evaluated taking into account the lead dwell time, pacemaker dependency, patient frailty and comorbidities. CIED management should be shared with the Endocarditis team and lead extraction should be performed percutaneously in centres with specific expertise and onsite surgical backup.

The endocarditis heart team

The 2023 guidelines underline the value of the heart team in the management of infective endocarditis (Fig. 2). The heart team can enhance the capability of early diagnoses, accurate treatment, optimal timing for cardiac surgery and prevention of complications, improving outcomes.^{56–61} The core members of the endocarditis team include: cardiologists, cardiac

Fig. 2



The endocarditis team for the management of infective endocarditis in heart valve centres and referring centres. See text for additional explanation.

imaging experts, cardiovascular surgeons, infectious diseases specialists and microbiologists. Adjunct specialties may be included according to the specific setting and case (e.g. radiologists and nuclear medicine specialists, pharmacologists, neurologists, neurosurgeons, anaesthesiologists and pathologists). According to the proposed model of management of infective endocarditis, uncomplicated cases can be managed in a referring centre that has regular communication with a heart valve centre (recommendation Class IB). A heart valve centre is a centre having all the diagnostic and therapeutic resources to treat infective endocarditis, including, in specific cases, cardiologists/cardiac surgeons with expertise in CIED extraction. The heart valve centre is the ideal place to which complicated cases of infective endocarditis should be referred at an early stage to improve outcomes (recommendation Class IB).

Conflicts of interest

There are no conflicts of interest.

References

- 1 Delgado V, Ajmone Marsan N, de Waha S, *et al.*, ESC Scientific Document Group. 2023 ESC Guidelines for the management of endocarditis. *Eur Heart J* 2023; **44**:3948–4042.

- 2 Habib G, Lancellotti P, Antunes MJ, *et al.*, ESC Scientific Document Group. 2015 ESC Guidelines for the management of infective endocarditis: The Task Force for the Management of Infective Endocarditis of the European Society of Cardiology (ESC). Endorsed by: European Association for Cardio-Thoracic Surgery (EACTS), the European Association of Nuclear Medicine (EANM). *Eur Heart J* 2015; **36**:3075–3128.
- 3 Momtazmanesh S, Saeedi Moghaddam S, Malakan Rad E, *et al.* Global, regional, and national burden and quality of care index of endocarditis: the global burden of disease study 1990-2019. *Eur J Prev Cardiol* 2022; **29**:1287–1297.
- 4 Chen H, Zhan Y, Zhang K, *et al.* The global, regional, and national burden and trends of infective endocarditis from 1990 to 2019: results from the Global Burden of Disease Study 2019. *Front Med (Lausanne)* 2022; **9**:774224.
- 5 Williams ML, Doyle MP, McNamara N, Tardo D, Mathew M, Robinson B. Epidemiology of infective endocarditis before versus after change of international guidelines: a systematic review. *Ther Adv Cardiovasc Dis* 2021; **17**:539447211002687.
- 6 Thornhill M, Prendergast B, Dayer M, Frisby A, Baddour LM. Endocarditis prevention: time for a review of NICE guidance. *Lancet Reg Health Eur* 2024; **39**:100876.
- 7 Thornhill MH, Jones S, Prendergast B, *et al.* Quantifying infective endocarditis risk in patients with predisposing cardiac conditions. *Eur Heart J* 2018; **39**:586–595.
- 8 Wilson WR, Gewitz M, Lockhart PB, *et al.*, American Heart Association Young Hearts Rheumatic Fever, Endocarditis and Kawasaki Disease Committee of the Council on Lifelong Congenital Heart Disease and Heart Health in the Young; Council on Cardiovascular and Stroke Nursing; and the Council on Quality of Care and Outcomes Research. Prevention of Viridans group streptococcal infective endocarditis: a scientific statement from the American Heart Association. *Circulation* 2021; **143**:e963–e978.

- 9 Habib G, Derumeaux G, Avierinos JF, *et al.* Value and limitations of the Duke criteria for the diagnosis of infective endocarditis. *J Am Coll Cardiol* 1999; **33**:2023–2029.
- 10 Vieira ML, Grinberg M, Pomerantzeff PM, Andrade JL, Mansur AJ. Repeated echocardiographic examinations of patients with suspected infective endocarditis. *Heart* 2004; **90**:1020–1024.
- 11 Hill EE, Herijgers P, Claus P, Vanderschueren S, Peetermans WE, Herregods MC. Abscess in infective endocarditis: the value of transesophageal echocardiography and outcome: a 5-year study. *Am Heart J* 2007; **154**:923–928.
- 12 Lamy B, Dargère S, Arendrup MC, Parienti JJ, Tattevin P. How to optimize the use of blood cultures for the diagnosis of bloodstream infections? A state-of-the art. *Front Microbiol* 2016; **7**:697.
- 13 Gouriet F, Samson L, Delaage M, *et al.* Multiplexed whole bacterial antigen microarray, a new format for the automation of serodiagnosis: the culture-negative endocarditis paradigm. *Clin Microbiol Infect* 2008; **14**:1112–1118.
- 14 Erba PA, Lancellotti P, Vilacosta I, *et al.* Recommendations on nuclear and multimodality imaging in IE and CIED infections. *Eur J Nucl Med Mol Imaging* 2018; **45**:1795–1815.
- 15 Bourque JM, Birgersdotter-Green U, Bravo PE, *et al.* ¹⁸F-FDG PET/CT and radiolabeled leukocyte SPECT/CT imaging for the evaluation of cardiovascular infection in the multimodality context: ASNC Imaging Indications (ASNC 12) Series Expert Consensus Recommendations from ASNC, AATS, ACC, AHA, ASE, EANM, HRS, IDSA, SCCT, SNMMI, and STS. *JACC Cardiovasc Imaging* 2024; **S1936-878X**(24) 00036-6.
- 16 Bai AD, Steinberg M, Showler A, *et al.* Diagnostic accuracy of transthoracic echocardiography for infective endocarditis findings using transesophageal echocardiography as the reference standard: a meta-analysis. *J Am Soc Echocardiogr* 2017; **30**:639.e8–646.e8.
- 17 Palraj BR, Baddour LM, Hess EP, *et al.* Predicting Risk of Endocarditis Using a Clinical Tool (PREDICT): scoring system to guide use of echocardiography in the management of *Staphylococcus aureus* bacteremia. *Clin Infect Dis* 2015; **61**:18–28.
- 18 Sunnerhagen T, Törmell A, Vikbrant M, Nilson B, Rasmussen M. HANDOC: a handy score to determine the need for echocardiography in non- β -hemolytic streptococcal bacteremia. *Clin Infect Dis* 2018; **66**:693–698.
- 19 Berge A, Krantz A, Östlund H, Nauclel P, Rasmussen M. The DENOVA score efficiently identifies patients with monomicrobial *Enterococcus faecalis* bacteremia where echocardiography is not necessary. *Infection* 2019; **47**:45–50.
- 20 Bouza E, Kestler M, Beca T, *et al.*, Grupo de Apoyo al Manejo de la Endocarditis. The NOVA score: a proposal to reduce the need for transesophageal echocardiography in patients with enterococcal bacteremia. *Clin Infect Dis* 2015; **60**:528–535.
- 21 Young WJ, Jeffery DA, Hua A, *et al.* Echocardiography in patients with infective endocarditis and the impact of diagnostic delays on clinical outcomes. *Am J Cardiol* 2018; **122**:650–655.
- 22 Jain V, Wang TKM, Bansal A, *et al.* Diagnostic performance of cardiac computed tomography versus transesophageal echocardiography in infective endocarditis: a contemporary comparative meta-analysis. *J Cardiovasc Comput Tomogr* 2021; **15**:313–321.
- 23 Oliveira M, Guittel L, Hamon M, Hamon M. Comparative value of cardiac CT and transesophageal echocardiography in infective endocarditis: a systematic review and meta-analysis. *Radiol Cardiothorac Imaging* 2020; **2**:e190189.
- 24 Huang JS, Ho AS, Ahmed A, Bhalla S, Menias CO. Borne identity: CT imaging of vascular infections. *Emerg Radiol* 2011; **18**:335–343.
- 25 Tonolini M, Petullà M, Bianco R. Mycotic visceral aneurysm complicating infectious endocarditis: imaging diagnosis and follow-up. *J Emerg Trauma Shock* 2012; **5**:201–203.
- 26 Goddard AJ, Tan G, Becker J. Computed tomography angiography for the detection and characterization of intra-cranial aneurysms: current status. *Clin Radiol* 2005; **60**:1221–1236.
- 27 Hekimian G, Kim M, Passefort S, *et al.* Preoperative use and safety of coronary angiography for acute aortic valve infective endocarditis. *Heart* 2010; **96**:696–700.
- 28 Lecomte R, Issa N, Gaborit B, *et al.* Risk-benefit assessment of systematic thoracoabdominal-pelvic computed tomography in infective endocarditis. *Clin Infect Dis* 2019; **69**:1605–1612.
- 29 Snygg-Martin U, Gustafsson L, Rosengren L, *et al.* Cerebrovascular complications in patients with left-sided infective endocarditis are common: a prospective study using magnetic resonance imaging and neurochemical brain damage markers. *Clin Infect Dis* 2008; **47**:23–30.
- 30 Cooper HA, Thompson EC, Laurenro R, *et al.* Subclinical brain embolization in left-sided infective endocarditis: results from the evaluation by MRI of the brains of patients with left-sided intracardiac solid masses (EMBOLISM) pilot study. *Circulation* 2009; **120**:585–591.
- 31 Duval X, lung B, Klein I, *et al.*, IMAGE (Resonance Magnetic Imaging at the Acute Phase of Endocarditis) Study Group. Effect of early cerebral magnetic resonance imaging on clinical decisions in infective endocarditis: a prospective study. *Ann Intern Med* 2010; **152**:497–504.
- 32 Sotero FD, Rosário M, Fonseca AC, Ferro JM. Neurological complications of infective endocarditis. *Curr Neurol Neurosci Rep* 2019; **19**:23.
- 33 Wang TKM, Sánchez-Nadales A, Igbinomwanhia E, Cremer P, Griffin B, Xu B. Diagnosis of infective endocarditis by subtype using ¹⁸F-fluorodeoxyglucose positron emission tomography/computed tomography: a contemporary meta-analysis. *Circ Cardiovasc Imaging* 2020; **13**:e010600.
- 34 Duval X, Le Moing V, Tubiana S, *et al.*, AEPEI-TEPvENDO study group. Impact of systematic whole-body ¹⁸F-fluorodeoxyglucose PET/CT on the management of patients suspected of infective endocarditis: the prospective multicenter TEPvENDO Study. *Clin Infect Dis* 2021; **73**:393–403.
- 35 Dahl A, Fowler VG, Miro JM, Bruun NE. Sign of the times: updating infective endocarditis diagnostic criteria to recognize *enterococcus faecalis* as a typical endocarditis bacterium. *Clin Infect Dis* 2022; **75**:1097–1102.
- 36 Høiby N, Ciofu O, Johansen HK, *et al.* The clinical impact of bacterial biofilms. *Int J Oral Sci* 2011; **3**:55–65.
- 37 Iversen K, Ihlemann N, Gill SU, *et al.* Partial oral versus intravenous antibiotic treatment of endocarditis. *N Engl J Med* 2019; **380**:415–424.
- 38 Pries-Heje MM, Wiingard C, Ihlemann N, *et al.* Five-year outcomes of the Partial Oral Treatment of Endocarditis (POET) trial. *N Engl J Med* 2022; **386**:601–602.
- 39 lung B, Doco-Lecompte T, Chocron S, *et al.*, AEPEI Study Group. Cardiac surgery during the acute phase of infective endocarditis: discrepancies between European Society of Cardiology guidelines and practices. *Eur Heart J* 2016; **37**:840–848.
- 40 Østergaard L, Oestergaard LB, Lauridsen TK, *et al.* Long-term causes of death in patients with infective endocarditis who undergo medical therapy only or surgical treatment: a nationwide population-based study. *Eur J Cardiothorac Surg* 2018; **54**:860–866.
- 41 Vahanian A, Beyersdorf F, Praz F, *et al.*, ESC/EACTS Scientific Document Group. 2021 ESC/EACTS Guidelines for the management of valvular heart disease. *Eur Heart J* 2022; **43**:561–632.
- 42 Fernandez-Felix BM, Barca LV, Garcia-Esquinas E, *et al.* Prognostic models for mortality after cardiac surgery in patients with infective endocarditis: a systematic review and aggregation of prediction models. *Clin Microbiol Infect* 2021; **27**:1422–1430.
- 43 Shahian DM, Jacobs JP, Badhwar V, *et al.* The Society of Thoracic Surgeons 2018 Adult Cardiac Surgery Risk Models: Part 1: Background, design considerations, and model development. *Ann Thorac Surg* 2018; **105**:1411–1418.
- 44 Fernández-Cisneros A, Hernández-Meneses M, Llopis J, *et al.*, Equip d'Endocarditis de l'Hospital Clinic de Barcelona. Risk scores' performance and their impact on operative decision-making in left-sided endocarditis: a cohort study. *Eur J Clin Microbiol Infect Dis* 2023; **42**:33–42.
- 45 Koch T, Hennigs A, Schmiedel S. Endocarditis guidelines: call for an interdisciplinary approach. *Lancet Infect Dis* 2024; **24**:e75.
- 46 Tornos P, lung B, Permanyer-Miraldà G, *et al.* Infective endocarditis in Europe: lessons from the Euro heart survey. *Heart* 2005; **91**:571–575.
- 47 Kiefer T, Park L, Tribouilloy C, *et al.* Association between valvular surgery and mortality among patients with infective endocarditis complicated by heart failure. *JAMA* 2011; **306**:2239–2247.
- 48 Thuny F, Beurtheret S, Mancini J, *et al.* The timing of surgery influences mortality and morbidity in adults with severe complicated infective endocarditis: a propensity analysis. *Eur Heart J* 2011; **32**:2027–2033.
- 49 Bohbot Y, Habib G, Laroche C, *et al.*, EORP EURO-ENDO Registry Investigators Group. Characteristics, management, and outcomes of patients with left-sided infective endocarditis complicated by heart failure: a substudy of the ESC-EORP EURO-ENDO (European infective endocarditis) registry. *Eur J Heart Fail* 2022; **24**:1253–1265.
- 50 Habib G, Erba PA, lung B, *et al.*, EURO-ENDO Investigators. Clinical presentation, aetiology and outcome of infective endocarditis: results of the ESC-EO REURO-ENDO (European infective endocarditis) registry: a prospective cohort study. *Eur Heart J* 2019; **40**:3222–3232.
- 51 Hubert S, Thuny F, Resseguier N, *et al.* Prediction of symptomatic embolism in infective endocarditis: construction and validation of a risk

- calculator in a multicenter cohort. *J Am Coll Cardiol* 2013; **62**:1384–1392.
- 52 Dashkevich A, Bratkov G, Li Y, *et al*. Impact of operative timing in infective endocarditis with cerebral embolism—the risk of intermediate deterioration. *J Clin Med* 2021; **10**:2136.
- 53 Zhang LQ, Cho SM, Rice CJ, *et al*. Valve surgery for infective endocarditis complicated by stroke: surgical timing and perioperative neurological complications. *Eur J Neurol* 2020; **27**:2430–2438.
- 54 Matthews CR, Hartman T, Madison M, *et al*. Preoperative stroke before cardiac surgery does not increase risk of postoperative stroke. *Sci Rep* 2021; **11**:9025.
- 55 Salaun E, Touil A, Hubert S, *et al*. Intracranial haemorrhage in infective endocarditis. *Arch Cardiovasc Dis* 2018; **111**:712–721.
- 56 Camou F, Dijos M, Barandon L, *et al*. Management of infective endocarditis and multidisciplinary approach. *Med Mal Infect* 2019; **49**:17–22.
- 57 El-Dalati S, Cronin D, Riddell J 4th, *et al*. The clinical impact of implementation of a multidisciplinary endocarditis team. *Ann Thorac Surg* 2022; **113**:118–124.
- 58 Elad B, Perl L, Hamdan A, *et al*. The clinical value of the endocarditis team: insights from before and after guidelines implementation strategy. *Infection* 2022; **50**:57–64.
- 59 Gibbons EF, Huang G, Aldea G, *et al*. A multidisciplinary pathway for the diagnosis and treatment of infectious endocarditis. *Crit Pathw Cardiol* 2020; **19**:187–194.
- 60 Kaura A, Byrne J, Fife A, *et al*. Inception of the 'endocarditis team' is associated with improved survival in patients with infective endocarditis who are managed medically: findings from a before-and-after study. *Open Heart* 2017; **4**:e000699.
- 61 Ruch Y, Mazzucotelli JP, Lefebvre F, *et al*. Impact of setting up an 'Endocarditis Team' on the management of infective endocarditis. *Open Forum Infect Dis* 2019; **6**:ofz308.