

Local therapy in glioma: An evolving paradigm from history to horizons (Review)

TAMARA IUS^{1*}, TERESA SOMMA^{2*}, FRANCESCO PASQUALETTI³, JACOPO BERARDINELLI²,
FRANCESCA VITULLI², MARIO CACCESE⁴, EUGENIA CELLA^{4,5}, CARLO CENCIARELLI⁶,
GIACOMO POZZOLI⁷, GIUSEPPE SCONOCCHIA⁶, MARCO ZEPPIERI⁸,
CARUSO GERARDO⁹, MARIA CAFFO^{9*} and GIUSEPPE LOMBARDI^{4*}

¹Unit of Neurosurgery, Head-Neck and Neurosciences Department, University Hospital of Udine, I-33100 Udine, Italy;

²Division of Neurosurgery, Department of Neurosciences, Reproductive and Odontostomatological Sciences, Federico II University, I-80128 Naples, Italy; ³Division of Radiation Oncology, Pisa University Hospital, I-56123 Pisa, Italy; ⁴Medical Oncology 1, Veneto Institute of Oncology-IRCCS, I-35128 Padua, Italy; ⁵Medical Oncology 2, San Martino Hospital-IRCCS, I-16131 Genoa Italy; ⁶Institute of Translational Pharmacology, National Research Council, I-00133 Roma, Italy; ⁷Section of Pharmacology, Department of Healthcare Surveillance and Bioethics, Catholic University Medical School, Fondazione Policlinico Universitario A. Gemelli IRCCS, I-00168 Rome, Italy; ⁸Department of Ophthalmology, University Hospital of Udine, I-33100 Udine, Italy; ⁹Unit of Neurosurgery, Department of Biomedical and Dental Sciences and Morphofunctional Imaging, University Hospital of Messina, I-98125 Messina, Italy

Received February 13, 2024; Accepted June 14, 2024

DOI: 10.3892/ol.2024.14573

Abstract. Despite the implementation of multimodal treatments after surgery, glioblastoma (GBM) remains an incurable disease, posing a significant challenge in neuro-oncology. In this clinical setting, local therapy (LT), a developing paradigm, has received significant interest over time due to its potential to overcome the drawbacks of conventional therapy options for GBM. The present review aimed to trace the historical development, highlight contemporary advances and provide insights into the future horizons of LT in GBM management. In compliance with the Preferred Reporting Items for Systematic Review and Meta-Analysis Protocols criteria, a systematic review of the literature on the role of LT in GBM management was conducted. A total of 2,467 potentially relevant articles were found and, after removal of duplicates, 2,007 studies were

screened by title and abstract (Cohen's κ coefficient=0.92). Overall, it emerged that 15, 10 and 6 clinical studies explored the clinical efficiency of intraoperative local treatment modalities, local radiotherapy and local immunotherapy, respectively. GBM recurrences occur within 2 cm of the radiation field in 80% of cases, emphasizing the significant influence of local factors on recurrence. This highlights the urgent requirement for LT strategies. In total, three primary reasons have thus led to the development of numerous LT solutions in recent decades: i) Intratumoral implants allow the blood-brain barrier to be bypassed, resulting in limited systemic toxicity; ii) LT facilitates bridging therapy between surgery and standard treatments; and iii) given the complexity of GBM, targeting multiple components of the tumor microenvironment through ligands specific to various elements could have a synergistic effect in treatments. Considering the spatial and temporal heterogeneity of GBM, the disease prognosis could be significantly improved by a combination of therapeutic strategies in the era of precision medicine.

Correspondence to: Dr Tamara Ius, Unit of Neurosurgery, Head-Neck and Neurosciences Department, University Hospital of Udine, Piazzale S. Maria della Misericordia 15, I-33100 Udine, Italy
E-mail: tamara.ius@gmail.com

Dr Marco Zeppieri, Department of Ophthalmology, University Hospital of Udine, Piazzale S. Maria della Misericordia 15, I-33100 Udine, Italy
E-mail: markzeppieri@hotmail.com

*Contributed equally

Key words: local therapy, immunotherapy, glioblastoma, high-grade gliomas, convection enhanced delivery, thermotherapy, carmustine wafer, brachytherapy, photodynamic therapy

Contents

1. Introduction
2. Study selection
3. BBB
4. Local treatments
5. Local treatment approaches and delivery systems for malignant gliomas
6. Local RT
7. Local immunotherapy
8. Advances in CAR-T cell technology and beyond for HGG
9. Conclusions

1. Introduction

Given the infiltrative characteristics and molecular heterogeneity of glioblastoma (GBM), the ongoing difficulty in discovering a cure persists. Despite advancements in technology and biological research, the median overall survival (OS) time of patients with GBM remains low, with a median OS time of 14-18 months (1-3). Even with advances in genetics and surgical techniques, neuro-oncology research has shown generally disappointing outcomes since the Stupp regimen was implemented. Although there have been advancements in surgical techniques, imaging protocols and radiotherapy (RT), as well as the use of intraoperative mapping to guide macroscopic complete resection, the median survival time has only increased by a few months (4). The current gold standard treatment after surgery for newly diagnosed patients with GBM dates back to 2005, with the EORTC/NCIC 26981 study demonstrating the survival benefits of combining radiation with temozolomide (TMZ) over radiation alone (2). Despite subsequent efforts, progress has remained constrained, as therapies including bevacizumab, everolimus and dose-dense TMZ have not demonstrated a significant survival benefit in randomized clinical trials when compared with the standard regimen of radiation and adjuvant TMZ. Challenges in developing new therapies include the need to penetrate the blood-brain barrier (BBB), tumor heterogeneity, and the widespread distribution of microscopic disease (1-4).

The resistance of GBM to treatment is widely known and can be explained by numerous different aspects of the tumor: i) GBM spatial heterogeneity limits the options and efficacy of target therapies; ii) GBM resistance to radiation and chemotherapy is facilitated by the pro-tumorigenic activity of the tumor microenvironment (TME); and iii) the limited immunogenicity of GBM inhibits a robust immunological reaction (5-7). In total, ~80% of GBM recurrences manifest within or on the periphery of the radiation field, highlighting the significant influence of local variables on the recurrence of the tumor. The localized recurrence significantly correlates with a notable reduction in progression-free survival (PFS), underscoring the imperative need for effective local treatment interventions (8). Additionally, the isolation of the brain by the BBB provides a distinctive chance for aggressive local treatment with minimal risk of systemic toxicity. In recent decades, several local therapy (LT) strategies have been developed. These include local thermal or laser therapy, local injection of immunotoxins via convection-enhanced delivery systems and implantation of Carmustine Wafers (CWs) into the resection cavity (9,10). Intracavitary radioimmunotherapy and Tumor Treating Fields (TTF) represent other examples of localized therapeutic strategy aimed at delaying or potentially preventing local tumor recurrence (11).

The 2021 World Health Organization (WHO) classification (12) of central nervous system (CNS) tumors brought significant revisions, particularly concerning GBM. These updates involved molecular parameters, refining GBM subtypes such as isocitrate dehydrogenase [NADP(+)] (IDH)-wild-type and IDH-mutant. It is crucial to note that each of these subtypes has distinct clinical and prognostic implications. For instance, IDH-wild-type GBM is associated with a more aggressive disease course and poorer prognosis

compared with IDH-mutant GBM. In addition, the emergence of new entities, such as diffuse midline glioma with histone H3 K27M mutation further complicates historical comparisons, emphasizing the need for updated diagnostic criteria and standardized reporting for consistency across studies (12). The new classification represents a significant temporal landmark, which can make it challenging and potentially misleading to compare studies conducted before and after this time point. Therefore, it is crucial to be aware of these complexities when interpreting and applying research findings.

Despite the limited or marginal improvements demonstrated by LT over current standard radio-chemotherapy, its future potential is promising. This is particularly true in light of recent advancements in gene-editing technologies and novel molecular and genetics discoveries, which are opening up new possibilities and avenues for treatment. The present review aimed to provide a historical review of LT and summarize the LTs that are currently being investigated or explored in GBM management.

2. Study selection

Study design and search strategy. The present review failed to satisfy the inclusion prerequisites set forth by the International Prospective Register of Systematic Reviews (PROSPERO) due to its specific focus on the evolution of LT for glioma over the past two decades. Consequently, the study protocol was not recorded within the PROSPERO database.

The present review constituted a systematic review of existing literature, conducted in accordance with the Preferred Reporting Items for Systematic Reviews (PRISMA) statement guidelines (13). Both prospective and retrospective clinical studies were considered. The search strategy of the pertinent literature was conducted by screening four distinct medical databases: Mendeley (<https://www.mendeley.com/reference-management/mendeley-cite>), Cochrane Library (<https://www.cochranelibrary.com/library>), EMBASE (<https://www.elsevier.com/products/embase>) and MEDLINE (<https://pubmed.ncbi.nlm.nih.gov/>), from January 1990 to December 2023. The following keywords, either singularly or in combination (using the Boolean operator 'AND'), were examined in all abstracts of English-language publications: 'glioma', 'gliomas', 'high grade glioma', 'glioblastoma', 'surgery', 'Intracavity Therapy', 'brachytherapy', 'immunotherapy', 'thermotherapy', 'laser interstitial thermal therapy', 'magnetic hyperthermia', 'magnetic field', 'nanomaterial', 'focused ultrasound therapy', 'gene therapy', 'tumor treating fields', 'virotherapy', 'oncolytic', 't-cell', 'engineered cell' and 'local treatment'. In the present study, two authors conducted the initial review of titles and abstracts, with any discrepancies resolved by consensus among three senior authors. Additionally, the references cited in each paper were scrutinized for relevant articles. The accuracy and completeness of all extracted data were verified by two independent authors. For ongoing clinical trials, a search of ClinicalTrials.gov was conducted, specifically for trials related to GBM with statuses such as 'not yet recruiting', 'recruiting', 'enrolling by invitation', 'active, not recruiting' or 'available'.

Inclusion and exclusion criteria. All Studies were included based on the following criteria: i) Published in the English language; ii) clinical trials, encompassing single-arm or double-arm studies, with a focus on both randomized controlled and non-randomized controlled trials; iii) investigations on immunotherapy strategies for GBM, whether as stand-alone or combined therapies with chemotherapy and/or RT; and iv) studies incorporating OS and PFS among the analyzed LT options. The exclusion criteria comprised: i) Editorials, case reports, case series, cohort studies, literature reviews and meta-analyses; ii) studies lacking clear definition of methods and/or results; and iii) studies without reported data on PFS or OS. The identified studies were imported into Endnote X9 (<https://support.clarivate.com/Endnote/s/article/EndNote-X9>) and duplicates were removed. In the present study, two independent authors assessed the results against the inclusion and exclusion criteria, with any disagreements resolved by a third author. Eligible articles then underwent full-text screening.

Data extraction. The following details were extracted for each study: Author information, publication year and journal, title, clinical trial name and phase, patient count, diagnosis, duration of follow-up, treatment type and outcomes. The primary outcomes assessed were OS and PFS following LT for glioma.

Risk of bias assessment. The Newcastle-Ottawa Scale was employed to evaluate the quality of the studies included in the present review (14). Quality assessment included the evaluation of selection criteria, comparability among studies and outcome assessment. A maximum score of 9 was considered ideal, with higher scores indicating greater study quality. Studies that received ≥ 7 points were classified as high-quality and included in the present review. The quality assessment was independently conducted by two authors. In cases of discrepancies, a third author re-examined the study.

Study selection process. Using a combination of keywords, MeSH and Emtree hierarchical terms, the authors found 2,711 potentially relevant articles, which were saved in a unique PubMed (.nbib) file and imported into Endnote to identify possible duplicates. For ongoing clinical trials, the same keywords were searched on ClinicalTrials.gov for the disease, 'glioblastoma' and 'glioma', leading to 171 potentially relevant trials. After the removal of duplicates and studies published before 2010, 619 studies were deleted. The remaining 2,263 studies were screened by title and abstract, leading to the exclusion of another 2,041 studies (Cohen's κ coefficient=0.92). Finally, 222 studies were sought for retrieval and fully assessed for eligibility leading to the final inclusion of 46 studies. The study selection process is outlined in Figs. 1-3, adhering to the PRISMA guidelines.

Study characteristics. The selected reviewed studies were subsequently categorized into three groups according to the specific type of LT utilized: i) Intraoperative LT modalities; ii) local RT; and iii) local immunotherapy. Following the review of studies, it emerged that 25 (15-39), 10 (40-49) and 11 (50-55) clinical studies explored the efficiency of intraoperative LT modalities, local RT and local immunotherapy, respectively. Table I provides a summary of the primary clinical studies involving patients who underwent treatment with

intraoperative LT modalities, Table II outlines clinical investigations based on local RT and Table III presents clinical studies focusing on advancements in local immunotherapy.

3. BBB

GBM persists as one of the most resistant malignant tumors in the CNS, characterized by inevitable recurrence despite progressions in neurosurgery, chemotherapy and RT. Recurrences predominantly occur within or proximal to the resection cavity, typically within regions exposed to the highest radiation doses (2,3,9,10). There is thus an urgent requirement for novel therapeutic techniques to improve patient outcomes. In this clinical setting, LTs have gained significant interest as a developing approach. This is due to their potential to overcome the constraints associated with conventional glioma treatment protocols.

The brain presents a substantial challenge for the efficient delivery of pharmacological compounds owing to the presence of specialized interfaces governing the exchange between the peripheral blood circulation and the cerebrospinal fluid (CSF) circulatory system. These interfaces include the choroid plexus epithelium (regulating blood-ventricular CSF), the arachnoid epithelium (regulating blood-subarachnoid CSF) and the blood-brain interstitial fluid. The BBB, formed by endothelial cells, limits the paracellular flux of hydrophilic molecules through tight junctions (TJs). The endothelial cells are surrounded by a basal lamina, and astrocytic glial cells provide biochemical support, regulate blood flow, supply nutrients, maintain ion balance and contribute to repair processes. Essential elements of the BBB supporting system include brain capillary endothelial cells, extracellular base membrane, pericytes, astrocytes and microglia. In detail, TJs are complex networks of transmembrane and cytoplasmic strands that are found on the apical portion of endothelial cells. They are made up of integral membrane proteins termed claudin, occludin and junction adhesion molecules. In addition, adherens junctions (AJs), situated below TJs in the basal region of the lateral plasma membrane, involve transmembrane glycoproteins (cadherins) linked to the cytoskeleton, enhancing the structural integrity between adjacent endothelial cells at the BBB. The ability of the BBB to control the passage of solutes and other substances is thus greatly supported by both TJs and AJs (26,54,56,57).

Overall, the BBB is a specialized structure that tightly regulates the molecular transit into the CNS. Typically, the relative impermeability of the BBB protects the brain from circulating toxins, maintaining an optimal microenvironment for neuronal function. Nevertheless, these obstacles impede efficient medication administration in disorders of the CNS, such as tumors (56,57). Hence, contemporary therapeutic strategies emphasize the endeavor to overcome BBB obstacles by administering treatments directly into or in close proximity to the tumor cavity. The present review explores the spectrum of currently accessible and emerging techniques, including both LTs and the latest advancements in immunotherapeutic drugs and genetically engineered cell therapies (Fig. 4).

4. Local treatments

Over time, a multitude of instruments have been developed to aid brain tumor surgery (9,10). Instruments such as

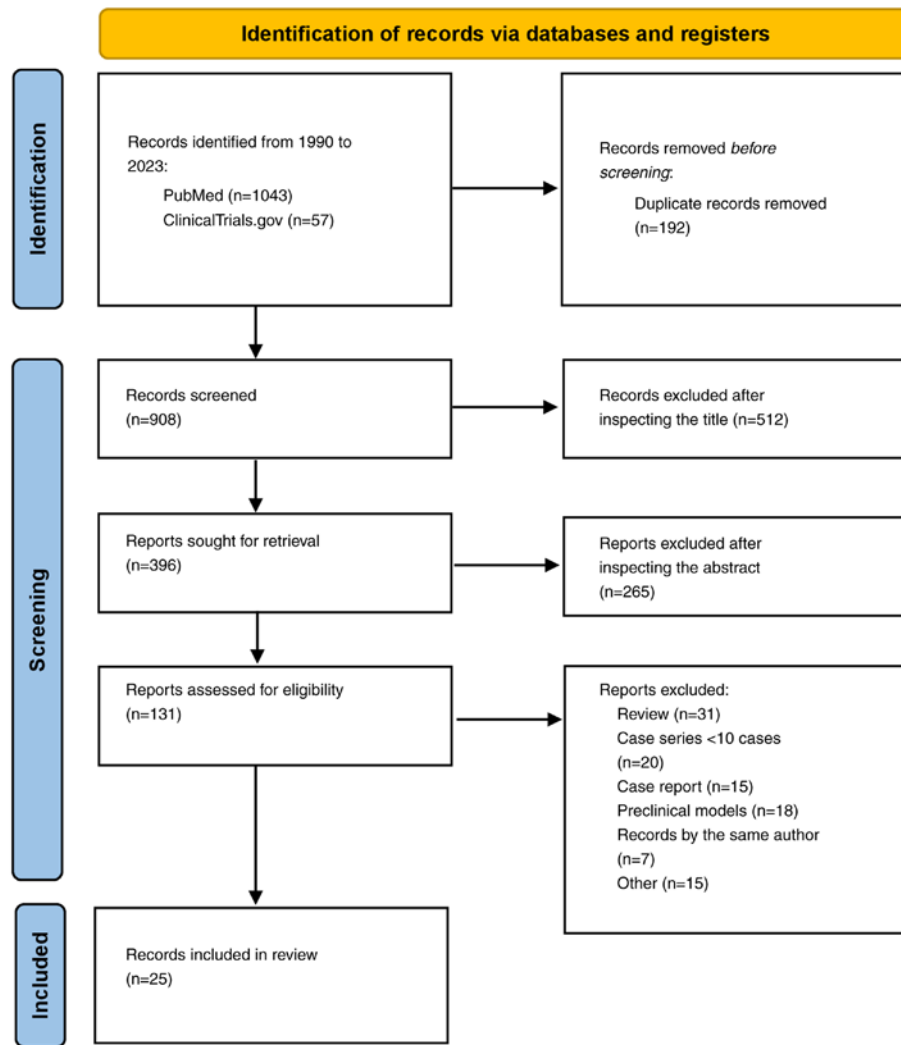


Figure 1. Preferred Reporting Items for Systematic Reviews flow-chart summarizing the inclusion and exclusion criteria for local treatments studies, including local laser interstitial therapy, focused ultrasound, magnetic therapy and Carmustine Wafers in the present systematic review.

surgical microscopes, high-resolution imaging, fluorescence-guided surgery and neuro-navigation are extensively employed in neurosurgery but fall outside the scope of the present review. At present, four main approaches, laser interstitial thermal therapy (LITT), magnetic hyperthermia (MH), (TTF) and focused ultrasound (FUS), are undergoing regulatory approval at different stages for the LT of GBM (Fig. 5).

Local thermal therapy (LTT). LTT, known since the 1890s, has a recognized ability to disrupt the BBB (58). The effectiveness of LTT is primarily ascribed to its ability to utilize heat, thus triggering programmed cell death and tissue necrosis in GBM cells. In addition to directly inducing apoptosis and necrosis, hyperthermia elicits supplementary outcomes, including the activation of immune responses, heightened susceptibility of GBM cells to RT and chemotherapy and temporary disruption of the BBB (9). The current use of LTT in patients with glioma reflects a dynamic landscape of research and clinical applications, with ongoing efforts aimed at refining techniques, optimizing treatment protocols and expanding their integration into comprehensive treatment

strategies for brain tumors. Due to the inadequate quality of the existing literature, it is not possible to offer conclusive findings about the cost-effectiveness of LTT for patients with GBM.

LITT. Recent technological advancements have facilitated the emergence of LITT as a promising treatment modality, particularly advantageous in situations where traditional open surgical approaches are deemed suboptimal, either due to surgical complexities or the frail condition of the patient (15-25). These technological advancements include laser probe design, cooling mechanisms, stereotactic targeting hardware and real-time thermography (18,59,60). Furthermore, two extensive studies comparing patients who underwent LITT for primary GBM with a control group found that the overall risk of complications was ~15%. However, there were no significant differences in PFS or OS between the two groups (18,60). A subsequent analysis revealed that LITT is a valid and effective choice for treating unifocal, lobar and recurrent GBM compared with a similar group of patients who underwent a second surgery (61). In addition, a recent study comparing surgically accessible recurrent GBM found

Table I. Clinical studies assessing intraoperative local treatment modalities (LITT, FUS, MH, TTF and CWs) in patients with GBM.

First author, year	Study	No. of patients	Pathology	Pre-treatment	Post-treatment	Complications	OS	(Refs.)
Mohammadi <i>et al</i> , 2014	Multicenter retrospective	34 (35 procedures)	24 GBM; 10 anaplastic oligodendroglioma	18 RT + CT	14 RT or CT; 13 RT + CT	7 worsening of preoperative motor deficit; 1 seizure; 1 postoperative hyponatremia; 1 bilateral deep vein thrombosis; 1 superficial wound infection; 1 ventriculitis	1-year estimate of OS was 68%. Median PFS was 5.1 months	(15)
Thomas <i>et al</i> , 2016	Single-institution retrospective	21 (8 newly diagnosed; 13 recurrent)	GBM	6 GTR; 5 STR; 12 RT; 12 TMZ; 2 additional bevacizumab; 1 stereotactic radiosurgery previously	5 adjuvant combination of CCNU and bevacizumab	1 functional decline; 1 status epilepticus	Median, 8 months in newly diagnosed group; 7 months in recurrent group	(16)
Beaumont <i>et al</i> , 2018	Multicenter retrospective	15 (9 newly diagnosed; 6 recurrent)	13 GBM; 2 LGG	4 craniotomy + RT + CT; 1 biopsy + RT + craniotomy + CT; 1 RT + CT	11 CT + RT	3 hemiparesis; 1 edema and herniation; 1 ventriculitis; 1 weakness; 1 hydrocephalus	18.2 months	(17)
Kamath <i>et al</i> , 2019	Single-institution retrospective	54 (58 procedures; 17 newly diagnosed; 41 recurrent)	GBM	35 resection + CT; 17 biopsy; 5 CT	53 CT; 15 RT; 3 surgery; 10 other (tumor-treating field; vaccines)	3 cerebral edema; 3 seizures; 1 hydrocephalus; 1 hyponatremia; 1 infection; 2 mortalities	11 months	(18)
O'Connor <i>et al</i> , 2020	Single-institution retrospective	43	recurrent GBM	-	-	2 intracranial hypertension; 1 weakness; 1 skin dehiscence; 1 CSF leak	-	(19)
Traylor <i>et al</i> , 2021	Single-institution retrospective	69 (20 newly diagnosed; 49 recurrent)	GBM	28 GTR; 41 not GTR	47 CT; 19 RT	17 neurological complication; 4 seizure; 3 impaired cognition; 1 urinary tract infection; 1 pneumonia; 1 hyponatremia; 1 pulmonary embolism; 1 acute kidney injury	Mean, 12 months	(20)

Table I. Continued.

First author, year	Study	No. of patients	Pathology	Pre-treatment	Post-treatment	Complications	OS	(Refs.)
A, LITT								
de Groot <i>et al</i> , 2022	Multicenter prospective	89 (29 newly diagnosed; 60 recurrent)	GBM	53 resection; 54 CT; 53 RT	57 CT; 19 RT; 9 immunotherapy	5 neurological deficits; 4 edema; 1 seizure; 1 hemorrhage; 1 deep vein thrombosis	Median, 9.7 months in newly diagnosed group; 8.9 months in recurrent group	(21)
Johnson <i>et al</i> , 2022	Single-institution retrospective	22	IDH 1/2 mutant gliomas	14 resection (GTR/STR); 12 RT; 10 CT; 4 biopsies; 1 radiosurgery	9 RT + CT; 4 CT; 1 STR + RT + CT; 1 CT + γ knife	1 edema; 1 seizure; 1 deep vein thrombosis	Only PFS reported (mean 5.2 months)	(22)
Muir <i>et al</i> , 2022	Single-institution retrospective	20	GBM	4 RT; 3 CT	13 RT; 12 CT	12 new or worsened motor deficit; 2 seizure	11 months	(23)
Kaisman-Elbaz <i>et al</i> , 2023	Single-institution retrospective	56	GBM multiforme	-	50 CT; 39 additional oncological treatment	1 mortality; 4 permanent neurological deficit	-	(24)
Jubran <i>et al</i> , 2023	Single-institution retrospective	49	31 recurrent GBM multiforme; 18 radiation necrosis	20 stereotactic radiosurgery; 37 RT; 49 CT	-	3 worsening aphasia; 1 seizure; 1 epidural hematoma; 1 intraparenchymal hemorrhage	20 months	(25)
B, FUS								
First author, year	Study	No. of patients	Pathology	Pre-treatment	Post-treatment	Complications	OS	(Refs.)
Guthkelch <i>et al</i> , 1991	Retrospective	15	11 GBM multiforme; 4 anaplastic astrocytoma	Craniectomy	10 resection + RT; 5 RT	4 hemorrhage; 2 thermal lesion, 2 CSF leak	11.8 months	(26)
Carpentier <i>et al</i> , 2016	Prospective phase I/IIa clinical trial	15	recurrent GBM	15 RT + TMZ; 9 resection	15 CT (carboplatin-based chemotherapy)	1 facial pain; 1 vagal episode with bradycardia followed by tachycardia; 1 edema; 2 cerebellar vascular stroke	-	(27)

Table I. Continued.

C, MH								
First author, year	Study	No of patients	Pathology	Pre-treatment	Post-treatment	Complications	OS	(Refs.)
Stea <i>et al</i> , 1994	Prospective phase I/II Trial	33	22 GBM (17 primary, 5 recurrent); 11 anaplastic astrocytomas (8 primary, 3 recurrent)	Surgical debulking	RT: 48.4 Gy, interstitial brachytherapy: 13.9-50	11 (33.3%) cerebral edema, 11 (33.3%) focal seizures, 2 (6.1%) pulmonary embolism	Primary, 23.5 months (control, 13.5 months); recurrent, 12 months (control, 12 months)	(28)
Maier-Hauff <i>et al</i> , 2011	Prospective phase II Trial	59	Recurrent GBM	Stereotactic beam RT (30 Gy)	Stereotactic beam RT (30 Gy)	14 (21.2%) motor disturbances, 15 (22.7%) focal convulsions; 6 (9.1%) grade 1-3 thermal stress, temperature >38°C; 9 (13.6%) headaches	From tumor recurrence, 13.4 months (95% CI, 10.6-16.2)	(29)
D, TTF								
First author, year	Study	No. of patients	Pathology	Pre-treatment	Post-treatment	Complications	OS	(Refs.)
Stupp <i>et al</i> , 2012	Randomized phase III trial	237 TTF alone (n=120) or active chemotherapy control (n=117)	Recurrent GBM	Surgery and different postoperative treatments. Number of prior treatments was two (range 1-6)	-	The TTF-related adverse events were mild (14%) to moderate (2%) skin rash beneath the transducer arrays. Severe adverse events occurred in 6 and 16% (P=0.022) of patients treated with TTF and chemotherapy, respectively. Quality of life analyses favored TTF therapy in most domains	Median survival was 6.6 vs. 6.0 months (HR, 0.86; 95% CI, 0.66-1.12; P=0.27), 1-year survival rate was 20% respectively in TTF and active control groups	(30)

Table I. Continued.

First author, year	Study	No of patients	Pathology	Pre-treatment	Post-treatment	Complications	OS	(Refs.)
C, MH								
Stupp <i>et al</i> , 2012	Randomized controlled trial	After completion of chemoradiotherapy, patients with GBM were randomized (2:1) to receive maintenance treatment with either TTF + TMZ (n=466) or TMZ alone (n=229)	GM newly diagnosed	All patients underwent surgery and had completed radiotherapy and concomitant TMZ as per local practice	-	The overall incidence, distribution and severity of adverse events were similar in patients treated with TTF + TMZ and in those treated with TMZ alone. Mild to moderate skin irritation was observed in 43% of patients treated with TTF + TMZ and severe skin reaction (grade 3) in 2%	Median overall survival in the per-protocol population was 20.5 months (95% CI, 16.7-25.0) in the TTF + TMZ group (n=196) and 15.6 months (95% CI, 13.3-19.1) in the TMZ alone group (n=84; HR, 0.64; 99.4% CI, 0.42-0.98; P=0.004)	(31)
E, CWs								
Vinjamuri <i>et al</i> , 2009	Randomized controlled trial	48 with CW 32 controls	GBM	-	Chemoradiation standard protocol	-	Median OS was superior in the TMZ vs. the BCNU group (15.9 vs. 11.5 months) and the curves were judged to be significantly different by the log-rank test (P<0.02)	(32)
De Bonis <i>et al</i> , 2012	Randomized controlled trial	10 with CW 67 controls	IV	-	Adjuvant therapy with TMZ	The toxicity after CW use was significantly higher, both for patients with newly diagnosed GBM and patients with recurrent GBM. Patients with 8 Gliadel wafers implanted had a 3-fold increased risk of adverse events. Patients with recurrent tumor had a 2.8-fold increased risk of adverse events	Adding CWs to standard treatment did not significantly improve the outcome	(33)

Table I. Continued.

First author, year	Study	No of patients	Pathology	Pre Treatment	Post-treatment	Complications	OS	(Refs.)
Catalán-Uribarrena <i>et al</i> , 2012	Randomized controlled trial	55 with CW 55 controls	HGG	-	Chemoradiation standard protocol	-	CW's group had a median survival of 13.414 months compared with 11.047 months in the group without implants (P=0.856)	(34)
Noël <i>et al</i> , 2012	Randomized controlled trial	28 with CW 37 controls	HGG	-	Chemoradiation standard protocol	4 cases of grade 3 thrombopenia occurred, all in the CW group	For patients treated with and without CWs, median and 1-year OS were 20.6 months and 78.6% vs. 20.8 months and 78.4%, respectively	(35)
Pallud <i>et al</i> , 2015	Randomized controlled trial	354 with CW 433 controls	IV	-	Chemoradiation standard protocol	The rate of postoperative non-infectious adverse events did not differ significantly between the implantation group and the standard group, except for raised intracranial pressure (P=0.004). The rate of postoperative overall infections was significantly higher in the implantation group (7.1%) than in the standard group (1.5%) (P=0.001)	The median overall survival was 20.4 and 18.0 months in the CWs and non-CW's groups, respectively	(36)
Roux <i>et al</i> , 2017	Randomized controlled trial	123 with CW 217 controls	IV	-	Standard combined chemoradiotherapy	CW's did not show a significant rise in postoperative complications, including postoperative infections	CW's implantation was independently associated with a longer OS (P=0.0290)	(37)
Akiyama <i>et al</i> , 2018	Randomized controlled trial	25 with CW 29 controls	IV	-	Standard combined chemoradiotherapy	The occurrence of adverse events was comparable among the treatment groups, except for infections, which were more prevalent in the CWs group (3.5 vs. 0%)	The median OS in the CWs and non-CW's groups were 24.2 and 15.30 months, respectively (P=0.027)	(38)

Table I. Continued.

First author, year	Study	No of patients	Pathology	Pre Treatment	Post-treatment	Complications	OS	(Refs.)
Bos <i>et al</i> , 2023	Human phase I study	15 recurrent GBM	Recurrent GBM	-	Surgery and various treatments	Second surgery and intra- and peritumoral infusion of hrBMP4	1 patient showed partial response and 2 patients a complete (local) tumor response, which was maintained until the most recent follow-up, 57 and 30 months post-hrBMP4. Tumor growth was inhibited in areas permeated by hrBMP4	(39)

CCNU, chloroethyl-cyclohexyl-nitrosourea; CSF, cerebrospinal fluid; CT, chemotherapy; CWs, Carmustine Wafers; FUS, focused ultrasound; GBM, glioblastoma; GTR, gross total resection; LITT, laser interstitial thermal therapy; MH, magnetic hyperthermia; OS, overall survival; PFS, progression free survival; RT, radiotherapy; STR, subtotal resection; TMZ, temozolomide; TTF, Tumor Treating Fields; hrBMP4, human recombinant bone morphogenetic protein 4; HR, hazard ratio; CI, confidence interval.

Table II. Clinical investigations assessing local radiotherapy in patients with GBM.

First author, year	Design	Sample	Age, years	Setting	Dose	Outcome	Toxicity	(Refs.)
Chan <i>et al</i> , 2005	Monocentric, retrospective	24	48.1	Recurrent GBM	53.1 Gy	Median Survival from diagnosis, 23.3 months; after BCT 9.1 months	1 patients wound infection, 2 symptomatic radiation necrosis	(40)
Schueller <i>et al</i> , 2005	Monocentric, retrospective	45	56	Newly diagnosed GBM	20 Gy	Median OS, 14.2 months; time to local failure, 9.9 months	2.8% radiation necrosis, 5.6% hemorrhage	(41)
Gabayan <i>et al</i> , 2006	Multicenter, retrospective	95	51	Recurrent grade 3 and 4 gliomas	Median, 60 Gy	Median survival from BCT, 36.3 weeks	8 RTOG grade 2 toxicity, 2 grade 3 who required reoperation for symptomatic radiation necrosis	(42)
Chen <i>et al</i> , 2007	Phase 1	18	50	Newly diagnosed GBM	400 Gy	OS, 114 weeks; PFS, 57 weeks	11 patients underwent reoperations for radiation necrosis	(43)
Welsh <i>et al</i> , 2007	Multicenter, retrospective	20	59	Newly diagnosed GBM	Median dose, 50 Gy	Average survival, 11.4 months	3 patients (14%) grade 3 CNS toxicity	(44)
Chino <i>et al</i> , 2008	Monocentric, Retrospective	32	-	Recurrent and newly diagnosed GBM	Median 60 Gy	Average survival after BCT, 12.5 months	1 leak from BCT balloon	(45)
Fabrini <i>et al</i> , 2009	Monocentric, retrospective	21	60	Recurrent GBM	18 Gy	Median OS, 21.7 months; median survival after recurrence, 8.0 months	1 patients had a fatal venous hemorrhage, 2 patients had asymptomatic radionecrosis	(46)
Usyckin <i>et al</i> , 2013	Monocentric, retrospective	12	48	Newly diagnosed GBM	Median dose, 12.5 Gy	Median OS, 13 months	Radiation necrosis, 9.4%; hemorrhage, 3.1%	(47)
Schwartz <i>et al</i> , 2015	Monocentric, retrospective	40	57.6	Recurrent GBM	50 Gy	Median OS, 41.8 months; PFS, 8.3 months	3 patients grade I, 1 grade II and 2 grade IV edema-associated toxicity	(48)
Sarria <i>et al</i> , 2020	Multicenter, retrospective	51	55	Newly diagnosed GBM	Median dose, 10 Gy	Median OS, 18 months; PFS, 11.4 months	25.5% radiation necrosis	(49)

GBM, glioblastoma; OS, overall survival; PFS, progression free survival; RTOG, Radiation Toxicity Oncology Grading; BCT, brachytherapy.

Table III. Local immunotherapy clinical trials in patients with GBM.

Immunotherapy	Target	Clinical trial identifier	Study phase	No. of patients	Setting	Trial design	Outcomes	Status
CAR-T cells	IL-13R α 2	NCT01082926	1	6	rGBM	Intratumoral infusion of GRm13Z40-2	OS, 19.7 months	Completed
		NCT02208362	1	1	rGBM	Intracavitary infusion CAR-T cells targeting IL-13R α 2	PFS, 7.6 months	Not recruiting
	B7-H3	NCT04670068	1/2	40	rGBM	Intratumoral injection of B7-H3 CAR-T cells between TMZ cycle	NA	Recruiting
Checkpoint inhibitors	EGFRvIII	NCT03283631	1	24	rGBM	CAR-T intracerebral with dose escalation	NA	Recruiting
	CAR-T (IL-13R α 2) + PD1	NCT04003649	1	60	rGBM	Intracranial infusion of CAR-T [IL-13R α 2] + EV nivolumab and ipilimumab	NA	Recruiting
Oncolytic viruses	DNX-2401 + PD1	NCT02798406	1/2	49	rGBM or gliosarcoma	Intratumoral DNX-2401 followed by pembrolizumab (anti-PD1)	OS, 12.3 months; ORR, 10.4 months	Completed
	Toca 511	NCT02414165	2/3	403	rGBM	Toca511 intracavitary followed by TocaFC administration vs. SOC	Median OS ITT, 11.1 (E) vs. 12.2 (S) months	Completed
	DNX-2401	NCT01956734	1	31	rGBM	DNX-2401 intratumoral injection + TMZ	NA	Completed
	HSV	2004-000464-28 (ASPECT)	3	250	New GBM diagnosis	Surgical resection + intraoperative perilesional injection of HSV-thymidine kinase followed by ganciclovir + SOC vs. resection and SOC alone	Median OS, 16 (E) vs. 14 (S) months	Completed
	Parvovirus	NCT01301430	1/2	18	New GBM diagnosis or rGBM	Parvovirus either intratumoral or EV + surgical resection 10 days later	NA	Completed

Table III. Continued.

Immunotherapy	Target	Clinical trial identifier	Study phase	No. of patients	Setting	Trial design	Outcomes	Status
	Poliovirus	NCT0149189 Desjardins <i>et al</i> , 2018 (55)	1	61	rGBM	Sabin type 1 poliovirus (PVSRIPO) intratumoral	Median OS, 12.5 months	Completed

ITT, intention-to-treat population; GBM, glioblastoma; E, experimental arm; S, standard arm; rGBM, recurrent GBM; EV, intravenous; TMZ, temozolomide; PFS, progression free survival; DNX-2401, δ -24-RGD adenovirus; ORR, objective response rate; HSV, herpes simplex virus; OS, overall survival; CAR-T, chimeric antigen receptor T cell.

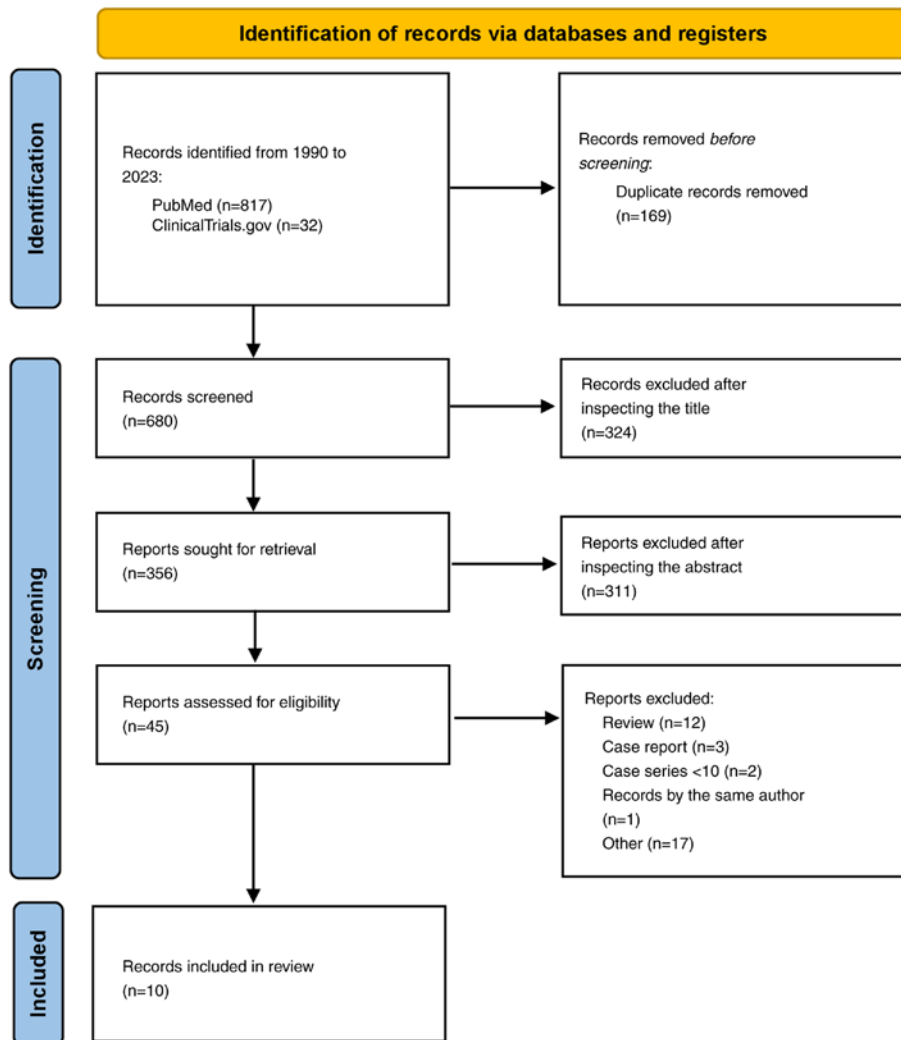


Figure 2. Preferred Reporting Items for Systematic Reviews flow-chart summarizing inclusion and exclusion criteria for local radiotherapy studies in the present systematic review.

no significant differences in survival outcomes or morbidity between LITT and repeat surgery. However, LITT was associated with shorter hospital stays and more efficient post-operative care (61). Similar to other clinical studies conducted on patients with brain tumors, research on LITT often consists of retrospective observational studies with a limited number of patients (15-25). However, to obtain more reliable results,

it is necessary to conduct a meticulously planned prospective multicenter randomized controlled study.

FUS. Recent developments in FUS technology have increased its viability and safety for the treatment of numerous intracranial diseases (62). In summary, FUS technology precisely guides ultrasound beams to specific areas of the brain, targeting

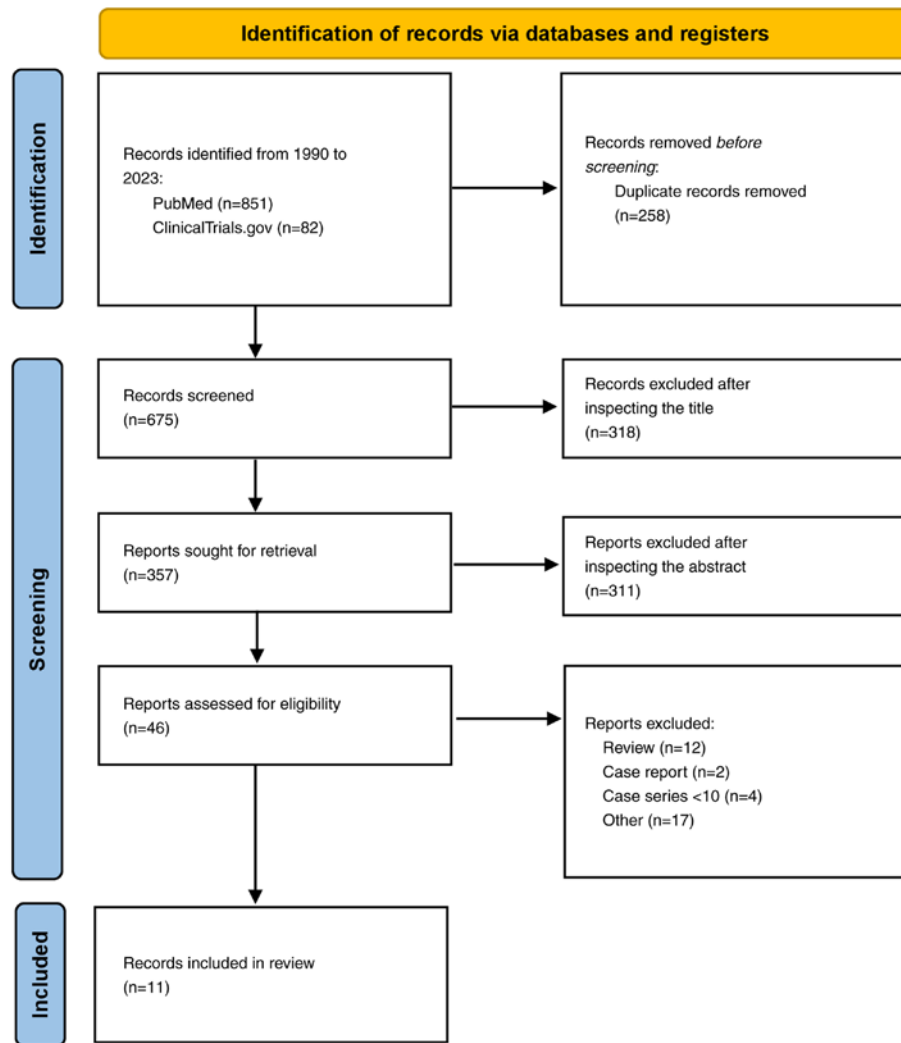


Figure 3. Preferred Reporting Items for Systematic Reviews flow-chart summarizing inclusion and exclusion criteria for local immunotherapy studies in the present systematic review.

tumor cells while minimizing damage to healthy tissue (26,27). The FUS technology is extensive, primarily categorized into high-intensity FUS (HIFUS) and low-intensity FUS (LIFUS) according to frequency (63-65). The two main categories of FUS infer thermal and non-thermal effects. The goal of HIFUS treatment in GBM is to employ heat to thermally ablate the tumor and the peritumoral surrounding tissue. HIFUS causes tissue heating, DNA fragmentation and protein denaturation by molecular vibration. (66). However, LIFUS is mostly dependent on non-thermal phenomena such as sonic cavitation and mechanical disturbance. When administered intravenously to the target location in conjunction with LIFUS, microbubbles enhance the administration of therapeutic drugs and facilitate liquid biopsies (63-65).

During FUS treatment for intracranial malignancies, steady cavitation is thus utilized to increase the permeability of the BBB, thereby facilitating drug delivery by loosening tight junctions. However, inertial cavitation causes direct harm to tissues by temporarily breaking the BBB (64,65,67). LIFUS can also induce the release of pro-inflammatory cytokines and stress responses in intra-tumoral immune cell populations and increase dendritic cell activity (68). When combined, these

actions hold the promise of overcoming immune evasion mechanisms initiated by GBM, potentially triggering an anti-tumor immune response that is not just relevant but could be a significant breakthrough in the field (68).

MH. MH is a form of targeted thermal therapy where electromagnetic energy is transformed into heat by activating magnetic nanoparticles or mediators within the tumor or resection cavity using an external alternating magnetic field. Apoptotic and necrotic cell deaths are directly caused by thermal energy delivered to the tumor site (69), which also indirectly triggers an immunological response in a ‘cold’ immunological site such as GBM (70). Following MH, heat shock proteins, which attach to antigen-presenting cells directly and then secondarily trigger an immune response dependent on CD8⁺ T cells, were found to be significantly upregulated in preclinical investigations conducted on primary tumor cells and animal models (71). Additionally, major histocompatibility complex class I and natural killer group 2, member D (NKG2D) ligand are more highly expressed in heated tumor cells, rendering them more vulnerable to lysis by CD8 and natural killer T cells (72).

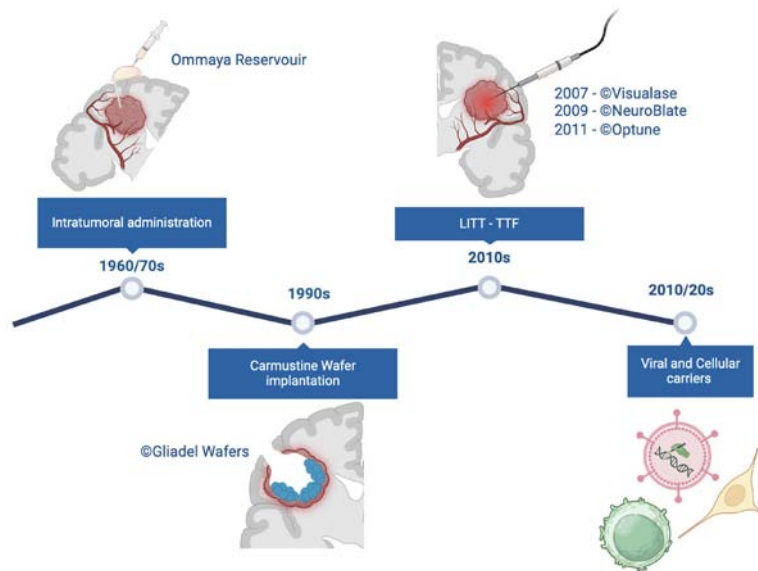


Figure 4. Schematic illustrations of historical development and application of localized drug delivery strategies for glioblastoma treatment. LITT, laser interstitial thermal therapy; TTF, Tumor Treating Fields.

The idea of heat generation and selective distribution of magnetic particles was initially proposed by Gilchrist *et al* (73) in the late 1950s. Stea *et al* (74) presented the first clinical trial describing the use of MH for primary malignant brain tumors in 1990 and subsequently conducted a prospective phase I/II experiment in 1994 (28) assessing the efficacy of brachytherapy (BCT) and interstitial thermotherapy in treating primary and recurrent high-grade glioma (HGG) following surgical resection. In this study, a noteworthy correlation between survival and hyperthermia [hazard ratio (HR), 0.53; 95% confidence interval (CI), 0.29-0.94] in the case of primary tumors was discovered. However, a relevant proportion of complications were also documented in the study, which included hydrocephalus, intracranial hemorrhage, episodic seizures and elevated edema. In a separate phase I investigation, 6 patients with recurrent GBM were found to exhibit a substantial edematous response to superparamagnetic iron oxide nanoparticles. Of these patients, 4 required high-dose corticosteroid therapy, and another craniotomy was necessary to remove the particles (70).

Direct stereotactic injection of nanoparticles into the tumor is another proposed form of delivery. The results of a prospective non-randomized study involving 59 patients with recurrent GBM who received repeated sessions of stereotactic RT and thermotherapy were presented by Maier-Hauff *et al* (29). When patients receiving MH were compared with historical controls from previous investigations, the authors found a significant survival advantage (OS from recurrence, 13.2 vs. 6.2 months). However, the study also reported significant side effects, including worsening of motor deficits, focal convulsions and grade 1-3 thermal stress.

The optimal treatment strategy for MH remains inadequately evaluated. Although preliminary research indicates that it may be useful in treating HGGs, more validation in randomized controlled trials is essential. However, MH also deserves careful examination due to the relationship with multiple potential complications, which may limit its application in routine clinical practice.

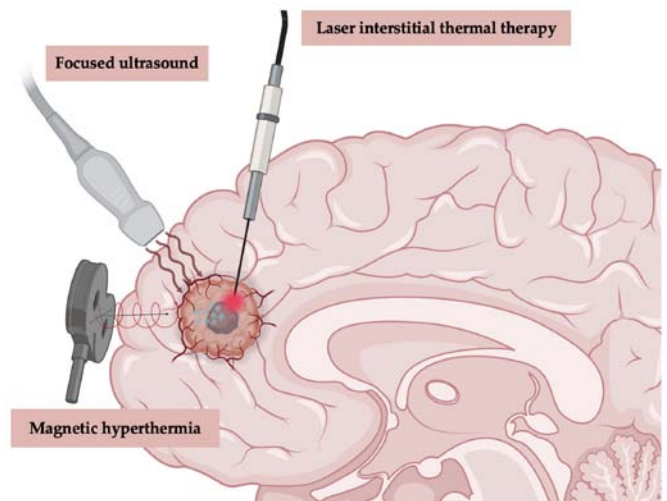


Figure 5. Main local thermal treatment strategies for glioblastoma. In laser interstitial thermal therapy, a laser probe is inserted under MRI guidance to deliver optical radiation and induce thermal damage to the tumor. High intensity focused ultrasound or stimulation of ferromagnetic implanted nanoparticles via an external electromagnetic field (magnetic hyperthermia) also lead to a localized thermal effect and ablation of tumoral tissue.

TTF. TTF represents a divisive and debated therapeutic approach to GBM management. TTF constitutes an antimetabolic therapy that uses transducer arrays applied to the shaved scalp to deliver low-intensity, intermediate-frequency (200 kHz) alternating electric fields. These fields exert anti-mitotic effects by disrupting microtubule assembly during cell division, resulting in tumor cell death (75-77). The TTF device for recurrent GBM received US Food and Drug Administration (FDA) approval in 2011 based on a phase III clinical trial (EF-11). This trial compared the efficacy of TTF with the best choice of chemotherapy (as determined by the physician) in patients with recurrent GBM, demonstrating comparable efficacy between the two treatments. However, patients receiving TTF experienced an improved quality of life and less

toxicity (30). In 2015, TTF therapy received FDA approval for treating patients with newly diagnosed GBM. This approval was based on the EF-14 clinical study (NCT00916409), which demonstrated a significant extension of PFS and OS time when TTF therapy was combined with maintenance TMZ (31). The National Comprehensive Cancer Network also incorporated the TTF device as a viable option for treating newly diagnosed GBM. However, Despite FDA endorsement, doubts persist surrounding this therapy (75).

After gaining approval in the US, subsequent regulatory approvals in Europe and Asia in recent years have heightened awareness of TTF therapy among a wider range of patient populations and treatment centers. In a recent meta-analysis, Ballo *et al* (77) analyzed 1,430 patients with GBM in a pooled analysis for OS time. The meta-analysis of comparative studies indicated a significant improvement in OS time for patients receiving TTF plus standard of care (SOC) vs. SOC alone ($P < 0.001$). Specifically, the OS time was 22.6 months for patients treated with TTF plus SOC, compared with 17.4 months for those receiving SOC alone.

Although a number of studies have assessed the safety and effectiveness of TTF, questions remain regarding research design, quality of life and therapeutic costs. These problems require further investigation, and ongoing trials are intended to yield more information regarding treatment outcomes and interactions in combination regimens.

5. Local treatment approaches and delivery systems for malignant gliomas

Given the notable drawbacks of systemic drug delivery options, local drug delivery techniques are seen as viable substitutes. The drawbacks of systemic methods include long delivery routes, which increase the chance of medication absorption by unwanted organs or clearance during blood circulation. Furthermore, the potential for systemic toxicity remains a notable concern. By contrast, local drug delivery techniques provide a focused and efficient approach, delivering drugs directly into the brain bypassing the limits of the BBB (9,78-82). Local drug delivery approaches encompass a growing number of research topics, including the continuous discovery of therapeutic nanomaterials and the continued development of pharmaceutical molecular design (9,10,78-82). Numerous intracranial implant-based delivery techniques are now under investigation (83-94).

Convention-enhanced delivery (CED). Since the 1994 study by Bobo *et al* (79), CED for gliomas has primarily remained under investigation in preclinical models (10). In CED, catheters extend past the cannula tip into the targeted tumor location and are proximally coupled to a syringe pump that contains the treatments components. Chemotherapy CED has demonstrated success in laboratory settings, but its application in clinical environments has encountered several challenges (80-82). These challenges highlight the necessity of addressing specific issues to enhance the implementation of CED in patient care. Failures of CED in glioma treatment can be attributed to several factors: i) Achieving uniform distribution within the tumor; ii) limitations in the design and placement of the probe; and iii) tracking the delivery of the

infusate. Since GBMs are highly infiltrative, effective drugs must discriminate between malignant and normal tissue while penetrating the tissue deeply to reduce the possibility of severe side effects (80-82). Several ongoing trials are investigating the CED of tumor-targeting compounds, encompassing cytokines, viruses, gene therapies and antibodies. Further details on these approaches will be discussed below.

Implanted delivery. Various preclinical models are currently under investigation to explore hydrogels, nanofibers and spray devices (80). Furthermore, nanoparticles can be used as carriers for the transport of pharmacological compounds and genetic material across the BBB. If properly engineered, nanoparticles can interact specifically with tumor cells, limiting damage to healthy cells (56). In this regard, biomaterial implants are becoming increasingly flexible therapeutic platforms capable of providing novel approaches in GBM treatments (83). A number of non-biodegradable ethylene-vinyl acetate copolymers (EVAc) and biodegradable materials [such as polyanhydride poly(bis(p-carboxy-phenoxy) propane-sebacic acid) copolymer, fatty acid dimer-sebacic acid copolymer, poly(lactic-co-glycolic acid) copolymer (PLGA) and poly- ϵ -caprolactone] have been explored for the local delivery of therapeutic agents including chemotherapy [such as paclitaxel, doxorubicin and bis-chloroethylnitrosourea (BCNU)] and anti-angiogenic (such as minocycline and endostatin fragment) drugs (84-86). These implantable biomaterials can be in different forms including wafers, discs, films, rods or meshes and can be fabricated using different methods such as electrospinning, solvent casting, extrusion or compression molding. The effectiveness of implantable drug delivery systems in treating recurrent cancer is potentially heterogeneous. Gliosis may hinder the delivery of drugs into the brain parenchyma and hamper access to tumor cells at tumor recurrence (56). The local administration of the anti-angiogenesis drug, minocycline, either in combination with systemic BCNU or alone, resulted in notable improvements in the median survival time in a rat brain tumor model without the need for excision (84).

Implanting a device containing EVAc and BCNU proved effective in reducing systemic toxicity while increasing local drug concentration (87). The device, created by dissolving the drug and polymer in methylene chloride, demonstrated potential antitumor effects in rat intracranial glioma models when delivering chemotherapy drugs, such as amsacrine and mitoxantrone, using EVAc. Additionally, PLGA, an FDA-approved copolymer, has been explored in studies. Xie and Wang (88) developed paclitaxel-loaded PLGA ultrafine-fiber implants for brain glioma treatment via electrospinning, achieving sustained drug release for >60 days. Another group utilized PLGA and paclitaxel in treating glioma, with the constructed electrospun paclitaxel-loaded PLGA fibrous meshes supporting drug release for 80 days (89). These implants resulted in much smaller tumors in a mouse subcutaneous C6 glioma *in vivo* model compared with the placebo and Taxol® injected control groups (89).

The topic of theranostic applications for the brain has seen a recent increase in interest, with an emphasis on the use of electronic devices such sensors and actuators. This represents a recent proposal that adds a new dimension to the ongoing

exploration of these technologies in the context of brain-related applications. The goal of this multidisciplinary strategy is to combine macroscopic and microscopic tactics to potentially revolutionize drug delivery options (78). For instance, in clinical practice, a solid implant for intracranial drug delivery in GBM is the biodegradable CWs. The US FDA approved the CW implantation strategy for the treatment of recurrent GBM and newly diagnosed HGG in 1996 and 2003, respectively, establishing a therapeutic bridge between adjuvant therapy and surgical resection (83). Despite the early promising results, the implantation of CWs in HGG has gradually been abandoned in typical clinical practice for a number of reasons (33-38,90). In a recent collaborative review by the Society for Neuro-Oncology-European Society of Neuro-Oncology, the authors stated that CWs offer a limited survival advantage of ~2 months, suggesting a limited use, primarily due to concerns related to safety and tolerability risks (91,92). Furthermore, the exclusion of CW-treated patients in later clinical trials, to prevent potential confounding effects brought by CWs, discourages its broad implementation (91,92).

Nevertheless, recent long-term follow-up studies have shown survival benefits in newly diagnosed patients with GBM treated with CW implantation, prompting a reevaluation of the therapeutic efficacy of CWs in selected cases, such as young patients with small lesions without ventricle opening during surgery. According to a recent study by Iuchi *et al* (93), implantation of CWs significantly extends OS (median OS time, 27.4 months; 2-year OS rate, 46%) in younger patients with an extent of resection >95%. The aforementioned study supports the critique directed towards the efficacy of CWs highlighted in a study by Champeaux and Weller (94), a 9-year nationwide retrospective study in which it was demonstrated that clinical and surgical factors (such as age, tumor volume, tumor side and extent of resection) may influence the survival benefit in patients receiving CWs, underling its potential efficacy in specific cases. In addition, although implantable CWs have been criticized in recent research, their efficacy and safety may be increased by adjusting the chemicals, dosage and implantation methods (95,96).

Human recombinant bone morphogenetic protein 4 (hrBMP4) has shown promise in preclinical studies for its ability to induce differentiation and reduce the self-renewal capacity of GBM stem-like cells (GSCs), which are often implicated in the aggressive nature and treatment resistance of GBM. By targeting these GSCs, BMP4 could potentially reduce tumor recurrence and improve patient outcomes (95). In a recent human phase I dose escalation trial, the efficacy and safety of hrBMP4 administered via CED was investigated in 15 patients with recurrent GBM. The results demonstrated that hrBMP4 was well-tolerated with no serious adverse events directly attributed to the treatment (39). The findings of these investigations suggest that local hrBMP4 delivery can inhibit tumor growth in areas exposed to the protein, highlighting the potential for hrBMP4 as a therapeutic approach for GBM.

Overall, CED bypasses the BBB to directly administer targeted therapies into malignant glioma tissue and surrounding areas. Despite being invasive, wafer and reservoir delivery systems offer the potential for prolonged compound delivery during disease progression. Although CED shows significant potential for advancing the treatment of GBM, continuous

research and refinement are necessary to fully harness its capabilities and address current challenges. Enhancing the design of the catheter to minimize backflow and improving the materials of the catheter to prevent scarring may increase the effectiveness of CED delivery. Catheter design, number of catheters, catheter location, infusion rate, start-up infusion protocol, infusion duration, type of drug infused, possible drug encapsulation and methods of evaluation for drug distribution are critical factors that need to be considered in the future. At present, CED is still a potent and promising treatment modality for GBM.

6. Local RT

RT is currently the primary method for controlling the growth of GBM. Since publication of the study by Stupp *et al* (1) in 2005, the dose of 60 Gy in 30 sessions has been delivered along with chemotherapy in the postoperative setting to the residual disease (when present) and the surgical bed with an adequate clinical margin (97). Unfortunately, even after RT, disease recurrence is inevitable, and in 70-80% of cases, it occurs within the treatment field (98). Several clinical trials have attempted to increase the dose of ionizing radiation in combination with TMZ using external beams RT (99). Nevertheless, the advantages in terms of survival have been marginal, while the adverse effects induced by radiation have significantly exacerbated.

To augment the dose directed at the tumor bed and mitigate harm to adjacent tissue, diverse BCT approaches have been explored, yielding differing levels of success (100). BCT and intraoperative RT (IORT) are the two main types of localized RT. BCT consists of placing a source of ionizing radiation into the surgical cavity, and IORT treats the surgical bed immediately after surgery using a dedicated linear accelerator. Both upfront and recurrent settings have been assessed in clinical trials. Nevertheless, to date, there are a limited number of published clinical studies, and most studies are retrospective and single-centered in design. In 2007, Chen *et al* (43) reported the results of a phase I study on 18 patients with GBM treated with BCT after the first surgical intervention (all patients had undergone radical resection). The median dose of ionizing radiation delivered through the placement of permanent iodine-125 (I-125) seeds at a depth of 0.5 cm was 400 Gy, followed by postoperative external beam RT. Despite PFS and OS results consistent with those reported by the aforementioned Stupp study, 11 patients underwent surgery for the development of radionecrosis (without evidence of disease progression). As a result of the high rate of toxicity, the trial was prematurely stopped. Similar results in terms of OS following BCT treatment at first diagnosis were also reported by Welsh *et al* (44). In addition, Fabrini *et al* (46) evaluated the viability and effectiveness of perioperative high-dose-rate BCT in 2009, administering an 18 Gy radiation at a 5 mm depth to 21 patients with recurrent GBM. The median OS time was 21.7 and 8 months from diagnosis and tumor recurrence, respectively. Chan *et al* (40) reported similar survival outcomes for 24 patients who received BCT at the time of the second surgical intervention, which likely indicates selection bias by the neurosurgeon affected the data. This was due to patient selection (ideal patients eligible for a second surgery

were selected), a prolonged time since the end of RT and a tumor recurrence that is easily resectable and preferably localized within the RT treatment fields. The study reported a median survival time of 23.3 months from diagnosis and 9.1 months from the date of recurrence.

In a study by Chino *et al* (45), the survival time of 26 patients treated with BCT after the second surgical intervention was 7.1 months. Gabayan *et al* (42) observed that patients who received BCT at the time of recurrence had a median survival time of 36.3 weeks from the date of BCT, which was consistent with earlier studies. In 2014, Kickingereder *et al* (101) reported a retrospective case series of patients with inoperable GBM treated with BCT at diagnosis and recurrence (103 patients treated at diagnosis and 98 at disease recurrence) between 1990 and 2012. A median dose of 60 Gy was administered through low-dose-rate stereotactic I-125 BCT. The treatment-related mortality was 0% and toxicities occurred in <7.5% of patients. It was found that patients treated with BCT at diagnosis and at recurrence had the same length of disease control (6.2 vs. 5.9 months, respectively; $P=0.11$). This result was likely affected by the patient selection (102,103). In 2015, Schwartz *et al* (48) published the results of a retrospective study on 68 patients with recurrent GBM who had been treated with I-125 BCT (the reference dose was 50.0 Gy, calculated to the boundary of the tumor). The median survival time was 41.8 months (95% CI, 29.2-55.9) and the perioperative morbidity was 2.9%. However, this study exhibited notable bias in patient selection, rendering the evaluation of OS data challenging.

Based on the available published studies, it can be concluded that BCT is likely safe, meriting further investigation in dedicated prospective clinical trials. However, the retrospective nature of currently published BCT studies, the variability in patient selection criteria, the prolonged enrollment periods resulting in heterogeneity according to various WHO classifications and the differing techniques and doses utilized present significant challenges to definitively determining the impact of this technique on patient survival. Future prospective studies are anticipated to provide critical insights.

Clinical experiences assessing the application of IORT in patients with GBM have revealed comparable limitations. In 2005, Schueller *et al* (41) reported the results of a retrospective study conducted on 71 patients with glioma treated with IORT. IORT demonstrated feasibility, with perioperative complication rates remaining unchanged. However, the survival outcomes generally did not exhibit improvement when compared with a historical control group. Disease recurrence exhibited similar survival rates as primary tumors, and GBM displayed a slightly elevated survival, suggesting potential indications for the use of IORT. Investigations by Usyckin *et al* (47) and Sarria *et al* (49) described findings indicating less favorable outcomes in terms of safety. The two studies assessed the viability of IORT in new and recurrent GBM. Radionecrosis occurred in 35 and 25.5% of patients in the respective studies. In addition, Usyckin *et al* (47) evaluated the impact of IORT in terms of survival and toxicity in a retrospective single-center study of 17 patients with GBM treated between 1992 and 2002. Each patient received high-dose IORT (20 Gy), followed by post-operative external beam RT. For the whole group, the median OS time was

13 months, consisting of 10.4 months for recurrent cases and 14 months for primary cases. Of the complications recorded, 3 patients presented with radionecrosis, 1 with osteomyelitis at the craniotomy bone flap, 1 with intracerebral hemorrhage and 1 with pulmonary embolism. In addition, 2 patients had a fatal outcome. Sarria *et al* (49) evaluated 51 patients with GBM. IORT was performed in a single session immediately after surgery (10-40 Gy prescribed at the applicator surface using low-energy photon) and was followed by standard radiochemotherapy treatment. Although no grade 4 radionecrosis was recorded, G1-G3 radionecrosis occurred in 25.4% of patients. At present, there is a lack of data supporting the use of IORT or BCT for diffuse glioma. Furthermore, the main clinical randomized trial investigating the efficacy of I-125 has failed to demonstrate a survival benefit (104).

The FDA clearance of GammaTile, incorporating Cs-131 titanium seeds within a resorbable collagen-based tile, has renewed the interest in BCT and introduced the concept of surgically targeted RT. Early clinical reports suggest a reasonable safety profile, but potential delayed seed settling during collagen absorption raises uncertainty about efficacy. Ongoing clinical trials are actively exploring the safety and efficacy of GammaTile for CNS tumors (105,106).

7. Local immunotherapy

Immunotherapy stands out as one of the extensively explored novel approaches for GBM treatment. The low immunogenicity of the tumor, along with an immunosuppressive TME, allows it to evade an immune response. For a number of reasons, including its low tumor mutational burden, low number of tumor-infiltrating T cells and low programmed cell death protein 1 (PD-1)/programmed death-ligand 1 expression, GBM is recognized as an immunologically inert tumor, particularly when compared with other cancer types that have responded favorably to immunotherapy. The high heterogeneity of GBM further facilitates immune evasion (7). In addition, although steroids are often essential for managing peritumoral edema, they can compromise the effectiveness of immunotherapies (7,107,108). Until now, several phase III clinical trials that focused on immune therapy for GBM have encountered difficulties, mainly related to individual components of the antitumor immune response. Learning from these setbacks, the potential success of immunotherapy for GBM appears most optimistic when utilizing a combination of immunotherapies to address the significant immunosuppression disease-related. It is thus crucial to detect reliable biomarkers both for appropriate patient selection and tumor evolution monitoring (9,10).

In this section, current findings and continuing clinical research in the field of immunotherapy for GBM will be discussed, which includes immune checkpoint inhibitors (ICIs), vaccines, chimeric antigen receptor T cell (CAR-T) treatment and viral therapy. In total, two different approaches of immunotherapy are described in literature: Passive immunotherapy (using antibodies and immune checkpoint modulators) and active immunotherapy (using tumor vaccination with viral vectors or dendritic cells and CAR-T treatments). A complete list of trials with clinical relevance using different immunotherapy strategies in the treatment of glioma are reported in Table III.

Viral therapy. Oncolytic viruses (OVs) selectively replicate in cancer cells and stimulate antitumor immunity, inducing immunogenic cell death (109). Studies have confirmed the efficacy and safety of OVs for the treatment of glioma; however, it is required to determine which OVs provide the most efficient treatment (adenovirus and herpes virus) (53,54,110). VB-11 is an adenovirus that directly disrupts the angiogenic vessels and induces a direct tumor immune response. Phase III trials have tested the efficacy of VB-11 with controversial results. A study by Brenner *et al* (110) demonstrated a significantly longer OS time (HR, 0.48; $P=0.043$) in patients primed with VB-111 in combination with bevacizumab. However, another phase III trial failed to demonstrate a benefit with this combination (OS time, 6.8 vs. 7.9 months; HR, 1.2; $P=0.19$) (53).

Oncolytic herpes simplex virus (HSV) is an attractive class of anticancer therapy due to a highly stable genome, potent cytolytic capability and effective drugs to treat adverse events. Westphal *et al* (54) demonstrated an improvement in median time to death (or re-intervention) with the perilesional injection of HSV-thymidine kinase followed by ganciclovir plus SOC. The survival time of the indicated treatment vs. SOC alone after tumor resection in newly diagnosed GBM was 308 vs. 268 days (HR, 1.53; $P=0.006$).

CAR-T cells. CARs are immunoglobulin T cell receptors that can activate T cells recognizing specific antigens, which have generated a recent particular interest due to favorable activity in hematologic malignancies (111). The most notable targets of these cells include EGFR, IL-13R2 and HER2; however, more recently discovered targets include mucin 1, CD147, GD2 and Eph receptor A2 (112). These cells appear to eliminate tumor cells with precision and demonstrate an increase in the immunogenicity of the GBM microenvironment (7). Encouraging data are also emerging in diffuse intrinsic pontine glioma. A study by Vitanza *et al* (113) demonstrated satisfactory tolerability to intraventricular infusion of B7-H3 CAR-T and 1 of the 3 patients with diffuse intrinsic pontine glioma enrolled had radiographic and clinical improvement through 12 months of the study. Further scientific details on this topic are discussed in greater depth in Chapter 8.

ICIs. ICIs target PD-1 or cytotoxic T-lymphocyte associate protein 4 (CTLA-4) to induce the immune response of T-cells. Although ICIs now represent the SOC in a number of cancer types with encouraging preclinical data (including in GBM), in a clinical context, ICIs do not improve the survival of patients with GBM (114,115). Different factors may limit immune cell trafficking, reducing the efficacy of suppressive TME. Although some encouraging data are emerging from the neoadjuvant phase investigations, these trials are still too immature and require a comparison arm. (116). Regarding intratumor activity, certain phase I/II clinical trials administering a combination of ICIs and CAR-T or OV make possible the application of ICIs in patients with glioma (52). Nassiri *et al* (52) in a multicenter phase 1/2 study, investigated the combination of intratumoral delivery of the OV, DNX-2401, followed by intravenous administration of anti-PD-1 antibody (pembrolizumab) in recurrent GBM. The authors demonstrated that the combination of DNX-2401

and pembrolizumab was safe and showed a notable survival benefit in selected patients. The OS rate at 12 months (52.7%; 95% CI, 40.1-69.2%), was significantly higher than the prespecified control rate of 20%. The median OS time was 12.5 months (10.7-13.5 months). Patients who achieved objective responses had a longer survival (HR, 0.20; 95% CI, 0.05-0.87). Additionally, 56.2% (95% CI, 41.1-70.5%) of patients experienced clinical benefits, defined as stable disease or better. Notably, 3 patients had durable responses and were alive at 45, 48 and 60 months.

8. Advances in CAR-T cell technology and beyond for HGG

Despite efforts in the genomic, transcriptomic, epigenetic and proteomic characterization of GBM specimens, little progress has been made in the survival of patients with GBM. The failure of treatments can be attributed to a number of GBM gene alterations, including mutations in KRAS, c-MET, PI3KCA, BRAF, telomerase reverse transcriptase, TP53 and PTEN, as well as the mutational status of the EGFR and platelet derived growth factor receptor α genes (7). Furthermore, the inability of tyrosine kinase inhibitors to cross the BBB reduces the efficacy of chemotherapy (116). Consequently, accurate tumor antigen targeting and effective intracranial drug delivery are essential for the success of GBM treatments (117). Comprehensive single-cell RNA-sequencing analysis of cancer stem cells, cells that remain in recurrent and resistant GBM inside the TME, may provide valuable data for future research on effective targeting strategies for this fatal illness (118). At present, several clinical trials are being conducted to treat GBM. These trials include vaccine therapy, immunotherapy and CAR-T cell therapy (119).

CAR-T cell technology envisages the production of T lymphocytes redirected to express a single-chain variable fragment (scFv) of an antibody to target and eliminate tumor cells that overexpress a specific tumor-associated antigen (TA) (120). CAR antigens that have been primarily targeted in patients with GBM include EGFR variant III (vIII), HER2, IL-13R α 2, B7-H3 and NKG2D (51,121-123). EGFRvIII CAR-T has been explored in several trials but has shown little OS benefit. Since CAR-T cell abundance in the blood is correlated with tumor regression, Suryadevara *et al* (124) have demonstrated that greater lymphodepletion induced by TMZ-dose intensified (TMZ-DI) is required to stimulate the proliferation and persistence of EGFRvIII CAR-T cells in a murine model. In light of this, a phase I clinical trial was established that involved individuals diagnosed with newly onset GBM, utilizing TMZ-DI as a preconditioning regimen preceding CAR-T cell immunotherapy (NCT02664363). According to Brown *et al* (51), intracranial infusion of IL-13R α 2 CAR-T cells initially demonstrated GBM regression but ultimately resulted in recurrence. In line with this, an ongoing phase I trial has been established to study the side effects and mechanism of IL-13R α 2 CAR-T cells when administered alone or in combination with the ICIs, nivolumab (anti-PD-1 mAb) and ipilimumab (anti-CTLA-4 mAb), in treating recurrent GBM cases (NCT04003649). As a result, CAR-T cell therapy for GBM will develop; however, several issues must be addressed, including TA heterogeneity, T-cell exhaustion, T-cell infiltration and the tumor immunosuppressive microenvironment.

Specifically, as demonstrated in the aforementioned studies, EGFRvIII CAR-T cell therapy led to a reduction in the number of EGFRvIII-expressing cells in patients with GBM. However, examination of post-infusion surgical resections demonstrated that, although EGFRvIII CAR-T cells effectively penetrated brain tumors, a high level of wild-type EGFR (wt EGFR) expression persisted in the residual tumor (51,123,124). To overcome this antigen heterogeneity, Choi *et al* (125) developed a sophisticated modified EGFRvIII CAR-T cells to produce a bispecific T-cell engager (BiTE) with the aim of targeting the residual EGFRvIII GBM cells in mice. BiTE was conceived to incorporate two scFvs, one directed against wt EGFR and the other to engage and activate T cells by binding CD3. BiTEs secreted by EGFRvIII CAR-T cells were also able to recruit local bystander T-cell effector activity. This platform may also apply to other tumor types that have demonstrated heterogeneous EGFRvIII expression, including medulloblastomas and breast and ovarian carcinoma.

To overcome the limited efficacy of CAR-T cells, multi-targeting CAR-T cells were also tested in preclinical GBM models. Novel CAR-T cells were developed to simultaneously target IL-13R α 2 and EphA2 or HER2 and IL-13R α 2 or EGFRvIII and IL-13R α 2 (126-128) and have shown additive T cell activation and antitumor activity. Trivalent CAR-T (IL-13R α 2, HER2 and EphA2) products were also developed. These CAR-T cells demonstrated a notably improved tumor clearance of autologous orthotopic glioma [patient-derived xenografts (PDXs)] compared with univalent and bivalent T-cell products (129). However, to the best of our knowledge, no first-in-human clinical trials of the latter proposed innovation have been listed on clinicaltrials.gov at present.

One of the cutting-edge therapeutic approaches to stimulate the immune system against solid tumors is the use of T-cell bispecific antibodies (TCB). TCBs are engineered to incorporate binding sites for CD3 ϵ of the T-cell receptor and a TA. For instance, EGFRvIII-TCB was developed against EGFRvIII, which is upregulated solely in GBM and is absent in healthy tissues (130). Peripheral infusion of EGFRvIII-TCB induced a strong antitumor activity in orthotopic humanized and PDX GBM models (130). The favorable preclinical data supported the use of this molecule in a first-in-human clinical trial (NCT05187624) in patients with newly diagnosed or recurrent GBM.

There are also currently ongoing clinical trials using the immune checkpoint inhibitor, lymphocyte activating 3 (LAG-3) mAb, alone or in combination regimens (NCT02658981 and NCT03493932). Unfortunately, immunotherapy using ICIs for the treatment of GBM still has drawbacks, such as high toxicity and poor efficacy (131).

The shortcomings in clinical outcomes underscore the imperative to pinpoint targets that can enhance the antitumor activity of CD8⁺ T-cells, suggesting that T-cell dysfunction may impact the GBM microenvironment. Ye *et al* (132) reported that the adoptive transfer of CD8⁺ T cells with protein disulfide isomerase family A member 3 (PDIA3), α -1,6-mannosylglycoprotein 6- β -N-acetylglucosaminyltransferase, epithelial membrane protein 1 or LAG-3 gene editing enhances the survival of GBM-bearing mice. In summary, it was shown that mutant human CD8⁺ T cells PDIA3⁻/EGFRvIII

CAR-T cells compared with wt EGFRvIII CAR-T cells enhanced killing of the GBM cell line, U87-EGFRvIII.

Although myeloid cell infiltration in the colorectal carcinoma (CRC) TME does not appear to be immunosuppressive, but instead is associated with a favorable clinical course of the disease (133,134), the presence of myeloid cells in the TME of GBM and most epithelial tumors, including renal cell carcinoma, is immunosuppressive (135,136).

Marked T cell dysfunction in GBM has also been demonstrated in two studies, which indicates why there is little antitumor immunity in GBM. Gangoso *et al* (136) demonstrated that GBM cells develop myeloid-like transcriptional and epigenetic programs in response to the immune microenvironment, which serves as a means of immune evasion. Another notable study by Ravi *et al* (137), explained the relationship between the release of the immunosuppressive cytokine, IL-10, from CD163⁺HMOX1⁺ myeloid cells in the GBM microenvironment and effector T-cell exhaustion and dysfunction. Ravi *et al* (137) discovered that chemically depleted myeloid cells caused T cells to produce more Granzyme B and less IL-10 and, based on these findings, the authors treated a patient with recurrent GBM with ruxolitinib, an inhibitor of the Janus kinase/STAT pathway, in a neoadjuvant setting in an effort to partially rescue the immunosuppressive environment. These studies provide insights into potential future therapeutic strategies that enhance T cell activation by decreasing immunosuppressive programs, beyond the use of CAR-T cell technology.

9. Conclusions

Multiple factors contribute to the poor prognosis of GBM and its resistance to current treatments, which include: i) The heterogeneity of GBM, which limits the options and efficacy of targeted therapies; ii) the pro-tumorigenic role of the TME, which activates resistance to radiation and chemotherapy in GBM; and iii) the low immunogenicity of GBM, which impedes a robust immunological response. In addition, the treatment for GBM incurs significant costs without providing an effective cure. Consequently, there is a pressing medical need for more effective treatments. To effectively address this lethal disease, future treatment approaches are needed that involve a combination of targeted local and systemic therapies, rather than relying on a single strategy.

Recurrences of GBM most typically occur within or near the resection cavity. Focusing therapeutic interventions directly on the tumor cavity has the potential of enhancing treatment effectiveness. Although LT for GBM has garnered attention, numerous innovative strategies are still in development. A combination of different approaches, such as dual targeting, should be considered. The exploration of post-operative implants holds particular appeal when compared with conventional chemotherapies for four reasons: i) LT allows the start of bridging therapy between surgery and conventional standard treatments; ii) LT implants offer the advantage of circumventing the BBB, allowing consideration of various chemotherapeutic agents and establishing a reservoir of active molecules in close proximity to the pathology; iii) the localized administration of active molecules results in limited systemic toxicity; and iii) given the complexity of GBM and

the potential for multi-targeting, employing ligands specific to various components of the TME could yield a synergistic effect in treatments. This innovative approach could revolutionize GBM treatment, offering new hope to patients and medical professionals alike.

Before the WHO 2021 classification, all investigations regarding LT and GBM were partially representative, adding bias and reducing the generalizability of results in the context of subsequent molecular discoveries. Prior classifications did not include extensive molecular and genetic profiling that currently separates a number of GBM subtypes. This oversight could mean that the patients or data selected for downstream analysis did not fairly represent the range of GBM cases, potentially distorting study findings. To ensure more accurate and inclusive research, it is beneficial and essential to reinterpret historical data in light of the new classification and define future prospective studies in this challenging clinical setting.

Acknowledgements

Not applicable.

Funding

No funding was received.

Availability of data and materials

Not applicable.

Authors' contributions

Conceptualization was conducted by TI, TS, FP, MCaf and GL; methodology was conducted by TI, JB and FV; formal analysis and data interpretation were conducted by TI, TS, FP, JB, FV, MCac, EC, CC, GP, GS, MZ, CG, MCaf and GL; literature analysis was conducted by TI, TS, FP, JB, FV, MCac, EC, CC, GS, MZ, CG, MCaf and GL; writing of the original draft was conducted by TI, TS, FP, JB, FV, MCac, EC, CC, GP, GS, MZ, CG, MCaf and GL; reviewing and editing of the manuscript was conducted by TI, TS, FP, CC, MZ, MCaf and GL; visualization was conducted by TI, TS, FP, JB, FV, MCac, EC, CC, GP, GS, MZ, CG, MCaf and GL; supervision was conducted by TI, TS, FP, CC, MZ, MCaf and GL; project administration was conducted by TI, GP and CC. All authors read and approved the final version of the manuscript. Data authentication is not applicable.

Ethics approval and consent to participate

Not applicable.

Patient consent for publication

Not applicable.

Competing interests

The authors declare that they have no competing interests.

References

1. Stupp R, Mason WP, van den Bent MJ, Weller M, Fisher B, Taphoorn MJ, Belanger K, Brandes AA, Marosi C, Bogdahn U, *et al*: Radiotherapy plus concomitant and adjuvant temozolomide for glioblastoma. *N Engl J Med* 352: 987-996, 2005.
2. Weller M, van den Bent M, Preusser M, Le Rhun E, Tonn JC, Minniti G, Bendszus M, Balana C, Chinot O, Dirven L, *et al*: EANO guidelines on the diagnosis and treatment of diffuse gliomas of adulthood. *Nat Rev Clin Oncol* 18: 170-186, 2021.
3. Ius T, Sabatino G, Panciani PP, Fontanella MM, Rudà R, Castellano A, Barbagallo GMV, Belotti F, Boccaletti R, Catapano G, *et al*: Surgical management of Glioma Grade 4: technical update from the neuro-oncology section of the Italian Society of Neurosurgery (SINch®): A systematic review. *J Neurooncol* 162: 267-293, 2023.
4. Zhu P, Du XL, Lu G and Zhu JJ: Survival benefit of glioblastoma patients after FDA approval of temozolomide concomitant with radiation and bevacizumab: A population-based study. *Oncotarget* 8: 44015-44031, 2017.
5. Pombo Antunes AR, Scheyltjens I, Duerinck J, Neyns B, Movahedi K and Van Ginderachter JA: Understanding the glioblastoma immune microenvironment as basis for the development of new immunotherapeutic strategies. *Elife* 9: e52176, 2020.
6. Menna G, Manini I, Cesselli D, Skrap M, Olivi A, Ius T and Della Pepa GM: Immunoregulatory effects of glioma-associated stem cells on the glioblastoma peritumoral microenvironment: A differential PD-L1 expression from core to periphery? *Neurosurg Focus* 52: E4, 2022.
7. Agosti E, Panciani PP, Zeppieri M, De Maria L, Pasqualetti F, Tel A, Zanin L, Fontanella MM and Ius T: Tumor microenvironment and glioblastoma cell interplay as promoters of therapeutic resistance. *Biology (Basel)* 12: 736, 2023.
8. Brandes AA, Tosoni A, Franceschi E, Sotti G, Frezza G, Amistà P, Morandi L, Spagnolli F and Ermani M: Recurrence pattern after temozolomide concomitant with and adjuvant to radiotherapy in newly diagnosed patients with glioblastoma: Correlation With MGMT promoter methylation status. *J Clin Oncol* 27: 1275-1279, 2009.
9. van Solinge TS, Nieland L, Chiocca EA and Broekman MLD: Advances in local therapy for glioblastoma-taking the fight to the tumour. *Nat Rev Neurol* 18: 221-236, 2022.
10. Young JS, Morshed RA, Hervey-Jumper SL and Berger MS: The surgical management of diffuse gliomas: Current state of neurosurgical management and future directions. *Neuro Oncol* 25: 2117-2133, 2023.
11. Reulen HJ, Suero Molina E, Zeidler R, Gildehaus FJ, Böning G, Gosewisch A and Stummer W: Intracavitary radioimmunotherapy of high-grade gliomas: Present status and future developments. *Acta Neurochir (Wien)* 161: 1109-1124, 2019.
12. Louis DN, Perry A, Wesseling P, Brat DJ, Cree IA, Figarella-Branger D, Hawkins C, Ng HK, Pfister SM, Reifenberger G, *et al*: The 2021 WHO Classification of Tumors of the Central Nervous System: A summary. *Neuro Oncol* 23: 1231-1251, 2021.
13. Page MJ, McKenzie JE, Bossuyt PM, Boutron I, Hoffmann TC, Mulrow CD, Shamseer L, Tetzlaff JM, Akl EA, Brennan SE, *et al*: The PRISMA 2020 statement: An updated guideline for reporting systematic reviews. *BMJ* 372: n71, 2021.
14. Stang A: Critical evaluation of the Newcastle-Ottawa scale for the assessment of the quality of nonrandomized studies in meta-analyses. *Eur J Epidemiol* 25: 603-605, 2010.
15. Mohammadi AM, Hawasli AH, Rodriguez A, Schroeder JL, Laxton AW, Elson P, Tatter SB, Barnett GH and Leuthardt EC: The role of laser interstitial thermal therapy in enhancing progression-free survival of difficult-to-access high-grade gliomas: A multicenter study. *Cancer Med* 3: 971-979, 2014.
16. Thomas JG, Rao G, Kew Y and Prabhu SS: Laser interstitial thermal therapy for newly diagnosed and recurrent glioblastoma. *Neurosurg Focus* 41: E12, 2016.
17. Beaumont TL, Mohammadi AM, Kim AH, Barnett GH and Leuthardt EC: magnetic resonance imaging-guided laser interstitial thermal therapy for glioblastoma of the corpus callosum. *Neurosurgery* 83: 556-565, 2018.
18. Kamath AA, Friedman DD, Akbari SHA, Kim AH, Tao Y, Luo J and Leuthardt EC: Glioblastoma treated with magnetic resonance imaging-guided laser interstitial thermal therapy: Safety, efficacy, and outcomes. *Neurosurgery* 84: 836-843, 2019.

19. O'Connor KP, Palejwala AH, Milton CK, Lu VM, Glenn CA, Sughrue ME and Conner AK: Laser interstitial thermal therapy case series: Choosing the correct number of fibers depending on lesion size. *Oper Neurosurg (Hagerstown)* 20: 18-23, 2020.
20. Traylor JI, Patel R, Muir M, de Almeida Bastos DC, Ravikumar V, Kamiya-Matsuoka C, Rao G, Thomas JG, Kew Y and Prabhu SS: Laser interstitial thermal therapy for glioblastoma: A single-center experience. *World Neurosurg* 149: e244-e252, 2021.
21. de Groot JF, Kim AH, Prabhu S, Rao G, Laxton AW, Fecci PE, O'Brien BJ, Sloan A, Chiang V, Tatter SB, *et al*: Efficacy of laser interstitial thermal therapy (LITT) for newly diagnosed and recurrent IDH wild-type glioblastoma. *Neurooncol Adv* 4: vdac040, 2022.
22. Johnson GW, Han RH, Smyth MD, Leuthardt EC and Kim AH: Laser interstitial thermal therapy in grade 2/3 IDH1/2 Mutant Gliomas: A preliminary report and literature review. *Curr Oncol* 29: 2550-2563, 2022.
23. Muir M, Patel R, Traylor JI, de Almeida Bastos DC, Kamiya C, Li J, Rao G and Prabhu SS: Laser interstitial thermal therapy for newly diagnosed glioblastoma. *Lasers Med Sci* 37: 1811-1820, 2022.
24. Kaisman-Elbaz T, Xiao T, Grabowski MM, Barnett GH and Mohammadi AM: The impact of extent of ablation on survival of patients with newly diagnosed glioblastoma treated with laser interstitial thermal therapy: A large single-institutional cohort. *Neurosurgery* 93: 427-435, 2023.
25. Jubran JH, Scherschinski L, Dholaria N, Shaftel KA, Farhadi DS, Oladokun FC, Hendricks BK and Smith KA: Magnetic resonance-guided laser interstitial thermal therapy for recurrent glioblastoma and radiation necrosis: A single-surgeon case series. *World Neurosurg* 182: e453-e462, 2024.
26. Guthkelch AN, Carter LP, Cassady JR, Hynynen KH, Iacono RP, Johnson PC, Obbens EA, Roemer RB, Seeger JF, Shimm DS, *et al*: Treatment of malignant brain tumors with focused ultrasound hyperthermia and radiation: Results of a phase I trial. *J Neurooncol* 10: 271-284, 1991.
27. Carpentier A, Canney M, Vignot A, Reina V, Beccaria K, Horodyckid C, Karachi C, Leclercq D, Lafon C, Chapelon JY, *et al*: Clinical trial of blood-brain barrier disruption by pulsed ultrasound. *Sci Transl Med* 8: 343re2, 2016.
28. Stea B, Rossman K, Kittelson J, Shetter A, Hamilton A and Cassady JR: Interstitial irradiation versus interstitial thermos radiotherapy for supratentorial malignant gliomas: A comparative survival analysis. *Int J Radiat Oncol Biol Phys* 30: 591-600, 1994.
29. Maier-Hauff K, Ulrich F, Nestler D, Niehoff H, Wust P, Thiesen B, Orawa H, Budach V and Jordan A: Efficacy and safety of intratumoral thermotherapy using magnetic iron-oxide nanoparticles combined with external beam radiotherapy on patients with recurrent glioblastoma multiforme. *J Neurooncol* 103: 317-324, 2011.
30. Stupp R, Wong ET, Kanner AA, Steinberg D, Engelhard H, Heidecke V, Kirson ED, Taillibert S, Liebermann F, Dbalý V, *et al*: NovoTTF-100A versus physician's choice chemotherapy in recurrent glioblastoma: A randomized phase III trial of a novel treatment modality. *Eur J Cancer* 48: 2192-2202, 2012.
31. Stupp R, Taillibert S, Kanner AA, Kesari S, Steinberg DM, Toms SA, Taylor LP, Lieberman F, Silvani A, Fink KL, *et al*: Maintenance therapy with tumor-treating fields plus temozolomide vs temozolomide alone for glioblastoma: A Randomized clinical trial. *JAMA* 314: 2535-2543, 2015.
32. Vinjamuri M, Adumala RR, Alaha R, Hobbs GR and Crowell EB Jr: Comparative analysis of temozolomide (TMZ) versus 1,3-bis (2-chloroethyl)-1 nitrosourea (BCNU) in newly diagnosed glioblastoma multiforme (GBM) patients. *J Neurooncol* 91: 221-225, 2009.
33. De Bonis P, Anile C, Pompucci A, Fiorentino A, Balducci M, Chiesa S, Maira G and Mangiola A: Safety and efficacy of Gliadel wafers for newly diagnosed and recurrent glioblastoma. *Acta Neurochir (Wien)* 154: 1371-1378, 2012.
34. Catalán-Uribarrena G, Bilbao-Barandica G, Pomposo-Gaztelu I, Undabeitia-Huertas J, Ruiz de Gopegui-Ruiz E, Galbarriatu-Gutiérrez L, Canales-Llantada M, Aurrecochea-Obieta J, Igartua-Azkune A and Carbayo-Lozano G: Prognostic factors and survival in a prospective cohort of patients with high-grade glioma treated with carmustine wafers or temozolomide on an intention-to-treat basis. *Acta Neurochir (Wien)* 154: 211-222; discussion 222, 2012.
35. Noël G, Schott R, Froelich S, Gaub MP, Boyer P, Fischer-Lokou D, Dufour P, Kehrli P and Maitrot D: Retrospective comparison of chemoradiotherapy followed by adjuvant chemotherapy, with or without prior gliadel implantation (carmustine) after initial surgery in patients with newly diagnosed high-grade gliomas. *Int J Radiat Oncol Biol Phys* 82: 749-755, 2012.
36. Pallud J, Audureau E, Noel G, Corns R, Lechapt-Zalcman E, Duntze J, Pavlov V, Guyotat J, Hieu PD, Le Reste PJ, *et al*: Long-term results of carmustine wafer implantation for newly diagnosed glioblastomas: A controlled propensity-matched analysis of a French multicenter cohort. *Neuro Oncol* 17: 1609-1619, 2015.
37. Roux A, Peeters S, Zanella M, Bou Nassif R, Abi Lahoud G, Dezamis E, Parraga E, Lechapt-Zalcmann E, Dhermain F, Dumont S, *et al*: Extent of resection and Carmustine wafer implantation safely improve survival in patients with a newly diagnosed glioblastoma: A single center experience of the current practice. *J Neurooncol* 135: 83-92, 2017.
38. Akiyama Y, Kimura Y, Enatsu R, Mikami T, Wanibuchi M and Mikuni N: Advantages and disadvantages of combined chemotherapy with carmustine wafer and bevacizumab in patients with newly diagnosed glioblastoma: A single-institutional experience. *World Neurosurg* 113: e508-e514, 2018.
39. Bos EM, Binda E, Verploegh ISC, Wembacher E, Hoefnagel D, Balvers RK, Korporaal AL, Conidi A, Warnert EAH, Trivieri N, *et al*: Local delivery of hrBMP4 as an anticancer therapy in patients with recurrent glioblastoma: A first-in-human phase 1 dose escalation trial. *Mol Cancer* 22: 129, 2023.
40. Chan TA, Weingart JD, Parisi M, Hughes MA, Olivi A, Borzillary S, Alahakone D, Detorie NA, Wharam MD and Kleinberg L: Treatment of recurrent glioblastoma multiforme with GliaSite brachytherapy. *Int J Radiat Oncol Biol Phys* 62: 1133-1139, 2005.
41. Schueller P, Micke O, Palkovic S, Schroeder J, Moustakis C, Bruns F, Schuck A, Wassmann H and Willich N: 12 years' experience with intraoperative radiotherapy (IORT) of malignant gliomas. *Strahlenther Onkol* 181: 500-506, 2005.
42. Gabayan AJ, Green SB, Sanan A, Jenrette J, Schultz C, Papagikos M, Tatter SP, Patel A, Amin P, Lustig R, *et al*: GliaSite brachytherapy for treatment of recurrent malignant gliomas: A retrospective multi-institutional analysis. *Neurosurgery* 58: 701-9; discussion 701-709, 2006.
43. Chen AM, Chang S, Pouliot J, Sneed PK, Prados MD, Lamborn KR, Malec MK, McDermott MW, Berger MS and Larson DA: Phase I trial of gross total resection, permanent iodine-125 brachytherapy, and hyperfractionated radiotherapy for newly diagnosed glioblastoma multiforme. *Int J Radiat Oncol Biol Phys* 69: 825-830, 2007.
44. Welsh J, Sanan A, Gabayan AJ, Green SB, Lustig R, Burri S, Kwong E and Stea B: GliaSite brachytherapy boost as part of initial treatment of glioblastoma multiforme: A retrospective multi-institutional pilot study. *Int J Radiat Oncol Biol Phys* 68: 159-165, 2007.
45. Chino K, Silvain D, Grace A, Stubbs J and Stea B: Feasibility and safety of outpatient brachytherapy in 37 patients with brain tumors using the GliaSite Radiation Therapy System. *Med Phys* 35: 3383-3388, 2008.
46. Fabrini MG, Perrone F, De Franco L, Pasqualetti F, Grespi S, Vannozzi R and Cionini L: Perioperative high-dose-rate brachytherapy in the treatment of recurrent malignant gliomas. *Strahlenther Onkol* 185: 524-529, 2009.
47. Usyckin S, Calvo F, dos Santos MA, Samblás J, de Urbina DO, Bustos JC, Diaz JA, Sallabanda K, Sanz A, Yélamos C, *et al*: Intra-operative electron beam radiotherapy for newly diagnosed and recurrent malignant gliomas: Feasibility and long-term outcomes. *Clin Transl Oncol* 15: 33-38, 2013.
48. Schwartz C, Romagna A, Thon N, Niyazi M, Watson J, Belka C, Tonn JC, Kreth FW and Nachbichler SB: Outcome and toxicity profile of salvage low-dose-rate iodine-125 stereotactic brachytherapy in recurrent high-grade gliomas. *Acta Neurochir (Wien)* 157: 1757-1764; discussion 1764, 2015.
49. Sarria GR, Sperk E, Han X, Sarria GJ, Wenz F, Brehmer S, Fu B, Min S, Zhang H, Qin S, *et al*: Intraoperative radiotherapy for glioblastoma: An international pooled analysis. *Radiother Oncol* 142: 162-167, 2020.
50. Keu KV, Witney TH, Yaghoubi S, Rosenberg J, Kurien A, Magnusson R, Williams J, Habte F, Wagner JR, Forman S, *et al*: Reporter gene imaging of targeted T cell immunotherapy in recurrent glioma. *Sci Transl Med*. 9: eaag2196, 2017.
51. Brown CE, Alizadeh D, Starr R, Weng L, Wagner JR, Naranjo A, Ostberg JR, Blanchard MS, Kilpatrick J, Simpson J, *et al*: Regression of glioblastoma after chimeric antigen receptor T-cell therapy. *N Engl J Med* 375: 2561-2569, 2016.
52. Nassiri F, Patil V, Yefet LS, Singh O, Liu J, Dang RMA, Yamaguchi TN, Daras M, Cloughesy TF, Colman H, *et al*: Oncolytic DNX-2401 virotherapy plus pembrolizumab in recurrent glioblastoma: A phase 1/2 trial. *Nat Med* 29: 1370-1378, 2023.

53. Cloughesy TF, Brenner A, de Groot JF, Butowski NA, Zach L, Campian JL, Ellingson BM, Freedman LS, Cohen YC, Lowenton-Spier N, *et al*: A randomized controlled phase III study of VB-111 combined with bevacizumab vs bevacizumab monotherapy in patients with recurrent glioblastoma [GLOBE]. *Neuro Oncol* 22: 705-717, 2020.
54. Westphal M, Ylä-Herttuala S, Martin J, Warnke P, Menei P, Eckland D, Kinley J, Kay R and Ram Z; ASPECT Study Group: Adenovirus-mediated gene therapy with sitimagene ceradenovec followed by intravenous ganciclovir for patients with operable high-grade glioma [ASPECT]: A randomised, open-label, phase 3 trial. *Lancet Oncol* 14: 823-833, 2013.
55. Desjardins A, Gromeier M, Herndon JE II, Beaubier N, Bolognesi DP, Friedman AH, Friedman HS, McSherry F, Muscat AM, Nair S, *et al*: Recurrent glioblastoma treated with recombinant poliovirus. *N Engl J Med* 379: 150-161, 2018.
56. Caffo M, Caruso G, Curcio A, Laera R, Crisafulli C, Passalacqua M and Germanò A: The Role of Nanotechnology in Brain Tumors. In: *Human Brain and Spinal Cord Tumors: From Bench to Bedside*. Vol 1. Springer International Publishing, pp193-207, 2022.
57. Langen UH, Ayloo S and Gu C: Development and cell biology of the blood-brain barrier. *Annu Rev Cell Dev Biol* 35: 591-613, 2019.
58. Patel B, Yang PH and Kim AH: The effect of thermal therapy on the blood-brain barrier and blood-tumor barrier. *Int J Hyperthermia* 37: 35-43, 2020.
59. Holste KG and Orringer DA: Laser interstitial thermal therapy. *Neurooncol Adv* 2: vdz035, 2019.
60. Mohammadi AM, Sharma M, Beaumont TL, Juarez KO, Kemeny H, Dechant C, Seas A, Sarmey N, Lee BS, Jia X, *et al*: Upfront magnetic resonance imaging-guided stereotactic laser-ablation in newly diagnosed glioblastoma: A multicenter review of survival outcomes compared to a matched cohort of biopsy-only patients. *Neurosurgery* 85: 762-772, 2019.
61. Fadel HA, Haider S, Pawloski JA, Zakaria HM, Macki M, Bartlett S, Schultz L, Robin AM, Kalkanis SN and Lee IY: Laser Interstitial thermal therapy for first-line treatment of surgically accessible recurrent glioblastoma: Outcomes compared with a surgical cohort. *Neurosurgery* 91: 701-709, 2022.
62. Quadri SA, Waqas M, Khan I, Khan MA, Suriya SS, Farooqui M and Fiani B: High-intensity focused ultrasound: past, present, and future in neurosurgery. *Neurosurg Focus* 44: E16, 2018.
63. Mauri G, Nicosia L, Xu Z, Di Pietro S, Monfardini L, Bonomo G, Varano GM, Prada F, Della Vigna P and Orsi F: Focused ultrasound: Tumour ablation and its potential to enhance immunological therapy to cancer. *Br J Radiol* 91: 20170641, 2018.
64. Hu S, Zhang X, Unger M, Patties I, Melzer A and Landgraf L: Focused ultrasound-induced cavitation sensitizes cancer cells to radiation therapy and hyperthermia. *Cells* 9: 2595, 2020.
65. Hersh AM, Bhimreddy M, Weber-Levine C, Jiang K, Alomari S, Theodore N, Manbachi A and Tyler BM: Applications of focused ultrasound for the treatment of glioblastoma: A new frontier. *Cancers (Basel)* 14: 4920, 2022.
66. Elhelf IAS, Albahar H, Shah U, Oto A, Cressman E and Almekkawy M: High intensity focused ultrasound: The fundamentals, clinical applications and research trends. *Diagn Interv Imaging* 99: 349-359, 2018.
67. Fomenko A and Lozano AM: Neuromodulation and ablation with focused ultrasound-toward the future of noninvasive brain therapy. *Neural Regen Res* 14: 1509-1510, 2019.
68. Cohen-Inbar O, Xu Z and Sheehan JP: Focused ultrasound-aided immunomodulation in glioblastoma multiforme: A therapeutic concept. *J Ther Ultrasound* 4: 2, 2016.
69. Cazares-Cortes E, Cabana S, Boitard C, Nehlig E, Griffete N, Fresnais J, Wilhelm C, Abou-Hassan A and Ménager C: Recent insights in magnetic hyperthermia: From the 'hot-spot' effect for local delivery to combined magneto-photo-thermia using magneto-plasmonic hybrids. *Adv Drug Deliv Rev* 138: 233-246, 2019.
70. Grauer O, Jaber M, Hess K, Weckesser M, Schwindt W, Maring S, Wölfer J and Stummer W: Combined intracavitary thermotherapy with iron oxide nanoparticles and radiotherapy as local treatment modality in recurrent glioblastoma patients. *J Neurooncol* 141: 83-94, 2019.
71. Toraya-Brown S, Sheen MR, Zhang P, Chen L, Baird JR, Demidenko E, Turk MJ, Hoopes PJ, Conejo-Garcia JR and Fiering S: Local hyperthermia treatment of tumors induces CD8(+) T cell-mediated resistance against distal and secondary tumors. *Nanomedicine* 10: 1273-1285, 2014.
72. Ito A, Tanaka K, Kondo K, Shinkai M, Honda H, Matsumoto K, Saida T and Kobayashi T: Tumor regression by combined immunotherapy and hyperthermia using magnetic nanoparticles in an experimental subcutaneous murine melanoma. *Cancer Sci* 94: 308-313, 2003.
73. Gilchrist RK, Medal R, Shorey WD, Hanselman RC, Parrott JC and Taylor CB: Selective inductive heating of lymph nodes. *Ann Surg* 146: 596-606, 1957.
74. Stea B, Cetas TC, Cassady JR, Guthkelch AN, Iacono R, Lulu B, Lutz W, Obbens E, Rossman K, Seeger J, *et al*: Interstitial thermoradiotherapy of brain tumors: Preliminary results of a phase I clinical trial. *Int J Radiat Oncol Biol Phys* 19: 1463-1471, 1990.
75. Fabian D, Guillermo Prieto Eibl MDP, Alnahhas I, Sebastian N, Giglio P, Puduvalli V, Gonzalez J and Palmer JD: Treatment of Glioblastoma (GBM) with the Addition of Tumor-Treating Fields (TTF): A Review. *Cancers (Basel)* 11: 174, 2019.
76. Shah PP, White T, Khalafallah AM, Romo CG, Price C and Mukherjee D: A systematic review of tumor treating fields therapy for high-grade gliomas. *J Neurooncol* 148: 433-443, 2020.
77. Ballo MT, Conlon P, Lavy-Shahaf G, Kinzel A, Vymazal J and Rulseh AM: Association of Tumor Treating Fields (TTFields) therapy with survival in newly diagnosed glioblastoma: A systematic review and meta-analysis. *J Neurooncol* 164: 1-9, 2023.
78. Joo H, Lee Y, Kim J, Yoo JS, Yoo S, Kim S, Arya AK, Kim S, Choi SH, Lu N, *et al*: Soft implantable drug delivery device integrated wirelessly with wearable devices to treat fatal seizures. *Sci Adv* 7: eabd4639, 2021.
79. Bobo RH, Laske DW, Akbasak A, Morrison PF, Dedrick RL and Oldfield EH: Convection-enhanced delivery of macromolecules in the brain. *Proc Natl Acad Sci USA* 91: 2076-2080, 1994.
80. Cha GD, Kang T, Baik S, Kim D, Choi SH, Hyeon T and Kim DH: Advances in drug delivery technology for the treatment of glioblastoma multiforme. *J Control Release* 328: 350-367, 2020.
81. Haar PJ, Chen ZJ, Fatouros PP, Gillies GT, Corwin FD and Broaddus WC: Modelling convection-enhanced delivery in normal and oedematous brain. *J Med Eng Technol* 38: 76-84, 2014.
82. White E, Bienemann A, Malone J, Megraw L, Bunnun C, Wyatt M and Gill S: An evaluation of the relationships between catheter design and tissue mechanics in achieving high-flow convection-enhanced delivery. *J Neurosci Methods* 199: 87-97, 2011.
83. Chew SA and Danti S: Biomaterial-Based implantable devices for cancer therapy. *Adv Healthc Mater* 6: 1600766, 2017.
84. Bow H, Hwang LS, Schildhaus N, Xing J, Murray L, Salditch Q, Ye X, Zhang Y, Weingart J, Brem H and Tyler B: Local delivery of angiogenesis-inhibitor minocycline combined with radiotherapy and oral temozolomide chemotherapy in 9L glioma. *J Neurosurg* 120: 662-669, 2014.
85. Bersini S, Jeon JS, Dubini G, Arrigoni C, Chung S, Charest JL, Moretti M and Kamm RD: A microfluidic 3D in vitro model for specificity of breast cancer metastasis to bone. *Biomaterials* 35: 2454-2461, 2014.
86. Liao J, Guo X, Grande-Allen KJ, Kasper FK and Mikos AG: Bioactive polymer/extracellular matrix scaffolds fabricated with a flow perfusion bioreactor for cartilage tissue engineering. *Biomaterials* 31: 8911-8920, 2010.
87. Yang Y, Hu X, Liu Y, Ouyang B, Zhang J, Jin H, Yu Z, Liu R, Li Z, Jiang L, *et al*: An implantable ultrasound-powered device for the treatment of brain cancer using electromagnetic fields. *Sci Adv* 8: eabm5023, 2022.
88. Xie J and Wang CH: Electrospun micro- and nanofibers for sustained delivery of paclitaxel to treat C6 glioma in vitro. *Pharm Res* 23: 1817-1826, 2006.
89. Benoit MA, Ribet C, Distexhe J, Hermand D, Letesson JJ, Vandehaute J and Gillard J: Studies on the potential of microparticles entrapping pDNA-poly(aminoacids) complexes as vaccine delivery systems. *J Drug Target* 9: 253-266, 2001.
90. Ius T, Cesselli D, Isola M, Toniato G, Pualetto G, Sciacca G, Fabbro S, Pegolo E, Rizzato S, Beltrami AP, *et al*: Combining clinical and molecular data to predict the benefits of carmustine wafers in newly diagnosed high-grade gliomas. *Curr Treat Options Neurol* 20: 3, 2018.
91. Ricciardi L, Manini I, Cesselli D, Trungu S, Piazza A, Mangraviti A, Miscusi M, Raco A and Ius T: Carmustine wafers implantation in patients with newly diagnosed high grade glioma: Is It still an option? *Front Neurol* 13: 884158, 2022.
92. Wen PY, Weller M, Lee EQ, Alexander BM, Barnholtz-Sloan JS, Barthel FP, Batchelor TT, Bindra RS, Chang SM, Chiocca EA, *et al*: Glioblastoma in adults: A Society for Neuro-Oncology (SNO) and European Society of Neuro-Oncology (EANO) consensus review on current management and future directions. *Neuro Oncol* 22: 1073-1113, 2020.

93. Iuchi T, Inoue A, Hirose Y, Morioka M, Horiguchi K, Natsume A, Arakawa Y, Iwasaki K, Fujiki M, Kumabe T and Sakata Y: Long-term effectiveness of Gliadel implant for malignant glioma and prognostic factors for survival: 3-year results of a postmarketing surveillance in Japan. *Neurooncol Adv* 4: vdab189, 2022.
94. Champeaux C and Weller J: Implantation of carmustine wafers (Gliadel®) for high-grade glioma treatment. A 9-year nationwide retrospective study. *J Neurooncol* 147: 159-169, 2020.
95. Wu Q and Yao J: BMP4, a new prognostic factor for glioma. *World J Surg Oncol* 11: 264, 2013.
96. Yang DY, Bu XY, Zhou ZL, Yan ZY, Ma CX, Qu MQ, Zhao YW, Kong LF, Wang YW and Luo JC: Enhanced antitumor effects of radiotherapy combined local nimustine delivery rendezvousing with oral temozolomide chemotherapy in glioblastoma patients. *J Cancer Res Ther* 14: 78-83, 2018.
97. Niyazi M, Andratschke N, Bendszus M, Chalmers AJ, Erridge SC, Galldiks N, Lagerwaard FJ, Navarra P, Munck Af Rosenschöld P, Ricardi U, *et al*: ESTRO-EANO guideline on target delineation and radiotherapy details for glioblastoma. *Radiother Oncol* 184: 109663, 2023.
98. Tu Z, Xiong H, Qiu Y, Li G, Wang L and Peng S: Limited recurrence distance of glioblastoma under modern radiotherapy era. *BMC Cancer* 21: 720, 2021.
99. Singh R, Lehrer EJ, Wang M, Perlow HK, Zaorsky NG, Trifiletti DM, Bovi J, Navarra P, Scocianti S, Gondi V, *et al*: Dose Escalated Radiation Therapy for Glioblastoma Multiforme: An International Systematic Review and Meta-Analysis of 22 Prospective Trials. *Int J Radiat Oncol Biol Phys* 111: 371-384, 2021.
100. Barbarite E, Sick JT, Berchmans E, Bregy A, Shah AH, Elsayyad N and Komotar RJ: The role of brachytherapy in the treatment of glioblastoma multiforme. *Neurosurg Rev* 40: 195-211, 2017.
101. Kickingreder P, Hamisch C, Suchorska B, Galldiks N, Visser-Vandewalle V, Goldbrunner R, Kocher M, Treuer H, Voges J and Ruge MI: Low-dose rate stereotactic iodine-125 brachytherapy for the treatment of inoperable primary and recurrent glioblastoma: Single-center experience with 201 cases. *J Neurooncol* 120: 615-623, 2014.
102. Pasqualetti F, Barberis A, Zanotti S, Montemurro N, De Salvo GL, Soffiatti R, Mazzanti CM, Ius T, Caffo M, Paia F, *et al*: The impact of survivorship bias in glioblastoma research. *Crit Rev Oncol Hematol* 188: 104065, 2023.
103. Pasqualetti F, Montemurro N, Desideri I, Loi M, Giannini N, Gadducci G, Malfatti G, Cantarella M, Gonnelli A, Montrone S, *et al*: Impact of recurrence pattern in patients undergoing a second surgery for recurrent glioblastoma. *Acta Neurol Belg* 122: 441-446, 2022.
104. Laperriere NJ, Leung PM, McKenzie S, Milosevic M, Wong S, Sher X, Pintilie M and Bernstein M: Randomized study of brachytherapy in the initial management of patients with malignant astrocytoma. *Int J Radiat Oncol Biol Phys* 41: 1005-1011, 1998.
105. Odia Y, Gutierrez AN and Kotecha R: Surgically targeted radiation therapy (STaRT) trials for brain neoplasms: A comprehensive review. *Neuro Oncol* 24 (Suppl 6): S16-S24, 2022.
106. Gessler DJ, Neil EC, Shah R, Levine J, Shanks J, Wilke C, Reynolds M, Zhang S, Özütemiz C, Gencturk M, *et al*: GammaTile® brachytherapy in the treatment of recurrent glioblastomas. *Neurooncol Adv* 4: vdab185, 2021.
107. Cristescu R, Mogg R, Ayers M, Albright A, Murphy E, Yearley J, Sher X, Liu XQ, Lu H, Nebozhyn M, *et al*: Pan-tumor genomic biomarkers for PD-1 checkpoint blockade-based immunotherapy. *Science* 362: eaar3593, 2018.
108. Thorsson V, Gibbs DL, Brown SD, Wolf D, Bortone DS, Ou Yang TH, Porta-Pardo E, Gao GF, Plaisier CL, Eddy JA, *et al*: The Immune Landscape of Cancer. *Immunity* 48: 812-830.e14, 2018.
109. Alayo QA, Ito H, Passaro C, Zdioruk M, Mahmoud AB, Grauwet K, Zhang X, Lawler SE, Reardon DA, Goins WF, *et al*: Glioblastoma infiltration of both tumor- and virus-antigen specific cytotoxic T cells correlates with experimental virotherapy responses. *Sci Rep* 10: 5095, 2020.
110. Brenner AJ, Peters KB, Vredenburg J, Bokstein F, Blumenthal DT, Yust-Katz S, Peretz I, Oberman B, Freedman LS, Ellingson BM, *et al*: Safety and efficacy of VB-111, an anticancer gene therapy, in patients with recurrent glioblastoma Results of a phase I/II study. *Neuro Oncol* 22: 694-704, 2020.
111. Agosti E, Zepieri M, De Maria L, Tedeschi C, Fontanella MM, Panciani PP and Ius T: Glioblastoma Immunotherapy: A Systematic Review of the Present Strategies and Prospects for Advancements. *Int J Mol Sci* 24: 15037, 2023.
112. Luksik AS, Yazigi E, Shah P and Jackson CM: CAR T Cell Therapy in Glioblastoma: Overcoming Challenges Related to Antigen Expression. *Cancers (Basel)* 15: 1414, 2023.
113. Vitanza NA, Wilson AL, Huang W, Seidel K, Brown C, Gustafson JA, Yokoyama JK, Johnson AJ, Baxter BA, Koning RW, *et al*: Intraventricular B7-H3 CAR T Cells for Diffuse Intrinsic Pontine Glioma: Preliminary First-in-Human Bioactivity and Safety. *Cancer Discov* 13: 114-131, 2023.
114. Omuro A, Brandes AA, Carpentier AF, Idbaih A, Reardon DA, Cloughesy T, Sumrall A, Baehring J, van den Bent M, Bähr O, *et al*: Radiotherapy combined with nivolumab or temozolomide for newly diagnosed Glioblastoma with unmethylated MGMT promoter: An international randomized phase III trial. *Neuro Oncol* 25: 123-134, 2023.
115. Reardon DA, Brandes AA, Omuro A, Mulholland P, Lim M, Wick A, Baehring J, Ahluwalia MS, Roth P, Bähr O, *et al*: Effect of nivolumab vs bevacizumab in patients with recurrent glioblastoma: The checkmate 143 phase 3 Randomized clinical trial. *JAMA Oncol* 6: 1003-1010, 2020.
116. Schalper KA, Rodriguez-Ruiz ME, Diez-Valle R, López-Janeiro A, Porciuncula A, Idoate MA, Inogés S, de Andrea C, López-Díaz de Cerio A, Tejada S, *et al*: Neoadjuvant nivolumab modifies the tumor immune microenvironment in resectable glioblastoma. *Nat Med* 25: 470-476, 2019.
117. Liu X, Chen X, Shi L, Shan Q, Cao Q, Yue C, Li H, Li S, Wang J, Gao S, *et al*: The third-generation EGFR inhibitor AZD9291 overcomes primary resistance by continuously blocking ERK signaling in glioblastoma. *J Exp Clin Cancer Res* 38: 219, 2019.
118. Rong L, Li N and Zhang Z: Emerging therapies for glioblastoma: Current state and future directions. *J Exp Clin Cancer Res* 41: 142, 2022.
119. Marei HE, Althani A, Caceci T, Arriga R, Sconocchia T, Ottaviani A, Lanzilli G, Roselli M, Caratelli S, Cenciarelli C and Sconocchia G: Recent perspective on CAR and Fcγ-CR T cell immunotherapy for cancers: Preclinical evidence versus clinical outcomes. *Biochem Pharmacol* 166: 335-346, 2019.
120. Karachi A, Dastmalchi F, Nazarian S, Huang J, Sayour EJ, Jin L, Yang C, Mitchell DA and Rahman M: Optimizing T cell-based therapy for glioblastoma. *Front Immunol* 12: 705580, 2021.
121. O'Rourke DM, Nasrallah MP, Desai A, Melenhorst JJ, Mansfield K, Morrisette JJ, Martinez-Lage M, Brem S, Maloney E, Shen A, *et al*: A single dose of peripherally infused EGFRvIII-directed CAR T cells mediates antigen loss and induces adaptive resistance in patients with recurrent glioblastoma. *Sci Transl Med* 9: eaaa0984, 2017.
122. Ahmed N, Brawley V, Hegde M, Bielamowicz K, Kalra M, Landi D, Robertson C, Gray TL, Diouf O, Wakefield A, *et al*: HER2-Specific chimeric antigen receptor-modified virus-specific T cells for progressive glioblastoma: A phase 1 dose-escalation trial. *JAMA Oncol* 3: 1094-1101, 2017.
123. Marei HE, Althani A, Afifi N, Hasan A, Caceci T, Pozzoli G and Cenciarelli C: Current progress in chimeric antigen receptor T cell therapy for glioblastoma multiforme. *Cancer Med* 10: 5019-5030, 2021.
124. Suryadevara CM, Desai R, Abel ML, Riccione KA, Batich KA, Shen SH, Chongsathidkiet P, Gedeon PC, Elsamadicy AA, Snyder DJ, *et al*: Temozolomide lymphodepletion enhances CAR abundance and correlates with antitumor efficacy against established glioblastoma. *Oncoimmunology* 7: e1434464, 2018.
125. Choi BD, Yu X, Castano AP, Bouffard AA, Schmidts A, Larson RC, Bailey SR, Boroughs AC, Frigault MJ, Leick MB, *et al*: CAR-T cells secreting BiTEs circumvent antigen escape without detectable toxicity. *Nat Biotechnol* 37: 1049-1058, 2019.
126. Muhammad N, Wang R, Li W, Zhang Z, Chang Y, Hu Y, Zhao J, Zheng X, Mao Q and Xia H: A novel TanCAR targeting IL13Rα2 and EphA2 for enhanced glioblastoma therapy. *Mol Ther Oncolytics* 24: 729-741, 2022.
127. Hegde M, Mukherjee M, Grada Z, Pignata A, Landi D, Navai SA, Wakefield A, Fousek K, Bielamowicz K, Chow KK, *et al*: Tandem CAR T cells targeting HER2 and IL13Rα2 mitigate tumor antigen escape. *J Clin Invest* 131: e152477, 2021.
128. Schmidts A, Srivastava AA, Ramapriyan R, Bailey SR, Bouffard AA, Cahill DP, Carter BS, Curry WT, Dunn GP, Frigault MJ, *et al*: Tandem chimeric antigen receptor (CAR) T cells targeting EGFRvIII and IL-13Rα2 are effective against heterogeneous glioblastoma. *Neurooncol Adv* 5: vdc185, 2022.
129. Bielamowicz K, Fousek K, Byrd TT, Samaha H, Mukherjee M, Aware N, Wu MF, Orange JS, Sumazin P, Man TK, *et al*: Trivalent CAR T cells overcome interpatient antigenic variability in glioblastoma. *Neuro Oncol* 20: 506-518, 2018.

130. Iurlaro R, Waldhauer I, Planas-Rigol E, Bonfill-Teixidor E, Arias A, Nicolini V, Freimoser-Grundschober A, Cuartas I, Martínez-Moreno A, Martínez-Ricarte F, *et al*: A Novel EGFRvIII T-Cell bispecific antibody for the treatment of glioblastoma. *Mol Cancer Ther* 21: 1499-1509, 2022.
131. Marei HE, Hasan A, Pozzoli G and Cenciarelli C: Cancer immunotherapy with immune checkpoint inhibitors (ICIs): Potential, mechanisms of resistance, and strategies for reinvigorating T cell responsiveness when resistance is acquired. *Cancer Cell Int* 23: 64, 2023.
132. Ye L, Park JJ, Dong MB, Yang Q, Chow RD, Peng L, Du Y, Guo J, Dai X, Wang G, *et al*: In vivo CRISPR screening in CD8 T cells with AAV-Sleeping Beauty hybrid vectors identifies membrane targets for improving immunotherapy for glioblastoma. *Nat Biotechnol* 37: 1302-1313, 2019.
133. Sconocchia G, Zlobec I, Lugli A, Calabrese D, Iezzi G, Karamitopoulou E, Patsouris ES, Peros G, Horcic M, Tornillo L, *et al*: Tumor infiltration by FcγRIII (CD16)+ myeloid cells is associated with improved survival in patients with colorectal carcinoma. *Int J Cancer* 128: 2663-2672, 2011.
134. Sconocchia G, Eppenberger-Castori S, Zlobec I, Karamitopoulou E, Arriga R, Coppola A, Caratelli S, Spagnoli GC, Lauro D, Lugli A, *et al*: HLA class II antigen expression in colorectal carcinoma tumors as a favorable prognostic marker. *Neoplasia* 16: 31-42, 2014.
135. Sconocchia G, Spagnoli GC, Del Principe D, Ferrone S, Anselmi M, Wongsena W, Cervelli V, Schultz-Thater E, Wyler S, Carafa V, *et al*: Defective infiltration of natural killer cells in MICA/B-positive renal cell carcinoma involves beta(2)-integrin-mediated interaction. *Neoplasia* 11: 662-671, 2009.
136. Gangoso E, Southgate B, Bradley L, Rus S, Galvez-Cancino F, McGivern N, Güç E, Kapourani CA, Byron A, Ferguson KM, *et al*: Glioblastomas acquire myeloid-affiliated transcriptional programs via epigenetic immunoediting to elicit immune evasion. *Cell* 184: 2454-2470.e26, 2021.
137. Ravi VM, Neidert N, Will P, Joseph K, Maier JP, Kückelhaus J, Vollmer L, Goeldner JM, Behringer SP, Scherer F, *et al*: T-cell dysfunction in the glioblastoma microenvironment is mediated by myeloid cells releasing interleukin-10. *Nat Commun* 13: 925, 2022.



Copyright © 2024 Ius et al. This work is licensed under a Creative Commons Attribution-NonCommercial-NoDerivatives 4.0 International (CC BY-NC-ND 4.0) License.