




Contents lists available at ScienceDirect

## Current Problems in Surgery

journal homepage: [www.elsevier.com/locate/cpsurg](http://www.elsevier.com/locate/cpsurg)

## Surgical approaches for bilateral Eagle's syndrome: A narrative review of literature



Stefania Troise, MD<sup>a</sup>, Emanuele Carraturo, MD<sup>a,\*</sup>,  
 Rebecca Napolitano, MD<sup>a</sup>, Raffaele Merola, MD<sup>b</sup>,  
 Luigi Angelo Vaira, MD<sup>c</sup>, Vincenzo Abbate, MD<sup>a</sup>,  
 Antonio Romano, MD<sup>a</sup>, Paola Bonavolontà, MD<sup>a</sup>,  
 Luca Raccampo, MD<sup>d</sup>, Salvatore Sembronio, MD<sup>d</sup>,  
 Massimo Robiony, MD<sup>d</sup>, Giacomo De Riu, MD<sup>c</sup>,  
 Pasquale Piombino, MD<sup>e</sup>

### Introduction

Eagle's syndrome is defined as elongation of the styloid process or the stylohyoid ligament mineralization complex which consists of styloid process, stylohyoid ligament and lesser horn of hyoid bone. The condition is named after Dr. Watt W. Eagle, who first described it in 1937.<sup>1,2</sup>

Eagle's syndrome can cause a variety of symptoms, including recurrent facial and throat pain, dysphagia, odynophagia, parapharyngeal foreign body sensation, otalgia and neck pain. The pain can be triggered by certain movements of the neck or head, such as turning the head or swallowing.<sup>3</sup> The syndrome has a symptomatic prevalence of approximately 0.16%—since only about 4% of the 4% of people with elongation exhibit symptoms.<sup>4</sup> It most commonly affects middle-aged to elderly individuals and is more frequently diagnosed in women.<sup>5</sup> Risk factors include previous tonsillectomy or neck trauma, suggesting both congenital and acquired origins.<sup>6</sup> Due to its wide range of nonspecific symptoms—such as cervicofacial pain, dysphagia, or foreign body sensation—it is frequently misdiagnosed as more common conditions like temporomandibular joint disorder or trigeminal neuralgia.<sup>7</sup>

From the <sup>a</sup>Department of Neurosciences, Maxillofacial Surgery Unit, Reproductive and Odontostomatological Sciences, University of Naples Federico II, Naples, Italy; <sup>b</sup>Department of Neurosciences, Anesthesia and Intensive Care Medicine, Reproductive and Odontostomatological Sciences, University of Naples Federico II, Naples, Italy; <sup>c</sup>Department of Medical, Maxillofacial Surgery Operative Unit, Surgical and Experimental Sciences, University of Sassari, Sassari, Italy; <sup>d</sup>Maxillofacial Surgery Department, Academic Hospital of Udine, Department of Medicine (DMED), University of Udine, Udine, Italy; and <sup>e</sup>Maxillofacial Surgery Unit, Caserta Hospital "Sant'Anna e San Sebastiano", Caserta, Italy

\* Address reprint requests to Emanuele Carraturo, MD, Department of Maxillofacial Surgery, Federico II University of Naples, Via Pansini, 5, 80131, Naples, Italy.

E-mail address: [emanuele.c2971995@gmail.com](mailto:emanuele.c2971995@gmail.com) (E. Carraturo).

<https://doi.org/10.1016/j.cpsurg.2025.101765>

0011-3840/© 2025 The Author(s). Published by Elsevier Inc. This is an open access article under the CC BY license (<http://creativecommons.org/licenses/by/4.0/>)

The condition can be diagnosed through physical examination and imaging tests, such as X-rays or CT scans.<sup>8</sup>

While Eagle's syndrome is relatively rare, it can cause significant discomfort and impact a person's quality of life. Therefore, it's important for individuals experiencing symptoms to seek medical attention from a qualified healthcare professional.<sup>9</sup> Eagle's syndrome can be treated conservatively (lacing local anesthetic into the styloid process and stylomandibular ligament attachment) or surgically. Although physical therapy and drug therapy are treatment options, the choice many times is surgery. However, which is the most correct surgical approach based on the different characteristics of the patient remains a debated topic.<sup>10</sup>

The treatment of choice is styloidectomy, which can be performed transorally or extraorally.<sup>11</sup> The extraoral or transcervical approach gives a more suitable anatomic exposure of both the SP and nearby structures, which would decrease the risk of vascular injury. Technically, the intraoral approach is relatively easy to perform due to less fascial dissection and less time consumption. However, it normally requires tonsillectomy and has disadvantages such as poor visualization, risk of neurovascular injury, and higher possibility of deep cervical infection. So, to date, the approach to choose remains a challenge for the surgeon.<sup>12,13</sup> The current study aims to provide a narrative review about the approaches typically adopted for the management of the Eagle's Syndrome, identifying the most correct approach based on the patient's features.

## Materials and method

### *Search strategy*

An online literature search on PubMed and MEDLINE was exploited to identify articles in English investigating on Eagle's Syndrome surgical approaches, from 2016 up 2023. Keywords queried included a various arrangement of the following terms: "Eagle's Syndrome," "Surgical," "Approaches," "Styloid process," "elongation," "Styloid process elongation," "Surgical management."

### *Studies selection*

Eligibility criteria excluded articles that reported Eagle's Syndrome surgical approach not written in English. All papers without abstract have been excluded. Additional queries were performed based on relevant references of the articles searched as well. All papers that included a patient study with outcomes were considered, consequently all reviews and systematic reviews were excluded.

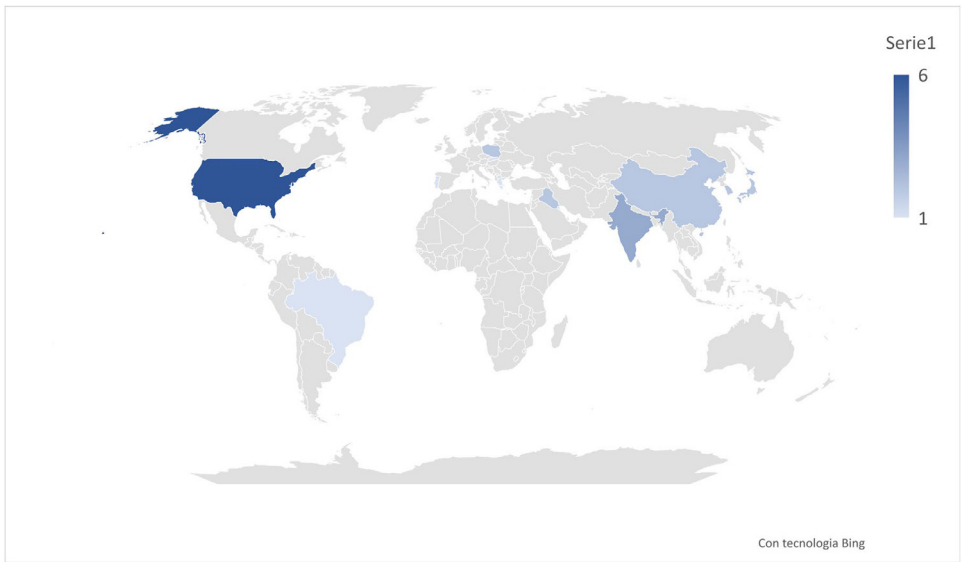
### *Data collection*

The data recorded included number of patients, side of the elongation, size, surgical approach, advantages and complications. The surgical approaches used for the removal of the styloid process were transoral, included the robotic-assisted procedures, or extraoral, included transcervical and retromandibular/submandibular.

## Results

### *Selected studies*

A total of 23 article were included in the review, being 7 retrospective cohort studies, 2 prospective studies, 5 case reports and 5 case series (1 case report and 1 case series were



**Fig. 1.** Distribution of the papers reviewed for nationality.

counted in the merit of 2 studies that also proposed retrospective studies). Regarding the nationality of origin of the papers, 6 are from the USA, 3 from India, 2 from China, 1 from Slovakia, 1 from Portugal, 2 from Iraq (of whom 1 from Pakistan also), 1 from Brazil, 2 from South Korea, 2 from Japan, 1 from Greece, 2 from Poland (Table 1, Fig. 1).

The total amount of patients from the review was 337.

A total of 206 patients were treated through the transoral approach, 4 of them using the robot (TORS) and 131 were treated with the external approach through transcervical incision.

Of the 23 articles, 8 studied the transoral approach, 9 the transcervical and 6 were mixed articles (retrospective studies) that evaluated a case series comprising both approaches.

The transoral approach was used in 63% of cases (212 patients) while the transcervical approach was used in 37% of cases (125 patients).

The wider range observed (total range) is 1.2-8 cm throughout the review. Specifically, for the transoral approach, the maximum size range of the styloid process was 1.1-6 cm, while for the transcervical approach it was 1.4-8 cm (Table 2).

As for indication, the greater majority of patients fell within the typical symptomatology caused elongated styloid process, consisting of odinophagia, dysphagia, neck pain, sensation of pain in the throat and specifically in swallowing, otalgia, pain on rotation of the neck, pain on extension of the tongue, change in voice, and a sensation of hypersalivation. By the way, 9 patients received styloidectomy due to nervous compression. Specifically 1 had hypoglossus nerve compression with hypomobility of the hemitongue concerned, 2 patients had spinal accessory nerve compression with ipomobility of omolateral trapezius muscle and persistent shoulder syndrome and 6 patients had glossopharyngeal nerve compression, with cervical pain. 6 patients underwent styloidectomy due to vascular compression, developing the "carotid artery syndrome," consisting of transient ischemic attacks and/or syncopal episodes along with unspecified cerebral symptoms (Table 3).

The main complications observed for the transoral approach were airway oedema, neck infection, first bite syndrome, postoperative numbness, bleeding and pain, otalgia, odynophagia, tinnitus, foreign body sensation in the throat, neck pain, tonsillar hemorrhage, transient lingual nerve hypoesthesia. The main complications for the transcervical approach were facial nerve paresthesia and auricular hypoesthesia. All complications are summarized in Table 3. Of the 2

**Table 1**

List of papers included in the review.

Author	Title	Year	Nationality	Type of study	Nr of pt	Side	Defect type with size (where available)	Surgical procedure (approach)	Advantages	Complications	Vascular Involvement (n. of pt)
Annuradha Dey et al. <sup>13</sup>	Eagle's Syndrome: A Diagnostic Challenge and Surgical Dilemma	2020	India	Case report	1	Monolateral (Right)		Transcervical	- Best exposure of styloid, - lower risk of infection, - cleaner wound, - decrease the risk of vascular injury.		0
Candace M Waters et al. <sup>14</sup>	Surgical Management of Stylohyoid Pain (Eagle's) Syndrome: A 5-Year Experience	2019	USA	Retrospective review + case series	32		Range 2.3-8.0 cm	Transcervical (except 1 pt transoral)	- Best exposure of styloid (>4 cm). - cleaner wound, - lower risk of infection, - can eat immediately after surgery.		0
Chenjing Cheng et al. <sup>15</sup>	The experience of treatment of coblation assisted surgical approach to Eagle's syndrome	2017	China	Case series	62	Bilateral 18, Left 12, Right 32	Range 1.2-2.8 cm,	Transoral	- Easier, - faster, - no undesirable scar.	- Airway edema, - neck infection, - postoperative bleeding.	0
Czako L et al. <sup>16</sup>	3D navigation in surgery of Eagle syndrome	2019	Slovakia	Case report	1			Transcervical	- Safer, - easier (> 3.5-4 cm), - long lasting symptomatic relief, - best exposure of styloid.		0
Diana Breda et al. <sup>17</sup>	Recurrent Syncope Related to Carotid Compression in Eagle Syndrome: A Case Report	2023	Portugal	case report	1	Bilateral	Range 3.8-4.3 cm	Transcervical	- Best exposure of styloid, - higher exposure to the carotid artery, - scar.		1

*(continued on next page)*

**Table 1** (continued)

Author	Title	Year	Nationality	Type of study	Nr of pt	Side	Defect type with size (where available)	Surgical procedure (approach)	Advantages	Complications	Vascular Involvement (n. of pt)
D.H. Kim et al. <sup>18</sup>	Transoral robotic surgery in Eagle's syndrome: our experience on 4 patients	2017	Korea	Case series	4	Bilateral	Range 3.3-5.1 cm	Transoral (TORS)	<ul style="list-style-type: none"> <li>- Magnified view,</li> <li>- easily distinguish tiny structures,</li> <li>- 360° rotating instruments,</li> <li>- surgical safety,</li> <li>- preservation of neurovascular structures.</li> </ul>		0
Emma De Ravin et al. <sup>19</sup>	Transcervical styloidectomy for Eagle syndrome	2022	USA	Case report + Review	15	Case report Right	Range 1.9-6.9 cm	Transcervical	<ul style="list-style-type: none"> <li>- Long lasting symptomatic relief,</li> <li>- best exposure of styloid,</li> <li>- lower risk of infection,</li> <li>- cleaner wound.</li> </ul>	Recurrent symptoms	2
Eric C Mitchell et al. <sup>20</sup>	"Winged" Eagle's syndrome: neurophysiological findings in a rare cause of spinal accessory nerve palsy. Illustrative cases	2023	USA	Case series	2	Left	Range 2.2-2.3 cm	Transcervical	-	-	0
Felipe Constanzo et al. <sup>21</sup>	Modified craniocervical approach for resection of the styloid process in patients with Eagle's syndrome	2019	Brazil	Retrospective cohort study	12	Bilateral 6, Left: 9, Right: 3.	Range 2.3-4.7 cm	Transcervical	<ul style="list-style-type: none"> <li>- Avoiding postoperative palsy.</li> <li>- best exposure of styloid.</li> </ul>	- Auricular paresthesia.	2

(continued on next page)

**Table 1** (continued)

Author	Title	Year	Nationality	Type of study	Nr of pt	Side	Defect type with size (where available)	Surgical procedure (approach)	Advantages	Complications	Vascular Involvement (n. of pt)
Frances Mei Hardin et al. <sup>22</sup>	Surgical management of patients with Eagle syndrome	2018	USA	Retrospective cohort study	21		Range 2.0-4.0 cm	Transcervical (12) Transoral (9)	Transoral: - faster, - no undesirable scar. disadvantage: - limited visibility - risk of infection. Transcervical - longer, - visible scar, - best exposure of styloid, - cleaner wound, - lower risk of infection.	- First bite syndrome. (Transoral approach);	0
I. Papadiochos et al. <sup>23</sup>	Treatment of Eagle syndrome with transcervical approach secondary to a failed intraoral attempt: Surgical technique and literature review	2017	Greece	Case report	1	Monolateral left	3.8 cm	Transcervical (after a first transoral approach failed)	- faster	temporary paresis of the lower lip (transoral)	0

(continued on next page)

Table 1 (continued)

Author	Title	Year	Nationality	Type of study	Nr of pt	Side	Defect type with size (where available)	Surgical procedure (approach)	Advantages	Complications	Vascular Involvement (n. of pt)
Jing Wang et al. <sup>24</sup>	Intraoral and extraoral approach for surgical treatment of Eagle's syndrome: a retrospective study	2021	China	Retrospective study + case report	103	Bilateral (case report)	(Case report: R 4.4 cm L 5.5 cm)	Transcervical (21); Transoral (82)	Transoral: - small internal diameter, -quick recovery. Transcervical: - safer, - best exposure of styloid, - lower risk of infection, - cleaner wound, - decrease the risk of vascular injury.	Tonsillar hemorrhage	0
Magdalena Wacawek et al. <sup>25</sup>	Own experience in the diagnosis and treatment of elongated styloid proce syndrome	2021	Poland	Case series	5	4 bilateral 1monolateral	Range 2.2-6.0 cm	Transoral	- Faster, - no undesirable scar.	- Odinophagia - edema.	0
Malarvizhi Ravisankar et al. <sup>26</sup>	Evaluation of Eagle's Syndrome and Assessment of Postoperative Outcome of Excision of Elongated Styloid Process: A Prospective Study, in Tertiary Care Centre, India	2020	India	Prospective Study	20	Bilateral 14, Left 2, Right 4.	Average 4.1 cm	Transoral	- Safer, - long lasting symptomatic relief.	Dysphagia	0

(continued on next page)

Table 1 (continued)

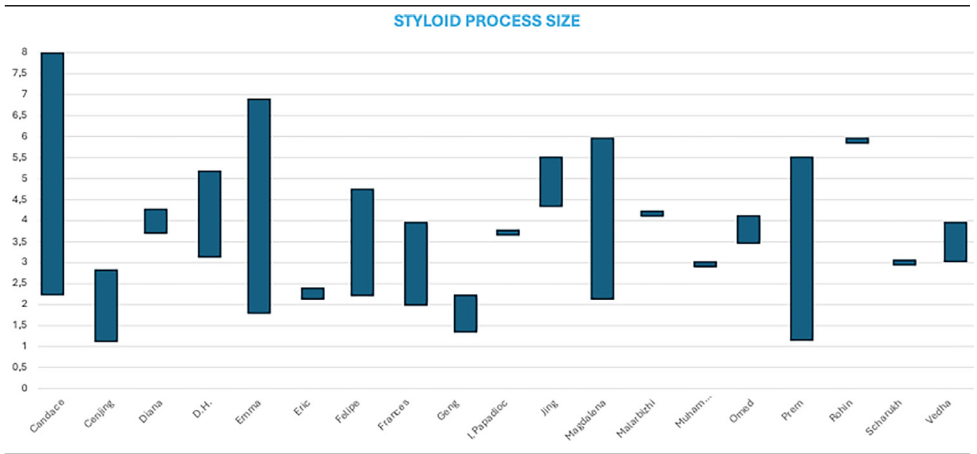
Author	Title	Year	Nationality	Type of study	Nr of pt	Side	Defect type with size (where available)	Surgical procedure (approach)	Advantages	Complications	Vascular Involvement (n. of pt)
Marcin Czajka et al. <sup>27</sup>	Assessment of surgical treatment of Eagle's syndrome	2019	Poland	Retrospective study	15			Transcervical (14), Transoral (1)	Transoral - no undesirable scar, - local anesthesia. Transcervical - visible scar, - general anesthesia.	Facial nerve paresthesia	0
Muhammad Ayhan Amir et al. <sup>28</sup>	Battling the Eagle's sharp beak, Eagle syndrome; a case report	2023	Pakistan; Iraq	Case report	1	Left	3 cm	Transcervical	-	-	0
Omed Shafiq Hamamin et al. <sup>29</sup>	Chronically misdiagnosed Eagle's syndrome, treated through transoral styloidectomy: a rare case report	2023	Iraq	Case report	1	Bilateral	Range 3.5-4.1 cm	Transoral	- Easier, - faster, - no undesirable scar, - local anesthesia.	-	0
Prem Shankar Kumar et al. <sup>30</sup>	Of Eagle's Syndrome and Finding Some Clarity on Its Management	2020	India	Prospective study	15		Range 1.1-5.5 cm	Transoral (8)	Transoral: - better surgical and tissue knowledge	- Pain, - trismus.	0
Rohin Singh et al. <sup>31</sup>	Surgical management of Eagle's syndrome causing neurovascular compression	2023	USA	Case report	2	Bilateral	Max size 5.98 cm	Transcervical	- Lower risk of complications.		1 (Jugular)

(continued on next page)

Table 1 (continued)

Author	Title	Year	Nationality	Type of study	Nr of pt	Side	Defect type with size (where available)	Surgical procedure (approach)	Advantages	Complications	Vascular Involvement (n. of pt)
Scharukh Jalisi et al. <sup>32</sup>	Surgical management of long-standing Eagle's syndrome	2017	USA	Retrospective review	6	Bilateral	Max size 3 cm	Transoral 3, Transcervical 3	Transcervical - safer, - best exposure of styloid, - lower risk of infection, - cleaner wound, - decrease the risk of vascular injury.	- Transient lingual nerve hypoesthesia (transoral)	0
Shintaro Sukegawa et al. <sup>33</sup>	Use of an intraoperative navigation system and piezoelectric surgery for styloidectomy in a patient with Eagle's syndrome: a case report	2017	Japan	Case report	1	Monolateral		Transoral	- Easier - no undesirable scar		0
Vedha Aravindan et al. <sup>34</sup>	Extraoral versus intraoral approach for removal of styloid process in treatment of Eagle's syndrome: A report of 2 cases	2023	India	Case series	2	1. Right 2. Bilateral	3-4 cm	1. Transcervical 2. Transoral	Transoral - faster, - quick recovery, - no undesirable scar. Transcervical - best exposure of styloid, - visible scar.		0
Yoshihiko Kumai et al. <sup>35</sup>	Surgical management of Eagle's syndrome: an approach to shooting craniofacial pain	2016	Japan	Retrospective study	8	Bilateral		Transoral	- Easier - no undesirable scar, - faster, - quick recovery.		0

**Table 2**  
Distribution of the styloid process length range for the papers reviewed.



**Table 3**  
Distribution of patients for symptoms.

Classical "Stylohyoid syndrome (n. of pt)	Nerve compression syndrome	Carotid artery syndrome
322	9	6

**Table 4**  
Postoperative complications reported for the transoral and transcervical approaches.

Transoral approach	No. of patients
Only pain in the throat	12
Foreign body sensation in the throat	21
Pain on changing head position	20
Earache	4
Pain in lower right neck	2
Pain in the throat, worsen when changing the head position	3
Tonsillar hemorrhage	2
Temporary paresis of the lower lip	1
First bite syndrome	5
Odinophagia/Dysphagia	22
Lingual nerve hypoesthesia	1
Transcervical approach	
Auricular paresthesia	2
Facial nerve paresthesia	1
Recurrent symptoms (unspecified)	9

approaches, the transoral approach generated postoperative complications in 93 patients (45%) while the transcervical approach in 12 patients (9.6%) (Table 4).

All procedures were done under general or local anesthesia. Intubation of choice was intraoral for the transcervical approach and intranasal for the transoral. Local anesthesia was used only in one case of transoral approach.

**Discussion**

Eagle syndrome is a condition characterized by an elongated styloid process or calcification of the stylohyoid ligament, leading to symptoms such as orofacial pain, neck pain, and dysphagia.

Surgical intervention is often considered when conservative treatments fail to alleviate symptoms. There are primarily 2 surgical approaches for treating Eagle syndrome: the transoral and transcervical approaches.

The transoral approach involves accessing the styloid process through the mouth, which can be less invasive and offers a direct route to the styloid process. However, it may present challenges such as limited visibility and increased risk of infection due to the oral cavity's environment.<sup>1,3,6</sup> Despite these challenges, the transoral approach, including variations like transoral robotic surgery (TORS), has shown high success rates with minimal complications, making it a viable option for many patients.<sup>5</sup>

On the other hand, the transcervical approach involves an external incision in the neck, providing better visibility and access to the styloid process. This method is often preferred for more complex cases or when the transoral approach is not feasible. It allows for more precise removal of the styloid process and is associated with fewer intraoperative risks.<sup>2,9,10</sup> Recent advancements, such as the use of piezoelectric surgery and surgical navigation, have enhanced the safety and efficacy of the transcervical approach, particularly in complex cases.<sup>1</sup>

Both approaches have their advantages and limitations, and the choice of technique often depends on the surgeon's experience and the specific clinical scenario. Overall, surgical treatment for Eagle syndrome is effective in alleviating symptoms, with most patients experiencing significant improvement postoperatively.<sup>2,8</sup> The aim of the review is to evaluate the characteristics, merits, flaws and differences between the 2 approaches described above.

The indications most typically emphasized for styloidectomy among the articles considered in the review were odinophagia, dysphagia, neck pain, sensation of pain in the throat and specifically in swallowing, otalgia, pain on rotation of the neck, pain on extension of the tongue, change in voice, and a sensation of hypersalivation.<sup>36-38</sup> Specifically, Kumar et al. noted that the symptom most present in their cohort of patients (37) was throat pain with hemifacial radiation both with pharyngeal foreign body sensation.<sup>30</sup> This was followed by odinophagia and otalgia and they also recorded one case of dizziness. Jalisi et al. in their cohort (12 patients) identified neck pain as the most common symptom, followed by otalgia, dysphagia, odinophagia and foreign body sensation in the parapharyngeal space.<sup>32</sup> Singh et al. described in their case report 1 case of a patient with hypoglossal nerve palsy due to compression of the styloid process.<sup>31</sup> This condition appears to be very rare and poorly described in the literature.<sup>39,40</sup> Mitchell et al., instead, described 2 cases of spinal accessory nerve compression by elongated styloid process, resulting in persistent low mobility of omolateral trapezius muscle and persistent shoulder syndrome. Also this condition found few related cases in literature.<sup>20</sup> Lastly, in the compendium of nerve compressions, Youshihuko et al. described 6 cases of patients treated with styloidectomy for glossopharyngeal nerve palsy. Again, being a very rare condition, few cases are described in literature.<sup>35</sup>

It must be said that this type of symptomatology described above falls within the framework of the typical stylohyoid syndrome described by Eagle in 1948.<sup>41</sup>

In that context Eagle also described the possibility of a symptom picture consisting of reversible transient ischemic attacks, consisting of ophthalmic symptoms and episodes of presyncope with extensive head turn due to an elongated styloid process compressing the carotid artery, and decreasing blood flow in the medial cerebral artery, falling under the term of stylo-carotid syndrome, later on described as "carotid artery syndrome." In our review, 6 patients (2%) fell under this definition. This percentage, although low, is in not so distant from the literature, which reports vascular involvement in approximately 4%-5% of cases of Eagle's syndrome.<sup>16,17</sup>

In this review, of the 2 approaches the transoral approach generated postoperative complications in 93 patients (45%) while the transcervical in 12 patients (9.6%).

The main postoperative complication for the transoral approach were airway edema, neck infection, first bite syndrome, postoperative numbness, bleeding and pain, otalgia, odynophagia, tinnitus, foreign body sensation in the throat, neck pain, tonsillar hemorrhage, transient hypoesthesia of the lingual nerve. Cheng et al. in their paper have analyzed the main complaints on 62 patients treated through transoral styloidectomy, both monolateral (44) and bilateral (18). Specifically, only pain in the throat was reported in 12 pz, foreign body sensation in the throat

in 21pz, pain on changing head position in 20 pz, earache in 4 pz, pain in lower right neck in 2 pz, pain in the throat, worsen when changing the head position in 3 pz.<sup>15</sup>

Only one case of transient facial nerve paresthesia was detected in the Transcervical approach (Czajka et al.) while auricular paresthesia was only found in 2 patients, by the way it was transient, as stated by Costanzo et al. De Ravin et al. for this approach reported in their paper 9 episodes of patients with complicancies consisting of unspecified recurrent symptoms, 3 of them being permanent.<sup>16</sup>

First bite syndrome, a clinical diagnosis, is a known potential complication of operations in the parapharyngeal space that leads to severe pain with the first bite of a meal was reported in their paper by Hardin et al. in 5 patients, 2 of them having long-time resolution.<sup>22</sup>

As for the length of the styloid process removed, in this review no particular difference has been found for the 2 approaches. Specifically, for the transoral approach, the maximum size range of the styloid process was 1.1-6 cm, while for the transcervical approach it was 1.4-8 cm. While having reported very similar results, showing that the transcervical approach and the transoral approach could be suited ideally for styloidectomy of any dimension, this does not mean that the 2 approaches are equally effective and straightforward in treating any range of styloidectomy lengths, The papers analyzed in this review address the limit for safe, fast and effective styloidectomy at 3.5-4 cm in length, indicating larger sizes to be treated with the transcervical approach and smaller sizes with the transoral approach (Table 1)

In this review some other differences have been reported. Although from what is shown in the results, the transcervical approach generated far fewer postoperative complications, Table 1 shows that almost all the authors agree in reporting the presence of a visible skin scar as a negative in this approach. As precise as the surgical technique is, there is no doubt that this risk is only related to the transcervical approach, since the transoral approach does not involve cutaneous surgical access. Similarly, however, the transcervical approach has shown (at least in the opinion of the authors included in the review) an advantage in the treatment of styloid processes greater than 4 cm in length, given the wider surgical field of the transoral approach. Kim et al., however, to overcome this limitation of the transoral approach suggests the use of a robot (TORS) that allows for image magnification and 360° rotation of the view.<sup>18</sup> Although very interesting, it must be emphasized that this type of treatment can only be performed in centers equipped with this type of technology, Furthermore, although some authors have noted the risk of infection in the deep spaces of the neck, Table 1 shows that the risk of infection is actually greater in the transoral approach, the oral cavity being by definition a contaminated environment. Finally, both approaches require general anesthesia, although in only one case of transoral approach is the use of local anesthesia reported (Czajka et al.).<sup>27</sup> There is no doubt that, ideally, this type of approach, being less invasive, may make it possible to avoid intubating the patient, but doubts arise as to the safety of the upper airway, especially in the event of bleeding.<sup>42</sup>

The message that could be obtained from this review is that neither approach has absolute advantages or disadvantages and that the choice of approach should be dependent on the surgeon's preference as well as tailored to the patient. For convenience, the main advantages and disadvantages have been summarized in Table 5.

**Table 5**

Advantages and disadvantages of transoral and transcervical approaches.

Transcervical	Transoral
Best exposure of styloid > 4 cm	Limited visibility
Cleaner wound and lower risk of infection	Risk of infection
Visible scar	No undesirable scar
General anesthesia	Local anesthesia
Safer and easier > 3.5-4 cm	Faster and easier < 3.5 cm
Can eat immediately after surgery	Quick recovery

## Conclusion

Within the limits of a narrative review, this paper made it possible to evaluate the main complications and the main benefits of the 2 approaches, transoral and transcervical, being able to derive a summary table on the indications (4). The limitations of this review must also be underlined in the number of papers analyzed, but also in the impossibility of discerning between the different approaches (submandibular, retromandibular) summarized in the term transcervical. The aim of the next reviews should be to systematize the research in order to increase the number of papers and to evaluate the pros and cons of the different transcervical approaches.

## Author contributions

**Stefania Troise:** Conceptualization, writing – editing, final approval; **Emanuele Carraturo:** writing original version; **Rebecca Napolitano:** writing original version; **Raffaele Merola:** Methodology; Project administration; **Luigi Angelo Vaira:** Formal analysis; Software; **Vincenzo Abbate:** Methodology; Project administration, **Paola Bonavolontà:** data curation, data elaboration; **Antonio Romano:** data curation, data elaboration; **Luca Raccampo:** Data curation; Formal analysis, **Salvatore Sembronio:** Conceptualization; Data curation; **Massimo Robiony:** Resources; Software, **Giacomo De Riu:** Methodology; Project administration, **Pasquale Piombino:** data curation, data elaboration.

## References

- Spalthoff S, Zimmerer R, Dittmann O, et al. Piezoelectric surgery and navigation: a safe approach for complex cases of Eagle syndrome. *Int J oral Maxillofac Surg.* 2016;45(10):1261–1267. doi:10.1016/j.ijom.2016.05.011.
- Hardin F, Xiao R, Burkey B. Surgical management of patients with Eagle syndrome. *Am J Otolaryngol.* 2018;39(5):481–484. doi:10.1016/j.amjoto.2018.05.003.
- Held M, Farsi S, Creighton E, Davis K, King D, Suen J. Eagle syndrome presentation and outcomes in a large surgical case series. *Laryngoscope Invest Otolaryngol.* 2024;9. doi:10.1002/liao.1289.
- Hassen I, Daghfous M, Kedous S. Eagle syndrome imaging: a case report. *J Otolaryngol-ENT Res.* 2018. doi:10.15406/joentr.2018.10.00361.
- Nedunchezian K. Eagle syndrome – An overview. *S Afr Med J.* 2017;21. doi:10.4102/SAJR.V2111.1247.
- Ramos M, Canales-Sermeño G, Chacaltana-Limaco R. Eagle syndrome: a review of the literature. *World Health J.* 2020. doi:10.47422/whj.v1i2.6.
- De Lima, J, Rocha, J, Ribeiro, E, Costa, V, & Sousa, E Eagle syndrome: literature review. 2007; 45.
- Weteid A, Miloro M, Arabia S. Transoral endoscopic-assisted styloidectomy: how should Eagle syndrome be managed surgically? *Int J oral Maxillofac Surg.* 2015;44(9):1181–1187. doi:10.1016/j.ijom.2015.03.021.
- Keirns D, Asarkar A, Entezami P, Ware E, Nagel T, Chang B. Transoral robotic surgery for Eagle syndrome: a systematic review. *Ear Nose Throat J.* 2024 1455613241246587. doi:10.1177/01455613241246587.
- Ferreira M, Miranda G, Almeida F, et al. Complications in intraoral versus external approach for surgical treatment of Eagle syndrome: a systematic review and meta-analysis. *Cranio: J Craniomandib Pract.* 2022;1–13. doi:10.1080/08869634.2021.2020995.
- Kapoor S, Gupta A, Satya S, Saidha P, Saini U, Singh A. Role of the surgical approach in the treatment of Eagle syndrome. *Int Arch Otorhinolaryngol.* 2022;28:e400–e406. doi:10.1055/s-0043-1776717.
- Chen R, Liang F, Han P, Cai Q, Yu S, Huang X. Endoscope-assisted resection of elongated styloid process through a retroauricular incision: a novel surgical approach to Eagle syndrome. *J oral Maxillofac Surg.* 2017;75(7):1442–1448. doi:10.1016/j.joms.2017.01.016.
- Dey A, Mukherji S. Eagle's Syndrome: a diagnostic challenge and surgical dilemma. *J Maxillofac Oral Surg.* 2022;21(2):692–696. doi:10.1007/s12663-020-01396-x.
- Waters CM, Ho S, Luginbuhl A, Curry JM, Cognetti DM. Surgical management of stylohyoid pain (Eagle's) syndrome: a 5-year experience. *Ann Otol Rhinol Laryngol.* 2019;128(3):220–226. doi:10.1177/0003489418816999.
- Cheng C, She C, Zhang Q. The experience of treatment of coblation assisted surgical approach to Eagle's syndrome. *Am J Otolaryngol.* 2017;38(3):301–304. doi:10.1016/j.amjoto.2017.01.030.
- Czako L, Hirjak D, Simko K, Thurzo A, Janovszky A, Galis B. 3D navigation in surgery of Eagle syndrome. *Bratisl Lek Listy.* 2019;120(7):494–497. doi:10.4149/BLL\_2019\_078.
- Breda D, Ferreira S, Colino M, Cerveira E, Amado I. Recurrent syncope related to carotid compression in Eagle syndrome: a case report. *Cureus.* 2023;15(9):e45134. doi:10.7759/cureus.45134.
- Kim DH, Lee YH, Cha D, Kim SH. Transoral robotic surgery in Eagle's syndrome: our experience on four patients. La chirurgia robotica transorale nella sindrome di Eagle: nostra esperienza su quattro pazienti. *Acta Otorhinolaryngol Ital.* 2017;37(6):454–457. doi:10.14639/0392-100X-1502.
- De Ravin E, Frost AS, Mady LJ, Newman JG. Transcervical styloidectomy for Eagle syndrome. *Head Neck.* 2022;44(6):1492–1495. doi:10.1002/hed.27013.

20. Mitchell EC, Wu KY, Siddiqi F, et al. Winged" Eagle's syndrome: neurophysiological findings in a rare cause of spinal accessory nerve palsy. Illustrative cases. *J Neurosurg.* 2023;6(24):CASE23358. doi:10.3171/CASE23358.
21. Constanzo F, Ramina R, Coelho Neto M. Modified craniocervical approach for resection of the styloid process in patients with Eagle's Syndrome. *J Neurol Surg.* 2021;82(Suppl 3):e179–e183. doi:10.1055/s-0039-3400297.
22. Hardin FM, Xiao R, Burkey BB. Surgical management of patients with Eagle syndrome. *Am J Otolaryngol.* 2018;39(5):481–484. doi:10.1016/j.amjoto.2018.05.003.
23. Papadiochos I, Papadiochou S, Sarivalalis ES, Goutzani L, Petsinis V. Treatment of Eagle syndrome with transcervical approach secondary to a failed intraoral attempt: surgical technique and literature review. *J Stomatol Oral Maxillofac Surg.* 2017;73(6):353–358. doi:10.1016/j.jormas.2017.06.017.
24. Wang J, Wang Z, Yan K, Liu Y. Intraoral and extraoral approach for surgical treatment of Eagle's syndrome: a retrospective study. *Eur Arch Oto-Rhino-Laryngol.* 2021;279:1481–1487. doi:10.1007/s00405-021-06914-2.
25. Waclawek M, Pietkiewicz P, Niewiadomski P, Olszewski J. Own experience in the diagnosis and treatment of elongated styloid process syndrome. *Otolaryngol Polska.* 2020;75(2):21–27. doi:10.5604/01.3001.0014.3666.
26. Ravisankar M, Murugesan GS. Evaluation of Eagle's syndrome and assessment of post-operative outcome of excision of elongated styloid process: a prospective study, in Tertiary Care Centre, India. *Indian J Otolaryngol Head Neck Surg.* 2022;74(2):150–157. doi:10.1007/s12070-020-02255-4.
27. Czajka M, Szuta M, Zapała J, Janicka I. Assessment of surgical treatment of Eagle's syndrome. *Otolaryngol Polska.* 2019;73(5):18–24. doi:10.5604/01.3001.0013.1533.
28. Amir MA, Rehman IU, Riaz U, et al. Battling the Eagle's sharp beak, Eagle syndrome; a case report. *eNeurologicalSci.* 2023;31:100462. doi:10.1016/j.ensci.2023.100462.
29. Hamamin OS, Arif AT, Razha AB, et al. Chronically misdiagnosed Eagle's syndrome, treated through transoral styloidectomy: a rare case report. *Ann Med Surg.* 2023;85(7):3611–3614. doi:10.1097/MS9.0000000000000810.
30. Kumar PS, Singh DK, Gupta SK, Raina S, Prasad BK. Of Eagle's syndrome and finding some clarity on its management. *Indian J Otolaryngol Head Neck Surg.* 2022;74(Suppl 2):2184–2189. doi:10.1007/s12070-020-02079-2.
31. Singh R, Hartke JN, Catapano JS, et al. Surgical management of Eagle's syndrome causing neurovascular compression. *Clin Neurol Neurosurg.* 2023;226:107596. doi:10.1016/j.clineuro.2023.107596.
32. Jalisi S, Jamal BT, Grillone GA. Surgical management of long-standing Eagle's Syndrome. *Ann Maxillofac Surg.* 2017;7(2):232–236. doi:10.4103/ams.ams\_53\_17.
33. Sukegawa S, Kanno T, Yoshimoto A, et al. Use of an intraoperative navigation system and piezoelectric surgery for styloidectomy in a patient with Eagle's syndrome: a case report. *J Med Case Rep.* 2017;11(1):322. doi:10.1186/s13256-017-1464-3.
34. Aravindan V, Marimuthu M, Krishna VK, Sneha A, Menon V. Extraoral versus intraoral approach for removal of styloid process in treatment of Eagle's syndrome: a report of two cases. *Cureus.* 2023;15(5):e38720. doi:10.7759/cureus.38720.
35. Kumai Y, Hamasaki T, Yumoto E. Surgical management of Eagle's syndrome: an approach to shooting craniofacial pain. *Eur Arch Oto-Rhino-Laryngol.* 2016;273(10):3421–3427. doi:10.1007/s00405-016-4057-7.
36. Cernea CR, Hojaji FC, De Carlucci Jr D, et al. First-bite syndrome after resection of the styloid process. *Laryngoscope.* 2007;117:181–182. doi:10.1097/01.mlg.0000245059.40028.ed.
37. Duarte-Celada W, Jin D, Neves G, Windisch T. Bilateral carotid dissection due to Eagle syndrome in a young female. *eNeurologicalSci.* 2021;24. doi:10.1016/j.ensci.2021.100353.
38. Baldino G, Di Girolamo C, De Blasis G, Gori A. Eagle syndrome and internal carotid artery dissection: description of 5 cases treated in two Italian institutions and review of the literature. *Ann Vasc Surg.* 2020. doi:10.1016/J.AVSG.2020.02.033.
39. Bensoussan Y, Letourneau-Guillon L, Ayad T. Atypical presentation of Eagle syndrome with hypoglossal nerve palsy and Horner syndrome. *Head Neck.* 2014;36(12):E136–E138.
40. Altun D, Çamci E. Bilateral hypoglossal nerve paralysis following elongated styloid process resection: case report. *J Anesth.* 2016;30:1082–1086.
41. Eagle WW. Elongated styloid process; further observations and a new syndrome. *Arch Otolaryngol.* 1948;47(5):630–640. doi:10.1001/archotol.1948.00690030654006.
42. Merola R, Troise S, Palumbo D, D'Auria D, Dell'Aversana Orabona G, Vargas M. Airway management in patients undergoing maxillofacial surgery: state of art review. *J Stomatol Oral Maxillofac Surg.* 2024;126(2):102044. doi:10.1016/j.jormas.2024.102044.