



UNIVERSITÀ  
DEGLI STUDI  
DI UDINE

## Università degli studi di Udine

### News in the classification of WHO 2022 bladder tumors

*Original*

*Availability:*

This version is available <http://hdl.handle.net/11390/1243357> since 2023-03-21T09:17:54Z

*Publisher:*

*Published*

DOI:10.32074/1591-951X-838

*Terms of use:*

The institutional repository of the University of Udine (<http://air.uniud.it>) is provided by ARIC services. The aim is to enable open access to all the world.

*Publisher copyright*

(Article begins on next page)

## News in the classification of WHO 2022 bladder tumors

Maria Rosaria Raspollini<sup>1</sup>, Eva M. Comperat<sup>2</sup>, Antonio Lopez-Beltran<sup>3</sup>, Rodolfo Montironi<sup>4</sup>, Alessia Cimadamore<sup>5</sup>, Toyonori Tsuzuki<sup>6</sup>, George J. Netto<sup>7</sup>

<sup>1</sup> *Histopathology and Molecular Diagnostics, University Hospital Careggi, Florence, Florence, Italy;* <sup>2</sup> *Department of Pathology, Medical University of Vienna, General Hospital of Vienna, Wien, AT, Austria;* <sup>3</sup> *University of Cordoba, Cordoba, Spain;* <sup>4</sup> *Molecular Medicine and Cell Therapy Foundation, Polytechnic University of the Marche Region, Ancona, Italy;* <sup>5</sup> *Section of Pathological Anatomy, School of Medicine, University of Udine, Udine, Italy;* <sup>6</sup> *Department of Surgical Pathology, Aichi Medical University, Aichi, Japan;* <sup>7</sup> *Heersink School of Medicine, The University of Alabama at Birmingham, Birmingham, Alabama, USA*

### Summary

The fifth-edition of World Health Organization (WHO) Classification of Tumors series for urinary and male genital tract tumors has been published, six years later the fourth-edition. In these years, new treatment approaches have been implemented and new molecular data on urological cancers are known.

Morphology remains the groundwork for taxonomy of the urinary tract tumors. However, a molecular approach to classification of urothelial carcinomas and the management of selected neoplasms with new therapeutic modalities such as immunotherapy are emerging. More data are needed for the application of these advances in routine pathology practice and patient management.

The 2022 World Health Organization (WHO) Classification of Tumors of the Urinary System and Male Genital Organs represents an update in classification on urinary tract tumors. It also offers new insights with regards to the grading of heterogeneous non-invasive urothelial neoplasms, the definition of inverted neoplasms, the grading of invasive urothelial carcinomas, the diversity of morphological appearance of urothelial carcinomas, the definition of precursor lesions and the lineage of differentiation of the tumors.

**Key words:** bladder, urothelial tumors, grading, molecular subgroups, WHO 2022

### The grading

The grading of urothelial neoplasms is based on the level of architectural and cytological disorders. Low-grade carcinoma is characterized by lack of marked variation on nuclear size, mild loss of nuclear polarity and mild variation in nuclear size. High-grade carcinoma is characterized by marked architectural and cytologic disorders, loss of polarity, presence of irregular and pleomorphic nuclei, high number of mitoses and anaplasia.

The two-tier distinction between low-grade and high-grade carcinomas was first proposed in the 1998 WHO/ISUP consensus <sup>1</sup> and this has been promulgated by WHO in the third <sup>2</sup> and the fourth <sup>3</sup> edition and maintained in the fifth <sup>4</sup>.

Low-grade and high-grade urothelial carcinomas are characterized by differences in prevalence of genetic alterations. The diagnosis of the two tumor groups (low- and high-grade) allows for correlation with cytological diagnosis using the terminology of the Paris System (TPS) <sup>5</sup>. The TPS, focuses on identification of high-grade tumors, is clinical

Received: December 7, 2022  
Accepted: December 12, 2022

### Correspondence

Maria Rosaria Raspollini  
Histopathology and Molecular Diagnostics  
University Hospital Careggi, 50139 Florence,  
Italy  
Tel.: +39 055 794 9002  
E-mail: mariarosaria.raspollini@unifi.it

**How to cite this article:** Raspollini MR, Comperat EM, Lopez-Beltran A, et al. News in the classification of WHO 2022 bladder tumors. *Pathologica* 2023 Jan 25 [Online ahead of print]. <https://doi.org/10.32074/1591-951X-838>

© Copyright by Società Italiana di Anatomia Patologica e Citopatologia Diagnostica, Divisione Italiana della International Academy of Pathology



OPEN ACCESS

This is an open access journal distributed in accordance with the CC-BY-NC-ND (Creative Commons Attribution-NonCommercial-NoDerivatives 4.0 International) license: the work can be used by mentioning the author and the license, but only for non-commercial purposes and only in the original version. For further information: <https://creativecommons.org/licenses/by-nc-nd/4.0/deed.en>

relevant and has been widely adopted. In addition, the use of low- and high-grade categories has better reproducibility and reduces the interobserver variability and is aligned with current patient management algorithms <sup>6</sup>.

According to the 2022 classification for urinary tract neoplasia, every invasive urothelial carcinoma must be graded <sup>7</sup>. In a substantial percentage of cases, invasive urothelial carcinomas are characterized by high-grade cytological findings. Uncommonly, invasive urothelial carcinomas lacking marked nuclear atypia and architectural disorder – both in exophytic and invasive components – can be encountered. It is important to distinguishing low-grade papillary tumor with lamina propria invasion among the pT1 carcinomas; in fact, literature data show that invasive pT1 low-grade tumors reveal more favorable outcome than pT1 high-grade carcinomas (Fig. 1a, 1b) <sup>8-10</sup>. Hence, clinical management schemes of pT1 urothelial carcinoma patients recognize different risk groups for low vs high-grade invasive carcinomas <sup>11-14</sup>.

It is of note that subtypes of urothelial carcinoma and those with divergent differentiation are all considered high-grade tumors, even subtypes with a bland morphology, such as nested-type or microcystic type urothelial carcinomas <sup>15-18</sup>.

From a pathological point of view, a critical issue is the heterogeneity of grade which occurs in one third of non-invasive papillary urothelial carcinomas, as grading is decisive for selecting the therapeutic approach. The lack of a clear cut-off for the distinguishing low- from high-grade carcinomas has led to variability in application of the criteria and some-

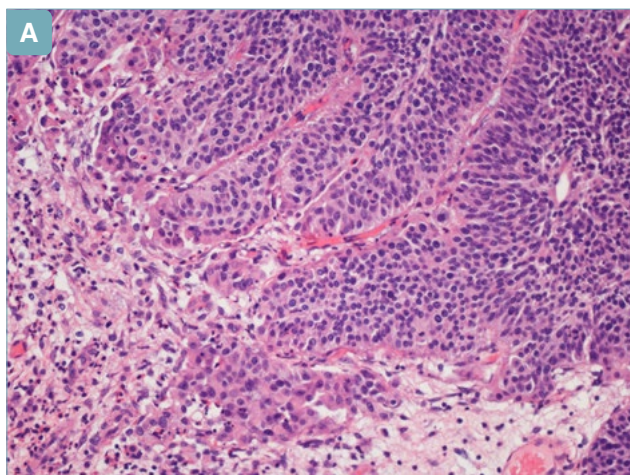
times poor interobserver reproducibility. Different proposals for better stratification of papillary urothelial carcinoma have been forwarded over the last years <sup>19-21</sup>.

The Editorial Board of this fifth edition believes that there is a need to for better interobserver reproducibility for heterogeneous tumors and suggest to adopt common diagnostic criteria as a recent study has described <sup>22</sup>. Therefore, the WHO 2022 blue book propose reporting papillary tumors as high-grade as long as the high-grade component represents 5% or more of the tumor. Moreover, tumors with less than 5% high-grade component should be reported as low-grade with less than 5% high-grade component. This clear approach for reporting, if widely adopted, will help to achieve more interobserver reproducibility and allow for better future correlation with clinical outcomes. In the future, machine learning and artificial intelligence might help pathologists in this regard. Multidisciplinary international collaboration for this issue is suggested.

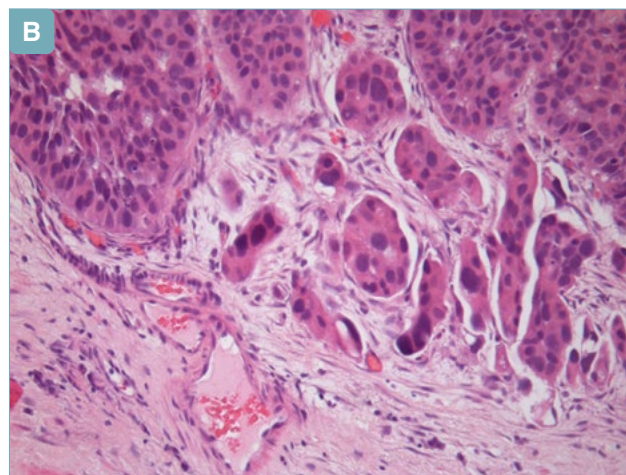
## Non-invasive urothelial lesions

Regarding non invasive papillary neoplasms, the WHO 2022 maintains the papillary urothelial neoplasia of low malignant potential (PUNLMP) which has lower rates of recurrence and progression than pTa LG carcinoma <sup>23,24</sup> as a clinically relevant category, as well as the low-grade, and the high-grade papillary carcinoma categories.

It is important to recognize the inverted pattern of growth and to differentiate it from the invasive lesions.



**Figure 1a.** Papillary urothelial carcinoma, low grade, with a focus of low-grade urothelial carcinoma invading lamina propria.



**Figure 1b.** Papillary urothelial carcinoma, high grade, invading lamina propria.

The reporting of presence of inverted pattern of growth also allows for better correlation with cystoscopic findings. Clarifications criteria for the differential diagnosis for tumors with inverted histology have been itemized. This includes the non-invasive papillary urothelial carcinoma, papillary urothelial neoplasm of low malignant potential and urothelial papilloma groups. While dedicated sections are reserved for uncommon benign lesions such as urothelial papilloma and inverted urothelial papilloma, other inverted lesions (eg. Inverted PUNLMP and inverted low-grade and high-grade non-invasive carcinomas) are included in the sections dedicated to the more common exophytic counterparts<sup>25-28</sup>.

### Subtype of urothelial carcinoma

The terminology of histologic “subtypes” has replaced “variants” throughout the fifth series. Invasive urothelial carcinoma presents with a diversity of morphologic appearances (Figs. 2-9). The different subtypes of urothelial carcinoma can occur in pure forms or more commonly admixed with conventional urothelial carcinoma. There are new subtypes of urothelial carcinoma, such as the tubular urothelial carcinoma, which in pure fashion is characterized by bland cells, arranged in tubular structures, and the large nested urothelial carcinoma<sup>29-30</sup> that has been distinguished from the nested type.

In addition there are refinements of the name *clear cell urothelial carcinoma* with the addition of the term *glycogen rich*<sup>31-32</sup> to clearly discriminate it from clear cell adenocarcinoma with Mullerian differentiation;

and the term *signet ring/diffuse* has been dropped from the plasmacytoid subtype.

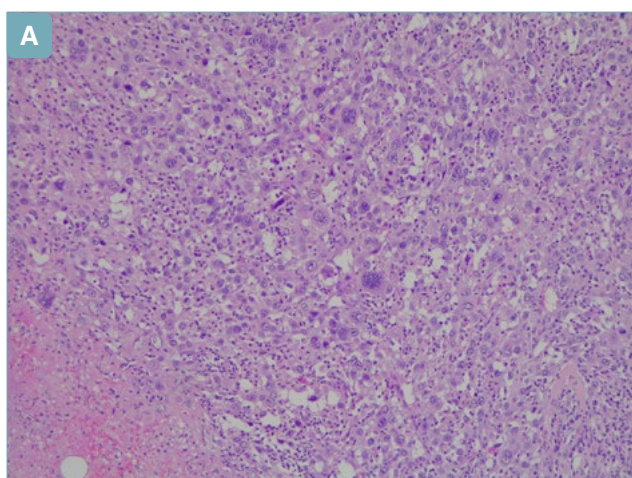
The knowledge of diversity in appearance of urothelial carcinoma with its specific subtypes is important for the recognition of the deceptively benign appearance of some subtypes such as microcystic, tubular, nested and large nested types when in pure form and for the differential diagnosis with non-urothelial tumor with morphological similarities.

Urothelial carcinoma can present areas of divergent differentiation that include glandular, squamous<sup>33</sup>, trophoblastic<sup>34</sup>, Mullerian<sup>35</sup> and even neuroendocrine lineages. The fifth edition underlines the need to report the presence and percentage(s) of the different subtypes and divergent differentiations in urothelial carcinomas which can be useful for patient management<sup>36-38</sup>.

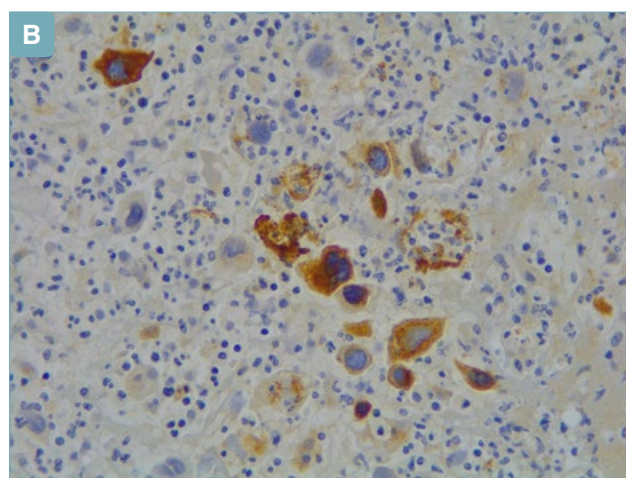
### Precursor lesions

#### UROTHELIAL DYSPLASIA

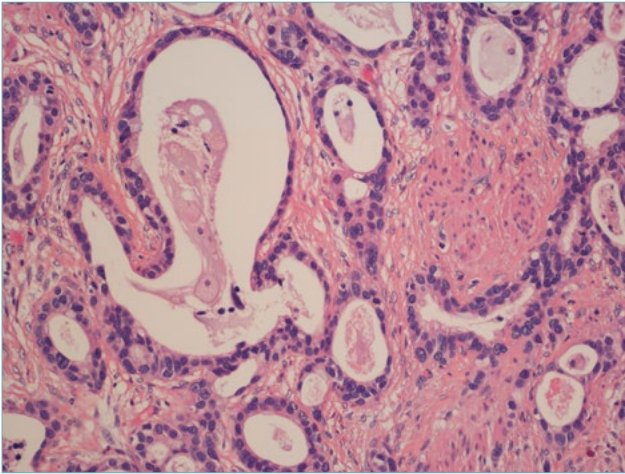
The term dysplasia is controversial, not the least as a result of being based on the absence of criteria for a definite diagnosis of carcinoma in situ (CIS). Dysplasia in the urinary tract does not equate with CIS. The diagnosis of dysplasia consists of a preneoplastic lesion that “*cytologically fall short of the diagnosis of carcinoma in situ*”<sup>39</sup>. The diagnostic term *dysplasia* is maintained in the fifth edition. However, instead of having its own entire chapter, like in the fourth-edition, it turns into a short description in the Urothelial Carcinoma in Situ chapter.



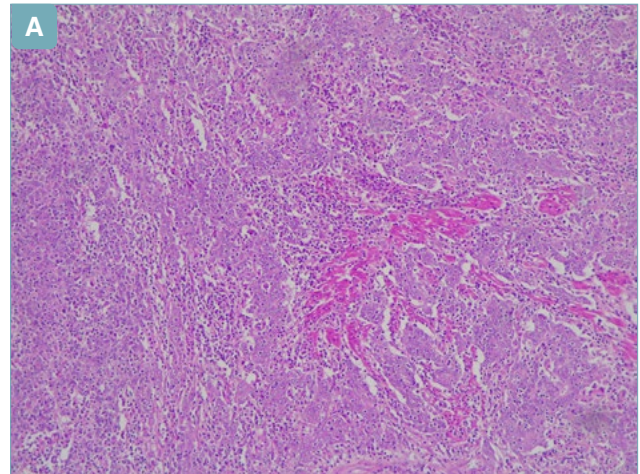
**Figure 2a.** Urothelial carcinoma with trophoblastic differentiation. Tumor with syncytiotrophoblastic cells.



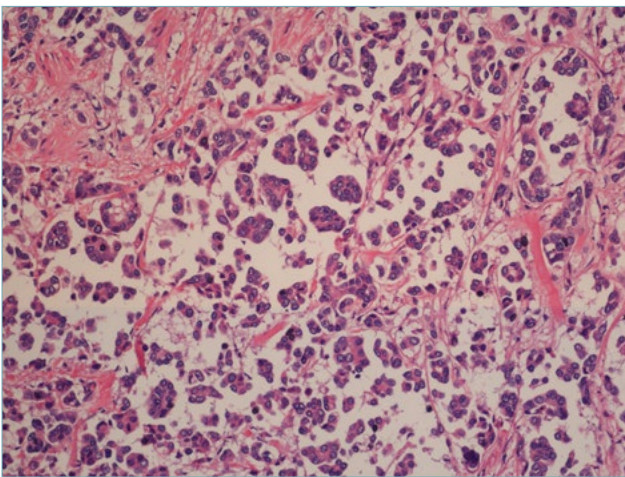
**Figure 2b.** Urothelial carcinoma with trophoblastic differentiation. Beta-hCG stain positive in syncytiotrophoblastic cells.



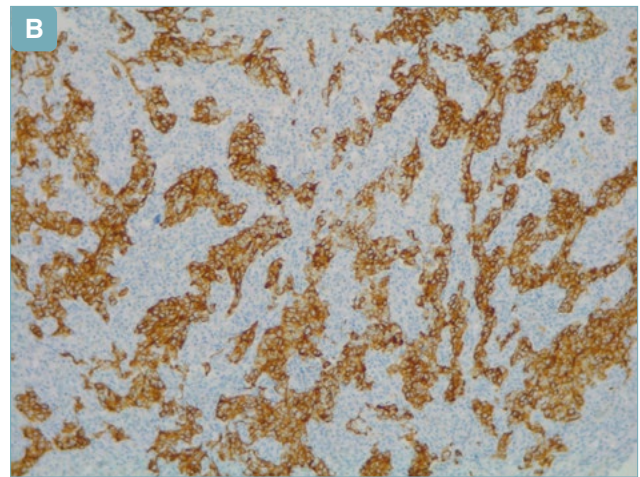
**Figure 3.** Microcystic urothelial carcinoma. Presence of cystic structures infiltrating a non-reactive stroma.



**Figure 5a.** Lymphoepithelioma-like urothelial carcinoma.



**Figure 4.** Micropapillary urothelial carcinoma. Tumor with micropapillary architecture.



**Figure 5b.** Lymphoepithelioma-like urothelial carcinoma. Sheet of CK7 positive cells with a syncytial feature.

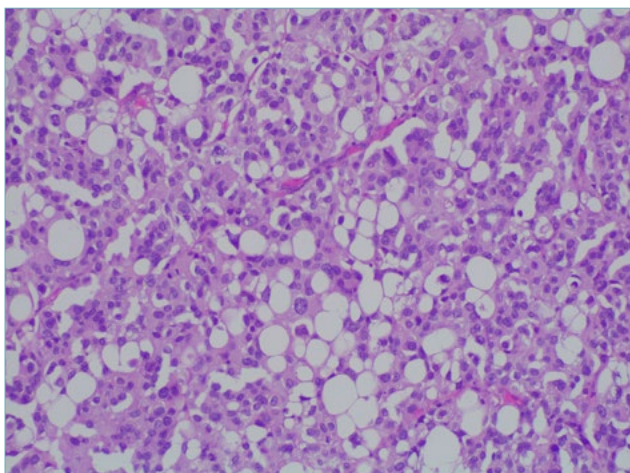
#### UROTHELIAL PAPILLARY PROLIFERATION OF UNDETERMINED MALIGNANT POTENTIAL

In the 2016 edition of the classification for urinary tract neoplasia, undulating urothelial proliferations that were considered like precursors of non-invasive low-grade papillary urothelial carcinoma were termed "urothelial proliferation with undetermined malignant potential". For such lesions, the term atypical urothelial proliferation (AUP) with tented and flat patterns has also been proposed<sup>40</sup>; however, in the 2022 edition, these lesions are no longer recognized as a stand-alone entity and are considered either early noninvasive low-grade papillary carcinomas or extensions of the edge of such tumors.

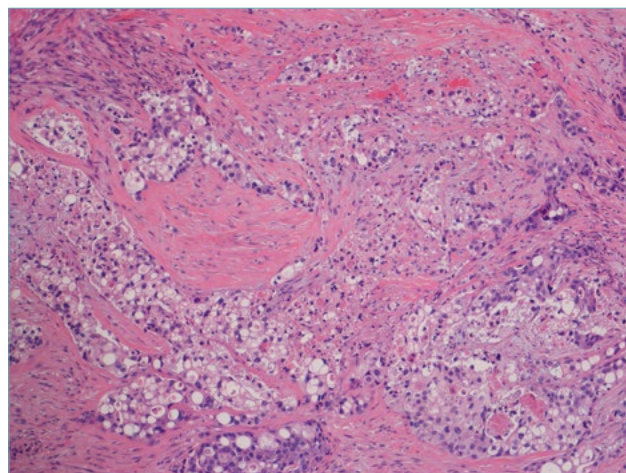
#### Organization of the fifth edition

Each tumor type is described listing benign and malignant entities. Urinary tract neoplasms are now listed in chapters that are mainly organized by tumor lineages of differentiation: urothelial, squamous and glandular tumors. Therefore, there are no longer dedicated organ-based chapters for urothelial tumors of prostate, urethra and upper urinary tract. Exceptions are made for histological findings useful for the diagnosis of rare tumors, such as urachal, diverticular and urethral accessory glands tumors that are described in specific sections.

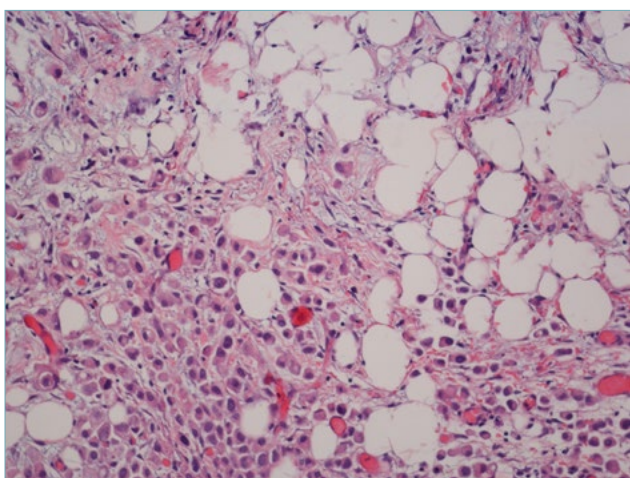
Neuroendocrine neoplasms are described in a ded-



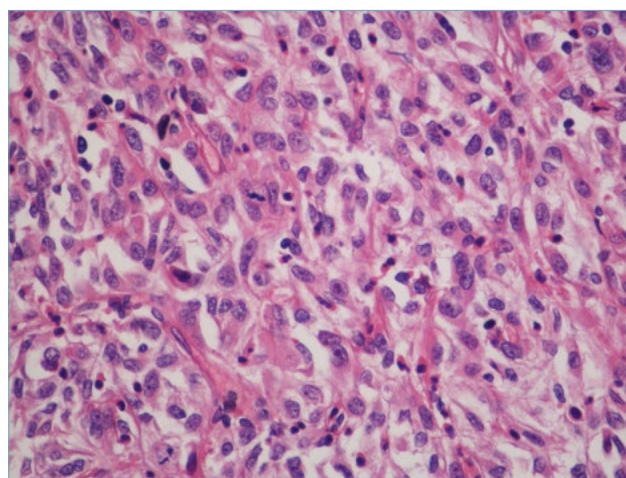
**Figure 6.** Lipid-rich urothelial carcinoma. Tumor cells with a lipoblast-like appearance.



**Figure 8.** Clear cell (glycogen-rich) urothelial carcinoma. Sheet of cells with clear cytoplasm invading the muscle.



**Figure 7.** Plasmacytoid urothelial carcinoma. Dyscohesive and plasmacytoid-appearance tumor cells invading the perivesical fat.



**Figure 9.** Sarcomatoid urothelial carcinoma. Spindle tumor cells with high grade atypia.

icated section. The classification which had been developed at the 2017 International Agency for Research on Cancer (IARC) neuroendocrine neoplasms consensus conference<sup>41</sup> is adopted for genitourinary tract organs as well as for all fifth-edition of World Health Organization (WHO) Classification of tumor series.

Mesenchymal, hematolymphoid, melanocytic and metastatic tumor are also reported in specific chapters. Genetic syndromes relevant for urinary tract tumors are described in the chapter on Genetic tumor syndromes of the urinary and male genital tract.

## Unsolved matters

There remains some unsolved matters in bladder and urinary tract pathology in fifth-edition, such as the sub-staging for pT1 tumors and the molecular classification for urothelial carcinoma.

### SUBSTAGING FOR pT1 TUMORS

Bladder cancer is staged using the TNM system<sup>42-45</sup>. The depth of tumor invasion into bladder wall and adjacent structures defines the pT categories. Tumor stage represents one of the most important factors for prognosis and management in bladder cancer pa-

tients. An unresolved matter is the substaging for pT1 HG urothelial carcinoma although there is agreement on the prognostic value of the depth of lamina propria invasion<sup>46-47</sup>. The fragmented nature of transurethral resection specimens and lack of orientation cause difficulties in the assessment of depth of lamina propria invasion. Histoanatomical and micrometric based systems have been proposed for substaging<sup>48-56</sup>. Using a histoanatomical approach, the pT1 substage is evaluated according to tumor invasion within or beyond the muscularis mucosae or the large vessels of the lamina propria. The micrometric approach is based on the actual measurement of the invasive component. For the latter approach, different cut-offs have been proposed for substaging of invasion in the lamina propria. Despite the variability in the cut-off of micrometric approach and/or the type of approach to be used, the fifth edition strongly suggests to quantify tumor invasion in lamina propria with any of the proposed systems.

#### MOLECULAR FINDINGS

Recent studies on muscle-invasive bladder carcinoma have revealed six molecular subgroups with different prognosis<sup>57-61</sup>. Luminal-papillary subgroups are identified in 24% of muscle-invasive tumors, luminal non-specified in 8%; luminal-unstable in 15%, stromal-rich in 15%, basal-squamous in 35% and neuroendocrine-like in 3% of muscle-invasive bladder carcinoma.

The various gene expression based subgroups are enriched for some histologic features, immune microenvironments and gene signatures. For example, *FGFR3* mutations are more frequent in luminal-papillary subtype, while *TP53* mutations are more likely in neuroendocrine-like, basal-squamous and luminal-unstable.

From a therapeutic point of view, alterations in *ERCC2* and other DNA damage repair genes are have been associated with better response to cisplatin-based chemotherapy<sup>62-63</sup>. Mutation, amplification, and fusion of *FGFR3* can be associated with anti-FGFR agents<sup>64-65</sup>.

Although at the current time it is not possible to go towards a molecular classification of urinary tract tumors, the 2022 blue book highlights the great potential impact of the novel molecular advances for diagnosis and management of urinary tract tumors<sup>66-68</sup>.

#### CONFLICTS OF INTEREST

The authors declare no conflict of interest.

MRR, EMC, TT and GJN served as expert members in 2022 WHO Classification of Tumours Editorial Board. Urinary and male genital tumours.

#### FUNDING

The authors declare no funding.

#### AUTHORS' CONTRIBUTIONS

Writing-original draft preparation, MRR; writing-review and editing, MRR, EMC, ALB, RM, AC, TT, GJN. All authors have read and agreed to the published version of the manuscript.

#### References

- Epstein JI, Amin MB, Reuter VR, et al. The World Health Organization/International Society of Urological Pathology consensus classification of urothelial (transitional cell) neoplasms of the urinary bladder. Bladder Consensus Conference Committee. *Am J Surg Pathol* 1998;22:1435-1448. <https://doi.org/10.1097/0000478-199812000-00001>. PMID: 9850170.
- Eble JN, Sauter G, Epstein J, et al., editors. Pathology and genetics of tumours of the urinary system and male genital organs. Lyon (France): IARC Press 2004. (WHO classification of tumours series, 3rd ed.; vol. 7). <https://publications.iarc.fr/7>.
- Moch H, Humphrey PA, Ulbright TM, et al., eds. WHO classification of tumours of the urinary system and male genital organs. Lyon (France): IARC Press 2016. (WHO classification of tumours series, 4th ed.; vol. 8). <https://publications.iarc.fr/540>.
- WHO Classification of Tumours Editorial Board. Urinary and male genital tumours. Lyon (France): IARC Press 2022 (WHO classification of tumours series, 5th ed.; vol. 8).
- The Paris System (TPS) for reporting cytology. Rosenthal DL, Wojcik EM, Kurtycz DFI, editors. The Paris System for reporting urinary cytology. Cham (Switzerland): Springer International Publishing 2016.
- Sylvester RJ, Rodríguez O, Hernández V, et al. European Association of Urology (EAU) Prognostic Factor Risk Groups for Non-muscle-invasive Bladder Cancer (NMIBC) Incorporating the WHO 2004/2016 and WHO 1973 Classification Systems for Grade: An Update from the EAU NMIBC Guidelines Panel. *Eur Urol* 2021;79:480-488. <https://doi.org/10.1016/j.eururo.2020.12.033>. Epub 2021 Jan 6. PMID: 33419683.
- Amin MB, Smith SC, Reuter VE, et al. Update for the practicing pathologist: the International Consultation On Urologic Disease-European association of urology consultation on bladder cancer. *Mod Pathol* 2015;28:612-630. <https://doi.org/10.1038/modpathol.2014.158>. Epub 2014 Nov 21. PMID: 25412849; PMCID: PMC5009623.
- Pan CC, Chang YH, Chen KK, et al. Constructing prognostic model incorporating the 2004 WHO/ISUP classification for patients with non-muscle-invasive urothelial tumours of the urinary bladder. *J Clin Pathol* 2010;63:910-915. <https://doi.org/10.1136/jcp.2010.079764>. PMID: 20876324.
- Toll AD, Epstein JI. Invasive low-grade papillary urothelial carcinoma: a clinicopathologic analysis of 41 cases. *Am J Surg Pathol* 2012;36:1081-1086. <https://doi.org/10.1097/PAS.0b013e318253d6e0>. PMID: 22510761.
- Holmäng S, Andius P, Hedelin H, et al. Stage progression in Ta papillary urothelial tumors: relationship to grade, immunohistochemical expression of tumor markers, mitotic frequency and DNA ploidy. *J Urol* 2001;165:1124-1128; discussion 1128-30. PMID: 11257652.
- Babjuk M, Burger M, Compérat EM, et al. European Association of Urology Guidelines on Non-muscle-invasive Bladder Cancer (TaT1 and Carcinoma In Situ) - 2019 Update. *Eur Urol*

- 2019;76:639-657. <https://doi.org/10.1016/j.eururo.2019.08.016>. Epub 2019 Aug 20. PMID: 31443960.
- <sup>12</sup> Soukup V, Čapoun O, Cohen D, et al. Risk Stratification Tools and Prognostic Models in Non-muscle-invasive Bladder Cancer: A Critical Assessment from the European Association of Urology Non-muscle-invasive Bladder Cancer Guidelines Panel. *Eur Urol Focus* 2020;6:479-489. <https://doi.org/10.1016/j.euf.2018.11.005>. Epub 2018 Nov 22. PMID: 30470647.
- <sup>13</sup> Chang SS, Boorjian SA, Chou R, et al. Diagnosis and Treatment of Non-Muscle Invasive Bladder Cancer: AUA/SUO Guideline. *J Urol* 2016;196:1021-1029. <https://doi.org/10.1016/j.juro.2016.06.049>. Epub 2016 Jun 16. PMID: 27317986.
- <sup>14</sup> Babjuk M, Burger M, Compérat E, et al. EAU guidelines on non-muscle-invasive bladder cancer (TaT1 and CIS). Arnhem (Netherlands): EAU Guidelines Office; 2021. Available from: <https://uroweb.org/guideline/non-muscle-invasive-bladder-cancer/>.
- <sup>15</sup> Beltran AL, Cheng L, Montironi R, et al. Clinicopathological characteristics and outcome of nested carcinoma of the urinary bladder. *Virchows Arch* 2014;465:199-205. <https://doi.org/10.1007/s00428-014-1601-y>. Epub 2014 May 31. PMID: 24878757.
- <sup>16</sup> Drew PA, Furman J, Civantos F, et al. The nested variant of transitional cell carcinoma: an aggressive neoplasm with innocuous histology. *Mod Pathol* 1996;9:989-994. PMID: 8902836.
- <sup>17</sup> Lopez Beltran A, Montironi R, Cheng L. Microcystic urothelial carcinoma: morphology, immunohistochemistry and clinical behaviour. *Histopathology* 2014;64:872-879. <https://doi.org/10.1111/his.12345>. Epub 2014 Feb 5. PMID: 24321001.
- <sup>18</sup> Veskimäe E, Espinos EL, Bruins HM, et al. What Is the Prognostic and Clinical Importance of Urothelial and Nonurothelial Histological Variants of Bladder Cancer in Predicting Oncological Outcomes in Patients with Muscle-invasive and Metastatic Bladder Cancer? A European Association of Urology Muscle Invasive and Metastatic Bladder Cancer Guidelines Panel Systematic Review. *Eur Urol Oncol* 2019;2:625-642. <https://doi.org/10.1016/j.euo.2019.09.003>. Epub 2019 Oct 8. PMID: 31601522.
- <sup>19</sup> Cheng L, Neumann RM, Nehra A, et al. Cancer heterogeneity and its biologic implications in the grading of urothelial carcinoma. *Cancer* 2000;88:1663-1670. [https://doi.org/10.1002/\(sici\)1097-0142\(20000401\)88:7<1663::aid-cnrcr21>3.0.co;2-8](https://doi.org/10.1002/(sici)1097-0142(20000401)88:7<1663::aid-cnrcr21>3.0.co;2-8). PMID: 10738225.
- <sup>20</sup> Gofrit ON, Pizov G, Shapiro A, et al. Mixed high and low grade bladder tumors--are they clinically high or low grade? *J Urol* 2014;191:1693-1696. <https://doi.org/10.1016/j.juro.2013.11.056>. Epub 2013 Dec 5. PMID: 24316096.
- <sup>21</sup> Schubert T, Danzig MR, Kotamarti S, et al. Mixed low- and high-grade non-muscle-invasive bladder cancer: a histological subtype with favorable outcome. *World J Urol* 2015;33:847-852. <https://doi.org/10.1007/s00345-014-1383-5>. Epub 2014 Aug 23. PMID: 25149472.
- <sup>22</sup> Reis LO, Taheri D, Chaux A, et al. Significance of a minor high-grade component in a low-grade noninvasive papillary urothelial carcinoma of bladder. *Hum Pathol* 2016;47:20-25. <https://doi.org/10.1016/j.humpath.2015.09.007>. Epub 2015 Sep 25. PMID: 26520419.
- <sup>23</sup> Holmäng S, Hedelin H, Anderström C, et al. Recurrence and progression in low grade papillary urothelial tumors. *J Urol* 1999;162(3 Pt 1):702-707. <https://doi.org/10.1097/00005392-199909010-00019>. PMID: 10458347.
- <sup>24</sup> Holmäng S, Andius P, Hedelin H, et al. Stage progression in Ta papillary urothelial tumors: relationship to grade, immunohistochemical expression of tumor markers, mitotic frequency and DNA ploidy. *J Urol* 2001;165:1124-1128; discussion 1128-30. PMID: 11257652.
- <sup>25</sup> Amin MB, Gómez JA, Young RH. Urothelial transitional cell carcinoma with endophytic growth patterns: a discussion of patterns of invasion and problems associated with assessment of invasion in 18 cases. *Am J Surg Pathol* 1997;21:1057-1068. <https://doi.org/10.1097/0000478-199709000-00010>. PMID: 9298882.
- <sup>26</sup> Hodges KB, Lopez-Beltran A, Maclennan GT, et al. Urothelial lesions with inverted growth patterns: histogenesis, molecular genetic findings, differential diagnosis and clinical management. *BJU Int* 2011;107:532-537. <https://doi.org/10.1111/j.1464-410X.2010.09853.x>. Epub 2010 Nov 23. PMID: 21091975.
- <sup>27</sup> Amin MB, Smith SC, Reuter VE, et al. Update for the practicing pathologist: The International Consultation On Urologic Disease-European association of urology consultation on bladder cancer. *Mod Pathol* 2015;28:612-630. <https://doi.org/10.1038/modpathol.2014.158>. Epub 2014 Nov 21. PMID: 25412849; PMCID: PMC5009623.
- <sup>28</sup> Guo A, Liu A, Teng X. The pathology of urinary bladder lesions with an inverted growth pattern. *Chin J Cancer Res* 2016;28:107-121. <https://doi.org/10.3978/j.issn.1000-9604.2016.02.01>. PMID: 27041933; PMCID: PMC4779755.
- <sup>29</sup> Compérat E, McKenney JK, Hartmann A, et al. Large nested variant of urothelial carcinoma: a clinicopathological study of 36 cases. *Histopathology* 2017;71:703-710. <https://doi.org/10.1111/his.13280>. Epub 2017 Aug 14. PMID: 28805264.
- <sup>30</sup> Cox R, Epstein JI. Large nested variant of urothelial carcinoma: 23 cases mimicking von Brunn nests and inverted growth pattern of noninvasive papillary urothelial carcinoma. *Am J Surg Pathol* 2011;35:1337-1342. <https://doi.org/10.1097/PAS.0b013e318222a653>. PMID: 21836490.
- <sup>31</sup> Zhou Z, Kinslow CJ, Wang P, et al. Clear Cell Adenocarcinoma of the Urinary Bladder Is a Glycogen-Rich Tumor with Poorer Prognosis. *J Clin Med* 2020;9:138. <https://doi.org/10.3390/jcm9010138>. PMID: 31947882; PMCID: PMC7019566.
- <sup>32</sup> Chan EO, Chan VW, Poon JY, et al. Clear cell carcinoma of the urinary bladder: a systematic review. *Int Urol Nephrol* 2021;53:815-824. <https://doi.org/10.1007/s11255-020-02725-2>. Epub 2021 Jan 18. PMID: 33462714.
- <sup>33</sup> Kim SP, Frank I, Cheville JC, et al. The impact of squamous and glandular differentiation on survival after radical cystectomy for urothelial carcinoma. *J Urol* 2012;188:405-409. <https://doi.org/10.1016/j.juro.2012.04.020>. Epub 2012 Jun 14. PMID: 22704101.
- <sup>34</sup> Przybycin CG, McKenney JK, Nguyen JK, et al. Urothelial Carcinomas With Trophoblastic Differentiation, Including Choriocarcinoma: Clinicopathologic Series of 16 Cases. *Am J Surg Pathol* 2020;44:1322-1330. <https://doi.org/10.1097/PAS.0000000000001532>. PMID: 32931680.
- <sup>35</sup> Herawi M, Drew PA, Pan CC, et al. Clear cell adenocarcinoma of the bladder and urethra: cases diffusely mimicking nephrogenic adenoma. *Hum Pathol* 2010;41:594-601. <https://doi.org/10.1016/j.humpath.2009.10.011>. Epub 2010 Jan 8. PMID: 20060152.
- <sup>36</sup> Takahara T, Murase Y, Tsuzuki T. Urothelial carcinoma: variant histology, molecular subtyping, and immunophenotyping significant for treatment outcomes. *Pathology* 2021;53:56-66. <https://doi.org/10.1016/j.pathol.2020.09.004>. Epub 2020 Oct 16. PMID: 33070956.
- <sup>37</sup> Mori K, Abufaraj M, Mostafaehi H, et al. A Systematic Review and Meta-Analysis of Variant Histology in Urothelial Carcinoma of the Bladder Treated with Radical Cystectomy. *J Urol* 2020;204:1129-1140. <https://doi.org/10.1097/JU.0000000000001305>. Epub 2020 Jul 27. PMID: 32716694.
- <sup>38</sup> Moschini M, D'Andrea D, Korn S, et al. Characteristics and clinical significance of histological variants of bladder cancer. *Nat Rev Urol* 2017;14:651-668. <https://doi.org/10.1038/nrurol.2017.125>. Epub 2017 Sep 12. PMID: 28895563.



- <sup>39</sup> McKenney JK. Precursor lesions of the urinary bladder. *Histopathology* 2019;74:68-76. <https://doi.org/10.1111/his.13762>. PMID: 30565304.
- <sup>40</sup> Amin MB, Comperat E, Epstein JI, et al. The Genitourinary Pathology Society Update on Classification and Grading of Flat and Papillary Urothelial Neoplasia With New Reporting Recommendations and Approach to Lesions With Mixed and Early Patterns of Neoplasia. *Adv Anat Pathol* 2021;28:179-195. <https://doi.org/10.1097/PAP.000000000000308>. PMID: 34128483.
- <sup>41</sup> Rindi G, Klimstra DS, Abedi-Ardekani B, et al. A common classification framework for neuroendocrine neoplasms: an International Agency for Research on Cancer (IARC) and World Health Organization (WHO) expert consensus proposal. *Mod Pathol* 2018;31:1770-1786. <https://doi.org/10.1038/s41379-018-0110-y>. Epub 2018 Aug 23. PMID: 30140036; PMCID: PMC6265262.
- <sup>42</sup> Paner GP, Stadler WM, Hansel DE, et al. Updates in the Eighth Edition of the Tumor-Node-Metastasis Staging Classification for Urologic Cancers. *Eur Urol* 2018;73:560-569. <https://doi.org/10.1016/j.eururo.2017.12.018>. Epub 2018 Jan 9. PMID: 29325693.
- <sup>43</sup> Paner GP, Montironi R, Amin MB. Challenges in Pathologic Staging of Bladder Cancer: Proposals for Fresh Approaches of Assessing Pathologic Stage in Light of Recent Studies and Observations Pertaining to Bladder Histoanatomic Variances. *Adv Anat Pathol* 2017;24:113-127. <https://doi.org/10.1097/PAP.0000000000000152>. PMID: 28398951.
- <sup>44</sup> Magers MJ, Lopez-Beltran A, Montironi R, et al. Staging of bladder cancer. *Histopathology* 2019;74:112-134. <https://doi.org/10.1111/his.13734>. PMID: 30565300.
- <sup>45</sup> Gallan AJ, Choy B, Paner GP. Contemporary Grading and Staging of Urothelial Neoplasms of the Urinary Bladder: New Concepts and Approaches to Challenging Scenarios. *Surg Pathol Clin* 2018;11:775-795. <https://doi.org/10.1016/j.path.2018.07.006>. PMID: 30447841.
- <sup>46</sup> Kardoust Parizi M, Enikeev D, Glybochko PV, et al. Prognostic value of T1 substaging on oncological outcomes in patients with non-muscle-invasive bladder urothelial carcinoma: a systematic literature review and meta-analysis. *World J Urol* 2020;38:1437-1449. <https://doi.org/10.1007/s00345-019-02936-y>. Epub 2019 Sep 6. PMID: 31493109; PMCID: PMC7245585.
- <sup>47</sup> Lawless M, Gulati R, Tretiakova M. Stalk versus base invasion in pT1 papillary cancers of the bladder: improved substaging system predicting the risk of progression. *Histopathology* 2017;71:406-414. <https://doi.org/10.1111/his.13247>. Epub 2017 Jun 27. PMID: 28470753; PMCID: PMC5552491.
- <sup>48</sup> Raspollini MR, Montironi R, Mazzucchelli R, et al. pT1 high-grade bladder cancer: histologic criteria, pitfalls in the assessment of invasion, and substaging. *Virchows Arch* 2020;477:3-16. <https://doi.org/10.1007/s00428-020-02808-6>. Epub 2020 Apr 15. PMID: 32296929.
- <sup>49</sup> Colombo R, Hurler R, Moschini M, et al. Feasibility and Clinical Roles of Different Substaging Systems at First and Second Transurethral Resection in Patients with T1 High-Grade Bladder Cancer. *Eur Urol Focus* 2018;4:87-93. <https://doi.org/10.1016/j.euf.2016.06.004>. Epub 2016 Jun 15. PMID: 28753746.
- <sup>50</sup> Fransen van de Putte EE, Otto W, Hartmann A, et al. Metric substaging according to micro and extensive lamina propria invasion improves prognostics in T1 bladder cancer. *Urol Oncol* 2018;36:361.e7-361.e13. <https://doi.org/10.1016/j.urolonc.2018.05.007>. Epub 2018 Jun 5. PMID: 29880460.
- <sup>51</sup> Chang WC, Chang YH, Pan CC. Prognostic significance in substaging of T1 urinary bladder urothelial carcinoma on transurethral resection. *Am J Surg Pathol* 2012;36:454-461. <https://doi.org/10.1097/PAS.0b013e31823dafd3>. PMID: 22261706.
- <sup>52</sup> van Rhijn BW, van der Kwast TH, Alkhateeb SS, et al. A new and highly prognostic system to discern T1 bladder cancer substage. *Eur Urol* 2012;61:378-384. <https://doi.org/10.1016/j.eururo.2011.10.026>. Epub 2011 Oct 25. PMID: 22036775.
- <sup>53</sup> Hu Z, Mudaliar K, Quek ML, et al. Measuring the dimension of invasive component in pT1 urothelial carcinoma in transurethral resection specimens can predict time to recurrence. *Ann Diagn Pathol* 2014;18:49-52. <https://doi.org/10.1016/j.anndiagpath.2013.11.002>. Epub 2013 Nov 20. PMID: 24370460.
- <sup>54</sup> Bertz S, Denzinger S, Otto W, et al. Substaging by estimating the size of invasive tumour can improve risk stratification in pT1 urothelial bladder cancer-evaluation of a large hospital-based single-centre series. *Histopathology* 2011;59:722-732. <https://doi.org/10.1111/j.1365-2559.2011.03989.x>. PMID: 22014053.
- <sup>55</sup> Leivo MZ, Sahoo D, Hamilton Z, et al. Analysis of T1 Bladder Cancer on Biopsy and Transurethral Resection Specimens: Comparison and Ranking of T1 Quantification Approaches to Predict Progression to Muscularis Propria Invasion. *Am J Surg Pathol* 2018;42:e1-e10. <https://doi.org/10.1097/PAS.0000000000000964>. PMID: 29076872.
- <sup>56</sup> Paner GP, Montironi R, Amin MB. Challenges in Pathologic Staging of Bladder Cancer: Proposals for Fresh Approaches of Assessing Pathologic Stage in Light of Recent Studies and Observations Pertaining to Bladder Histoanatomic Variances. *Adv Anat Pathol* 2017;24:113-127. <https://doi.org/10.1097/PAP.0000000000000152>. PMID: 28398951.
- <sup>57</sup> Kamoun A, de Reyniès A, Allory Y, et al. A Consensus Molecular Classification of Muscle-Invasive Bladder Cancer. *Eur Urol* 2020;77:420-433. <https://doi.org/10.1016/j.eururo.2019.09.006>. Epub 2019 Sep 26. PMID: 31563503; PMCID: PMC7690647.
- <sup>58</sup> Sjö Dahl G, Lövgren K, Lauss M, et al. Toward a molecular pathologic classification of urothelial carcinoma. *Am J Pathol* 2013;183:681-691. <https://doi.org/10.1016/j.ajpath.2013.05.013>. Epub 2013 Jul 1. PMID: 23827819.
- <sup>59</sup> Choi W, Porten S, Kim S, et al. Identification of distinct basal and luminal subtypes of muscle-invasive bladder cancer with different sensitivities to frontline chemotherapy. *Cancer Cell* 2014;25:152-165. <https://doi.org/10.1016/j.ccr.2014.01.009>. PMID: 24525232; PMCID: PMC4011497.
- <sup>60</sup> Robertson AG, Kim J, Al-Ahmadie H, et al. Comprehensive Molecular Characterization of Muscle-Invasive Bladder Cancer. *Cell* 2017;171:540-556.e25. <https://doi.org/10.1016/j.cell.2017.09.007>. Epub 2017 Oct 5. Erratum in: *Cell* 2018;174:1033. PMID: 28988769; PMCID: PMC5687509.
- <sup>61</sup> Mo Q, Nikolos F, Chen F, et al. Prognostic Power of a Tumor Differentiation Gene Signature for Bladder Urothelial Carcinomas. *J Natl Cancer Inst* 2018;110:448-459. <https://doi.org/10.1093/jnci/djx243>. Erratum in: *J Natl Cancer Inst* 2019;111(11):1236. PMID: 29342309; PMCID: PMC6279371.
- <sup>62</sup> Van Allen EM, Mouw KW, Kim P, et al. Somatic ERCC2 mutations correlate with cisplatin sensitivity in muscle-invasive urothelial carcinoma. *Cancer Discov* 2014;4:1140-1153. <https://doi.org/10.1158/2159-8290.CD-14-0623>. Epub 2014 Aug 5. PMID: 25096233; PMCID: PMC4238969.
- <sup>63</sup> Iyer G, Balar AV, Milowsky MI, et al. Multicenter Prospective Phase II Trial of Neoadjuvant Dose-Dense Gemcitabine Plus Cisplatin in Patients With Muscle-Invasive Bladder Cancer. *J Clin Oncol* 2018;36:1949-1956. <https://doi.org/10.1200/JCO.2017.75.0158>. Epub 2018 May 9. PMID: 29742009; PMCID: PMC6049398.
- <sup>64</sup> Pal SK, Rosenberg JE, Hoffman-Censits JH, et al. Efficacy of BGJ398, a Fibroblast Growth Factor Receptor 1-3 Inhibitor, in Patients with Previously Treated Advanced Urothelial Carcinoma with *FGFR3* Alterations. *Cancer Discov* 2018;8:812-821. <https://doi.org/10.1158/2159-8290.CD-18-0229>. Epub 2018 May 30. PMID: 29848605; PMCID: PMC6716598.

- <sup>65</sup> Lorient Y, Necchi A, Park SH, et al. Erdafitinib in Locally Advanced or Metastatic Urothelial Carcinoma. *N Engl J Med* 2019;381:338-348. <https://doi.org/10.1056/NEJMoa1817323>. PMID: 31340094.
- <sup>66</sup> Hodgson A, Slodkowska E, Jungbluth A, et al. PD-L1 Immunohistochemistry Assay Concordance in Urothelial Carcinoma of the Bladder and Hypopharyngeal Squamous Cell Carcinoma. *Am J Surg Pathol* 2018;42:1059-1066. <https://doi.org/10.1097/PAS.0000000000001084>. PMID: 29750666; PMCID: PMC6750743.
- <sup>67</sup> Tretiakova M, Fulton R, Kocherginsky M, et al. Concordance study of PD-L1 expression in primary and metastatic bladder carcinomas: comparison of four commonly used antibodies and RNA expression. *Mod Pathol* 2018;31:623-632. <https://doi.org/10.1038/modpathol.2017.188>. Epub 2017 Dec 22. PMID: 29271413.
- <sup>68</sup> Reis H, Serrette R, Posada J, et al. PD-L1 Expression in Urothelial Carcinoma With Predominant or Pure Variant Histology: Concordance Among 3 Commonly Used and Commercially Available Antibodies. *Am J Surg Pathol* 2019;43:920-927. <https://doi.org/10.1097/PAS.0000000000001264>. PMID: 31135485; PMCID: PMC6561805.