

*Systematic Review*

# Update of Laparoscopic Surgery in Borderline Ovarian Tumor: Systematic Review

Isabella Rotondella<sup>1,†</sup>, Elisa Scarpelli<sup>1,†</sup>, Giulia Martignon<sup>1,\*</sup>, Davide Scebba<sup>1</sup>, Luciano Monfardini<sup>1</sup>, Michela Gaiano<sup>1</sup>, Alessandra De Finis<sup>1</sup>, Martina Leotta<sup>1</sup>, Carlotta Montrucchio<sup>1</sup>, Asya Gallinelli<sup>1</sup>, Stefano Cianci<sup>2</sup>, Stefano Restaino<sup>3</sup>, Giuseppe Vizzielli<sup>3,4</sup>, Vito Andrea Capozzi<sup>1</sup>

<sup>1</sup>Department of Medicine and Surgery, University Hospital of Parma, 43125 Parma, Italy

<sup>2</sup>Department of Medicine and Surgery, University Hospital of Messina, 98125 Messina, Italy

<sup>3</sup>Clinic of Obstetrics and Gynecology, “Santa Maria della Misericordia” University Hospital, Azienda Sanitaria Universitaria Friuli Centrale, 33100 Udine, Italy

<sup>4</sup>Department of Medicine, University of Udine, 33100 Udine, Italy

\*Correspondence: [giulia.martignon@unipr.it](mailto:giulia.martignon@unipr.it) (Giulia Martignon)

†These authors contributed equally.

Academic Editors: Valerio Gaetano Vellone and Michael H. Dahan

Submitted: 5 August 2023 Revised: 20 September 2023 Accepted: 27 September 2023 Published: 29 December 2023

## Abstract

**Background:** Borderline ovarian tumor (BOT) predominantly affects young women and is often diagnosed at an early stage. BOT accounts for 15% of all epithelial tumors. In this regard, a minimally invasive surgical approach and the ability to preserve fertility, without increasing the incidence of recurrences or worsening the prognosis, are crucial. This review aims to provide an update on the role and indications of laparoscopic surgery in BOTs. **Methods:** The electronic research was performed on Pubmed, Medline, and Embase. Articles published in the last 20 years (2004–2023) were included, and the following keywords were used: ‘borderline ovarian tumor’ and ‘laparoscopic surgery’, ‘borderline ovarian tumor’ and ‘minimally invasive surgery’, ‘borderline ovarian tumor’ and ‘fertility sparing’, ‘borderline ovarian tumor’ and ‘recurrence’ and ‘Borderline ovarian tumor’ and ‘relapse’. The agreement about potential relevance was reached by consensus of the researchers and according to PRISMA statement guidelines. We thoroughly reviewed all bibliographies to assess the inclusion of any further eligible studies. We excluded studies that did not align with the study’s objectives. **Results:** The electronic database search yielded 767 total studies. Of whom, 188 were published before 2004, 84 were case reports, and 45 were not in the English language. Of the remaining 450 studies, 148 were considered eligible for the study. We included 20 studies in this review. **Conclusions:** Despite the latest guidelines recommending an open approach for the treatment of BOT, the laparoscopic approach has gained popularity as a feasible and safe alternative. The use of an endo-bag, along with advanced laparoscopic skills, has made the minimally invasive approach increasingly safe, with oncological outcomes almost comparable to those of reference. Moreover, in the context of fertility-sparing surgery (FSS), laparoscopy seems to be associated with improved obstetrical outcomes, without detrimental effects on overall survival and disease-free survival. Therefore, the laparoscopic approach in the treatment of BOT appears to be a safe and effective option, especially in the case of FSS.

**Keywords:** laparoscopic surgery; gynecologic oncology; borderline ovarian tumor; fertility-sparing

## 1. Introduction

Borderline ovarian tumors (BOTs) are a group of epithelial tumors characterized by uncontrolled hyperproliferation, and mild nuclear atypia without stromal invasion [1]. BOT accounts for 15% of all epithelial tumors and it can be diagnosed as an adnexal mass with aspecific symptoms (dyspareunia, abdominal pain, or abdominal swelling), or incidentally during routine gynecological examinations. The ultrasound findings should be accompanied by serum tumor markers (usually elevated but non-specific) [2]. BOT can be associated with stromal micro invasion, intraepithelial carcinoma, and non-invasive peritoneal implants. Nevertheless, BOTs are mostly limited to the ovaries at the time of diagnosis with the International

Federation of Gynecology and Obstetrics (FIGO) stage I or II (75% stage I). They have a good prognosis with a 5–10 year overall survival (OS) rate of 95–97%, and surgery is curative [3–5].

Histologically, we can distinguish six subtypes: serous (50%), mucinous (45%), and less common types including endometrioid, clear cell, seromucinous, and Brenner borderline tumor [6].

As stated by the European Society for Medical Oncology (ESMO) and European Society of Gynaecological Oncology (ESGO) 2019 guidelines, the treatment consists of ipsilateral salpingo-oophorectomy, and peritoneal staging after careful exploration of the peritoneal cavity to detect potentially suspicious implants. Peritoneal surgical staging



is based on peritoneal washing, peritoneal biopsies (pelvic peritoneum, paracolic gutters, diaphragm), and omentectomy (at least infracolic) [7–9].

The recommended surgical approach is laparotomy (LPT) since it allows better macroscopic visualization and lower risk of cyst rupture during dissection, which would negatively impact FIGO staging, compared to minimally invasive surgery (MIS) [7,10–12].

Nowadays, with the advent of accurate and innovative instrumentation, MIS in expert hands has taken more widespread in surgical BOT treatment [13,14]. Since BOT often occurs in young patients [15], both minimally invasive surgical approaches and fertility-sparing surgery (FSS) are essential aspects to reduce postoperative complications and preserve childbearing desire. Several studies report excellent long-term survival rates among stage I patients treated with conservative surgery. This underscores the safety and efficacy of fertility-sparing and ultra-fertility-sparing procedures, which involve either unilateral salpingo-oophorectomy or cystectomy, respectively [16–18]. However, several concerns are still unresolved in the BOT treatment. When to perform fertility-sparing *vs.* ultra fertility-sparing surgery, the risk of intraoperative cyst rupture, or which adnexal mass sizes can be treated laparoscopically remain open questions [19–21].

In this manuscript, a systematic review of the literature of the last 20 years regarding the minimally invasive laparoscopic approach in BOT was performed.

We evaluated tumor diameter, cyst rupture, fertility-sparing approach, pregnancy rate, and oncological outcome in terms of recurrence rate, disease-free survival (DFS), and OS in patients treated by laparoscopy *vs.* open laparotomy.

## 2. Materials and Methods

From May to July 2023, an electronic research was performed on Pubmed, Medline, and Embase. For study purposes, articles published in the last 20 years (2004–2023) were included and the following keywords were used: ‘borderline ovarian tumor’ and ‘laparoscopic surgery’, ‘borderline ovarian tumor’ and ‘minimally invasive surgery’, ‘borderline ovarian tumor’ and ‘fertility sparing’, ‘Borderline ovarian tumor’ and ‘recurrent’ and ‘Borderline ovarian tumor’ and ‘relapse’.

The consensus on potential relevance was achieved through the collective agreement of the researchers and according to PRISMA statement guidelines (see Fig. 1) [22]. Two double-blind authors (IR and GM) read all abstracts. After the initial selection, the researchers assessed the complete texts of the chosen papers and independently extracted pertinent data concerning study design and outcomes. The present review encompasses systematic reviews, meta-analyses, clinical trials, and original articles. Studies deemed incompatible with the study’s objectives, case reports and duplicate studies were excluded. More-

over, only articles written in English were included.

All references were examined to assess the inclusion of any additional eligible studies. Redundant studies were excluded from the analysis. In the case of doubtful articles, further opinion was asked to a third author (VAC).

## 3. Results

The electronic database search yielded 767 total studies. Of whom, 188 were published before 2004, 84 were case reports, and 45 were not in the English language. Of the remaining 450 studies, 148 met the eligibility criteria for the study. One-hundred-twenty-eight studies not fitting the review scope were excluded. The studies’ selection flow-chart is shown in Fig. 1.

We included 20 studies in this review: 8 studies concerning laparoscopic and laparotomic approach and risk of cyst rupture (Table 1, Ref. [13,19–21,23–26]); 6 studies concerning laparoscopic and laparotomic surgery and FSS (Table 2, Ref. [27–32]); 6 studies concerning laparoscopic and laparotomic approach and oncological risk of recurrence (Table 3, Ref. [33–38]).

To better illustrate the results of the research and describe scientific evidence about laparoscopy and BOT surgical treatment, the main findings are reported in chapters: tumor diameter, cyst rupture and surgical approach; laparoscopic approach in fertility sparing surgery; oncological outcomes and surgical approach.

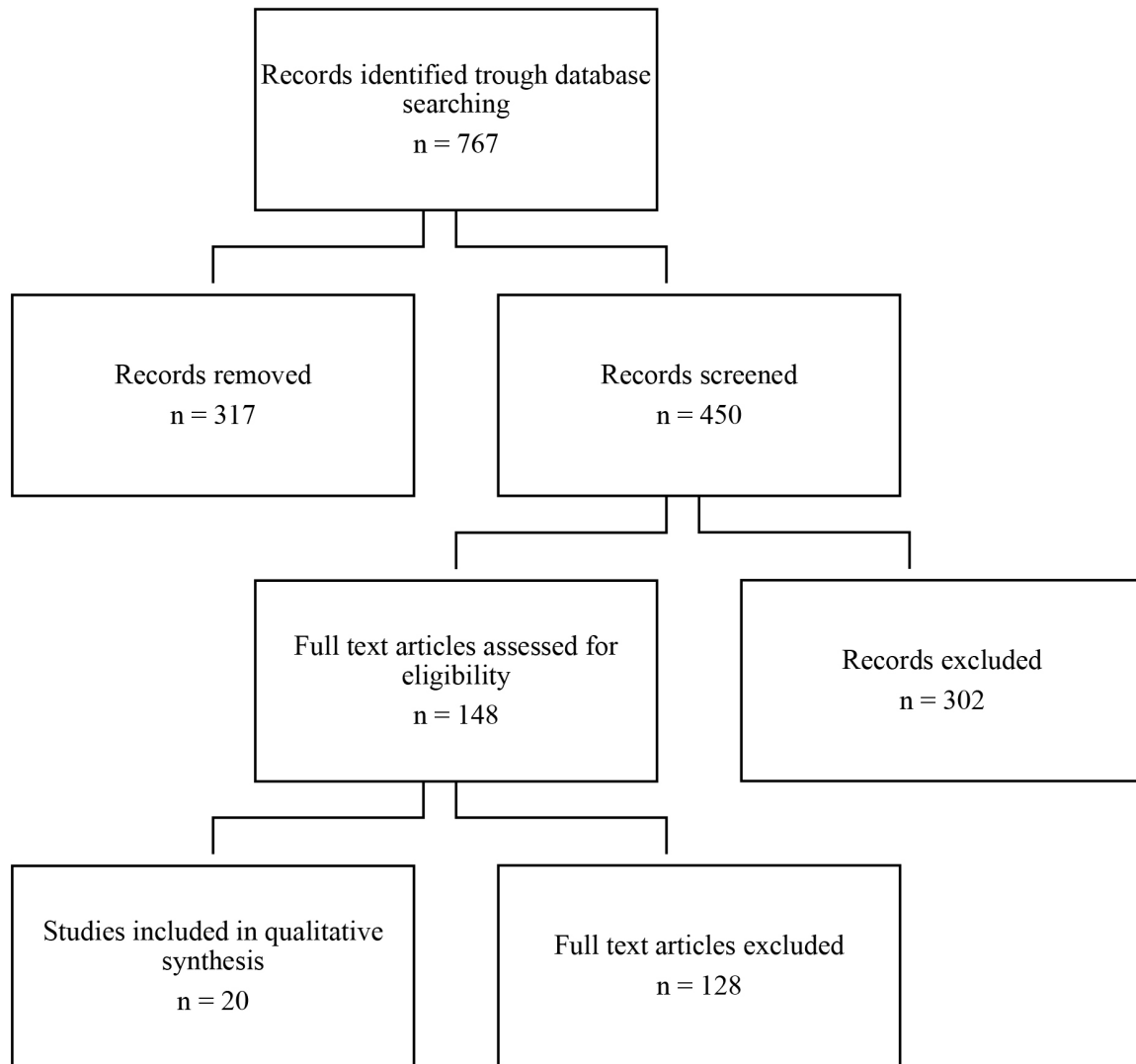
## 4. Discussion

### 4.1 Tumor Diameter, Cyst Rupture and Surgical Approach

Cyst diameter is crucial in surgical approach selection. The risk of cyst rupture during the procedure and the inherent difficulty in its extraction may limit the use of MIS. Undoubtedly, the use of endo-bag for tumor extraction is mandatory, since port-site metastasis occurrence is reported also in the case of BOT [39].

In any case, there is no real established cut-off for opting for open surgery *vs.* laparoscopy. In 2004 Maneo *et al.* [13] conducted a retrospective study on 62 patients with BOT. The authors found that a tumor diameter larger than 5 cm in the laparoscopy group was associated with a higher risk of tumor relapse compared to patients with smaller cysts (odds ratio (OR): 9.7,  $p = 0.02$ ). The authors concluded that laparoscopy should be discouraged for tumors larger than 5 cm, however, subsequent analysis showed laparoscopic safety and feasibility also for larger masses [13].

Romagnolo *et al.* [20] in a case series on 113 patients showed that a tumor diameter >10 cm was significantly associated with a preference for the laparotomic approach. Cyst rupture with tumor spillage was significantly higher in the laparoscopy group than in the open laparotomy group (34.6% *vs.* 6.6%,  $p < 0.0001$ ). However, the recurrence rate was similar between the two groups (13.5% in the laparoscopy groups *vs.* 9.8% in the open laparotomy group,



**Fig. 1. PRISMA study flow diagram.**

$p > 0.05$ ), and only the use of cystectomy was associated with reduced progression-free survival (PFS) [20].

In line with these results, Fauvet *et al.* [21] reported a significantly higher median diameter of the cyst in the laparotomy compared to the laparoscopic group (13.5 vs. 7.5 cm, respectively,  $p < 0.0001$ ), and cyst rupture was significantly higher in the laparoscopy group ( $p < 0.001$ ). On the other hand, the authors found that the conservative surgery was the only factor affecting the recurrence rate [21].

Song *et al.* [19] compared single-port laparoscopy, multi-port laparoscopy, and laparotomy. The median diameter was significantly different between the three groups ( $p < 0.001$ ): 9 cm, 8 cm, and 14 cm, respectively. The maximal diameter treated by laparoscopy was 17 cm, and the cyst rupture occurrence rate was not reported in these studies.

According to Ødegaard *et al.* [23], when considering a maximal diameter of 10 cm, tumor spillage is significantly higher with a laparoscopic approach than with open laparotomy.

On the contrary, in 2020 Kang *et al.* [24] conducted a retrospective study considering only patients with suspected BOT treated by single-port laparoscopy (n = 105) or open laparotomy (n = 73). The mean tumor diameter was 20 cm in both groups, and no significant difference was registered in intraoperative tumor rupture (11.4% vs. 6.8%,  $p = 0.307$ ). Remarkably, a technique involving controlled cyst rupture has been described. This method utilizes a wound retractor and aspiration of the cyst's contents, without compromising the continuation of the procedure through laparoscopy [24]. In line with these results Desfeux *et al.* [25] in a retrospective series on 118 patients with BOT, found an incidence of intraoperative tumor rupture of 9%, without differences between laparoscopy and laparotomy ( $p = 0.1$ ).

In summary, current literature does not establish a unanimous maximal cut-off to favor laparotomy over laparoscopy or vice versa. Some authors have reported a hig-

**Table 1. Tumor diameter, cyst rupture and surgical approach.**

Author	Year	Number of patients	Study design	Surgical approach	Tumor size	Obstetric outcomes	Oncological outcomes	Main results
Maneo <i>et al.</i> [13]	2004	62	Retrospective study	Intervention for restaging or follow-up purpose: LPS 30/62 (48.4%); LPT 32/62 (51.6%)	Mean diameter: 6.7 cm in the LPS group; 13.5 cm in the LPT group	/	Persistent disease after LPS in 11/30 patients (37%); 2/7 cases during restaging; 9/23 cases during follow-up surgery within 15 months	Laparoscopic treatment in BOTs should be reserved to masses smaller than 5 cm. When conservative therapy is desired, a salpingo-oophorectomy should be performed. In case of bilateral disease, cystectomy could be an option in women who wish to preserve fertility, although they are at high risk of relapse.
Romagnolo <i>et al.</i> [20]	2006	113	Retrospective multicenter study	LPS (46%); LPT (54%)	20–300 mm	15.1% pregnancy rate (8 pregnancies in 7 patients out of 53 FSS procedures)	11.5% recurrence rate	Conservative laparoscopic surgery may be the treatment of choice; no statistical difference was observed in the incidence of relapses between the types of surgical approaches.
Fauvet <i>et al.</i> [21]	2005	358	Retrospective multicenter study	LPS 149 (41.6%); LPT 209 (58.4%)	LPS group 7.5 cm ( $\pm 4.1$ ); LPT group 13.5 cm ( $\pm 8.0$ )	/	Recurrence rate and mean time to recurrence: LPS group 13/107 (12.1%) in $25 \pm 18.2$ months; Laparoconversion group 5/42 (11.9%) in $11.3 \pm 9.3$ months; LPT group 19/209 (9.1%) in $35.4 \pm 41.1$ months	Laparoscopy in borderline ovarian tumors is associated with a higher rate of cyst rupture and incomplete staging. Moreover, a higher recurrence rate is observed.
Song <i>et al.</i> [19]	2017	687	Retrospective study	SPA-LPS 89/687 (12.5%); MP-LPS 223/687 (32.4%); LPT 375/687 (54.6%)	9.0 cm (5.9–17.0); 8.0 cm (6.0–13.8); 14.0 cm (10.0–20.0)	/	Recurrence rate after a median FU of 41.8 months: SPA-LPS 4.5%; MP-LPS 7.6%; Open surgery 6.4%	Laparoscopic approach is preferred to open surgery. It is associated with more favorable surgical outcomes, with no compromise in oncologic outcome.
Ødegaard <i>et al.</i> [23]	2007	107	Retrospective study	LPS 38/107 (35.5%); LPT 69/107 (64.4%); Including 14 (27%) women starting with laparoscopy	LPS 8.6 cm (4–30); LPT 16.4 cm (3–35)	No difference in two groups	Follow-up: 14–78 months, no relapse occurring in either group	Laparoscopic treatment of BOTs is feasible if tumor is of moderate size (diameter below 10 cm), gives fewer complications, and shorter hospital stay.

Table 1. Continued.

Author	Year	Number of patients	Study design	Surgical approach	Tumor size	Obstetric outcomes	Oncological outcomes	Main results
Kang <i>et al.</i> [24]	2020	178	Retrospective study	SPA-LPS 105/178 (59%); LPT 73/178 (41%)	Tumor diameter 20.6 ± 6.3 cm; no difference between the two groups	/	Recurrence rate 2/54 (3.7%), one in each group	SPA laparoscopy for surgical treatment of a large ovarian tumor suspected to be BOT is feasible and is associated with a shorter hospital stay and less perioperative complications.
Desfeux <i>et al.</i> [25]	2005	118	Retrospective multicenter study	LPS 48/118 (41%); LPT 54/118 (45%); Laparoconversion 16/118 (14%)	/	/	Recurrence rate and time to recurrence: 1/48 in LPS group after 145 months; 5/54 in LPT group after 11–148 months; 2/6 patients had recurrent invasive cancer and died	Staging of macroscopic early stage BOTs was better in patients requiring radical surgery. After adjustment on disease severity, type of surgical access was not related to staging quality.
Jung <i>et al.</i> [26]	2018	643	Retrospective study	LPS 210/643 (32.7%); LPT 433/643 (67.3%)	LPS group 9.0 ± 5.3 cm; LPT group 16.3 ± 7.8 cm	/	Recurrence rate and mean time to relapse: LPS group 4.3% in 39 months (17–127); LPT group 5.3% in 26 months (3–88)	Laparoscopic surgery and open surgery showed similar survival outcomes in BOTs. The surgical outcomes of laparoscopic surgery were more favorable. In the multivariate analysis, age less than 40 years, nonmucinous histologic type, and extraovarian tumor implants were independent risk factors for decreased DFS.

Abbreviations: BOT, borderline ovarian tumor; LPS, laparoscopy; LPT, laparotomy; SPA-LPS, single-port access laparoscopy; MP-LPS, multi-port laparoscopy; FSS, fertility sparing surgery; DFS, disease free survival; FU, follow-up.

**Table 2. Laparoscopic approach in fertility sparing surgery.**

Author	Year	Number of patients	Study design	Surgical approach	Tumor size	Obstetric outcomes	Oncological outcomes	Main results
Chen <i>et al.</i> [27]	2016	122	Retrospective study	LPS 52/122 (42.6%); LPT 70/122 (57.4%)	10.5 ± 7.0 cm	Overall, 34/45 (75.6%) patients had a successful pregnancy	Recurrence rate and time to recurrence in the subtypes of surgery: USO 2.1%, 48 months; C: 6.8%, 22.8 months; USO+C: 14.3%, 26 months; BC: 22.2%, 21 months	FSS is safe and beneficial for most young BOTs. USO through laparoscopy should be recommended as the first choice. To the patients with bilateral tumors, elevated CA125, extra-ovary tumor or mucinous type, conservative surgery should be carefully chosen and subsequent pregnancy should be attempted in short term.
Uzan <i>et al.</i> [28]	2010	39	Retrospective study	LPS 21/39 (53.8%); LPT 10/39 (25.6%); Unknown 8/39 (20.5%)	/	Pregnancy rate 18/41 (43.9%); 9 patients with spontaneous pregnancy; 5 patients underwent infertility treatment	Recurrence rate 22/41 (56%) median time of FU of 48 months; 19/22 recurrent borderline ovarian tumor; 3/22 recurrent invasive cancer	Spontaneous pregnancy rate is high after conservative treatment of advanced-stage BOT (with noninvasive implants) but there's a high risk of relapse. Nevertheless, this high recurrence rate has no impact on survival. Conservative surgery is feasible in patients with a borderline tumor of the ovary and noninvasive peritoneal implants. In case of persistent infertility following treatment of the BOT, an <i>in vitro</i> fertilization procedure can be cautiously proposed.
Palomba <i>et al.</i> [29]	2007	32	Randomised controlled trial	LPS Experimental group: BC; LPS Control group: USO+C	/	Pregnancy rate: Experimental group 93.3%; Control group 52.9% ( $p = 0.011$ )	Recurrence rate 58–60%; Globally, no significant difference between BC and USO+C; Shorter time to first recurrence in the BC group ( $p < 0.001$ )	Laparoscopic bilateral cystectomy, followed by non-conservative treatment upon the first recurrence after completing childbearing, represents an effective surgical strategy for patients with bilateral early-stage BOTs who wish to achieve pregnancy as soon as possible.
Palomba <i>et al.</i> [30]	2010	32	Prospective long-term extension study of a randomized controlled trial	See above	/	Pregnancy rate: Experimental group 93.3%; Control group 58.8% ( $p = 0.04$ ); Significantly shorter time to conceive in the experimental group ( $p = 0.01$ )	Shorter time to first recurrence in the experimental group ( $p < 0.01$ )	The ultra-conservative approach (BC) has superior reproductive outcomes compared with the standard approach, albeit with an increased oncological risk.

Table 2. Continued.

Author	Year	Number of patients	Study design	Surgical approach	Tumor size	Obstetric outcomes	Oncological outcomes	Main results
Trillsch <i>et al.</i> [31]	2014	950	Retrospective multicenter study	LPS 297 (31.3%); Laparoconversion 67 (7.1%); LPT 585 (61.6%); Vaginal 1 (0.1%)	/	/	Recurrence rate 74/950 (7.8%): 50/74 in patients <40 years, 24/74 in patients >40 years; Invasive recurrent disease 22/74 (29.7%); 6/50 patients <40 years, 16/24 patients >40 years	Despite favourable survival, young BOT patients with child-bearing potential are at higher risk for disease recurrence. However, relapses usually remain BOT in the preserved ovaries as opposed to older patients being at higher risk for malignant transformation in peritoneal or distant localisation.
Zhao <i>et al.</i> [32]	2018	74	Retrospective study	LPT vs. LPS	/	Pregnancy rate of 33.8%, 9/30 patients in the LPT group and 16/44 in the LPS group	100% OS; Recurrence rate 6.75%	Good short-term outcomes and pregnancy were observed in patients receiving conservative treatment for BOTs, especially in patients receiving incomplete conservative laparoscopic surgery.

Abbreviations: BOT, borderline ovarian tumor; LPS, laparoscopy; LPT, laparotomy; USO, unilateral salpingo-oophorectomy; C, cystectomy; BC, bilateral cystectomy; USO+C, unilateral salpingo-oophorectomy and contralateral cystectomy; FSS, fertility sparing surgery; OS, overall survival; FU, follow-up; CA125, carbohydrate antigen 125.



**Table 3. Oncological outcomes and surgical approach.**

Author	Year	Number of patients	Study design	Surgical approach	Tumor size	Obstetric outcomes	Oncological outcomes	Main results
Du Bois <i>et al.</i> [33]	2013	950	Retrospective multicenter study	LPS 38.3%; LPT 61.6%	/	/	Recurrence rate 7.8% (74/950); With 30% recurrence as invasive cancer. 43 patients died during the FU	The prognosis of BOT is influenced by both tumor-related and surgery-related factors. The balance between recurrence risk and organ preservation through fertility-sparing surgery is a significant issue deserving further research.
Wu <i>et al.</i> [34]	2009	233	Retrospective study	LPS 39/233 (16.7%); LPT 194/233 (83.3%)	Mean 17.5 ± 9.4 cm	/	5-year OS 97.6%, 10-year OS 96.4%; 5-year RFS 92.7%, 10-year RFS 88.2%; Recurrence rate 21/233 (9%); 7/21 invasive recurrent carcinoma, 14/21 recurrent borderline tumor or implants	Although BOT has an excellent prognosis, they are not exempted from a risk of recurrence. Stage II/III (or invasive implants), cystectomy and higher pre-operative serum CA125 were independent variables predicting recurrence.
Koskas <i>et al.</i> [35]	2011	97	Retrospective study	LPS vs. LPT	Intestinal mBOT 17.6 cm (±9.1); Endocervical-like mBOT 8.4 cm (±3.0) ( $p = 0.03$ )	/	13.4% recurrence rate; The only factor associated with a higher risk of relapse was the use of cystectomy	Mucinous BOT is not a “safe” disease. Cystectomy as conservative treatment was the only factor that correlated with relapse, suggesting that a salpingo-oophorectomy should be preferred.
Lenhard <i>et al.</i> [36]	2009	113	Retrospective study	LPS 18/113 (15.9%); LPT 95/113 (84.1%)	/	/	Recurrence rate and mean time to recurrence: 10.1% (10/99) in 2.0 ± 1.7 months; 5-years and 10-years OS with recurrence 90% and 80%; 5-years and 10-years OS without recurrence 98.9% and 94.4%	Borderline ovarian tumor shows good prognosis in general. Patients with invasive implants have higher relapse rates. Fertility sparing surgery in women at childbearing age can be an adequate treatment option in early-stage disease.

Table 3. Continued.

Author	Year	Number of patients	Study design	Surgical approach	Tumor size	Obstetric outcomes	Oncological outcomes	Main results
Camatte <i>et al.</i> [37]	2004	34	Retrospective study	LPS: Group A: primary surgery; Group B: recurrent BOT	Median size 5 cm (2–12)	Ten pregnancies in 6/15 patients with a median time to first pregnancy after surgical treatment of 5 months	6/34 (17.6%) patients relapsed; 5/6 had recurrent BOT; 1/6 recurrent peritoneal implants	Laparoscopic treatment can be safely performed in young patients with early stage BOT. Such a procedure is then feasible, but should be evaluated in patients with BOT and peritoneal implants.
Kipp <i>et al.</i> [38]	2023	42	Retrospective study	LPS 29/42 (69.0%); LPT 13/42 (31.0%)	/	/	Recurrence rate 4.8% (2/34 patients). One died for recurrent low-grade ovarian carcinoma	A very low recurrence rate was observed. Neither advanced FIGO stage, nor incomplete staging, nor peritoneal implants were associated with a higher recurrence rate, contrary to findings in other studies. Further studies are necessary to investigate additional recurrence risks.

Abbreviations: BOT, borderline ovarian tumor; mBOT, mucinous borderline ovarian tumor; LPS, laparoscopy; LPT, laparotomy; OS, overall survival; RFS, recurrence free survival; FU, follow-up; FIGO, the International Federation of Gynecology and Obstetrics.

her risk of cyst rupture during laparoscopy [20,21,23]; however, this association is not consistently confirmed in all available case series, even for large masses [24–26]. Furthermore, when considering the oncological outcome, cyst rupture does not necessarily affect the prognosis, and the use of an endo-bag provides additional assistance to the surgeon in preventing tumor spillage into the abdominal cavity [40,41]. In conclusion, when deciding the optimal surgical approach for BOT treatment, tumor dimension should not be the sole parameter to consider. Instead, the surgeon's laparoscopic skills and the risk of malignancy at the final histology should also be taken into account [42].

#### 4.2 Laparoscopic Approach in Fertility Sparing Surgery

Fertility preservation is a crucial concern in the treatment of BOT, especially considering that one-third of patients are younger than 40 years at the time of diagnosis [43,44]. In this specific group of patients, laparoscopy emerges as a preferable option compared to laparotomy offering improved cosmetic outcomes [45,46]. Furthermore, some authors reported the feasibility of fertility-sparing surgery not only in early-stage disease but also in patients with peritoneal implants [47].

Chen *et al.* [27] analyzed the oncological and fertility outcomes of 122 patients undergoing FSS via laparotomy ( $n = 70$ ) and laparoscopy ( $n = 52$ ). Recurrence rate (RR) and DFS did not differ depending on the surgical approach (7.1% vs. 5.8% and 25.5 months vs. 26.3 months,  $p > 0.05$ ). The pregnancy rate was respectively 66.7% in the laparotomy group and 88.9% in the laparoscopy group, but this difference did not reach statistical significance ( $p = 0.16$ ).

Looking at the feasibility of conservative treatment in advanced-stage borderline ovarian tumors, Uzan *et al.* [28] retrieved the outcomes of 39 patients affected by BOT and conservatively treated. The laparoscopic approach was used in 21 patients, the laparotomic approach in 10 patients, and in 8 cases the surgical approach was unknown [28]. In their study, 22 patients (56%) relapsed, and no association with the type of surgical approach was observed. Five and ten-year overall survival (OS) rates were 100% and 92%, respectively. According to the authors, conservative surgery is feasible in advanced-stage patients with peritoneal implants. However, an adequate follow-up is necessary because of the higher recurrence rate. Moreover, the treatment of recurrence can once again involve a fertility-sparing approach if technically feasible. Eighteen pregnancies were observed in 14 patients, however, the pregnancy rate was not assessed because the desire for pregnancy was not registered.

A study conducted by Palomba *et al.* [29] in 2007, and then extended in 2010, compared the fertility outcomes in patients affected by bilateral stage I BOT treated by conservative surgery. In these studies, patients were divided into two groups: the experimental group underwent ultraconservative treatment (bilateral cystectomy) while the

control group underwent conservative treatment (unilateral salpingo-oophorectomy plus contralateral cystectomy). Surgery in both groups was conducted with a laparoscopic approach and consisted of complete peritoneal staging. The study showed significantly higher serum follicle-stimulating hormone (FSH) levels and a higher cumulative pregnancy rate, with a shorter time to conceive in the experimental group compared to the control group. Therefore, in the case of bilateral serous BOTs bilateral cystectomy should be performed if technically feasible.

In 2010 Palomba *et al.* [30] published the oncological and obstetrics outcomes, in the same group of patients, after an 11-year follow-up. There was no significant difference between the two groups in the recurrence rate, neither in the multiple recurrence rate, in age at first recurrence, nor in the age of patients who received non-conservative surgery. On the other hand, a much shorter progression free survival was observed in patients who underwent bilateral cystectomy compared with those who received unilateral salpingo-oophorectomy plus contralateral cystectomy ( $p < 0.01$ ).

Trillsch *et al.* [31] in 2014 conducted a sub-analysis on 950 patients with BOT, comparing patients under 40 years of age and older than 40 years. The laparoscopic approach was significantly more frequently used in the younger group ( $p < 0.001$ ). At multivariate analysis, advanced FIGO stage and FSS were associated with reduced PFS. However, the authors emphasize that in young patients the disease relapsed as BOT. Therefore, patients who wish to retain fertility should be counseled about the potential risk of recurrence without a detrimental effect on OS.

In 2018 Zhao *et al.* [32] compared short-term outcomes and pregnancy rates in 74 patients undergoing FSS for BOT. Out of the 74 patients, 44 underwent laparotomic treatment, while 30 received laparoscopic treatment. Interestingly, there was no statistically significant difference in the recurrence rate observed between these two groups. The overall pregnancy rate was 33.8% (25 out of 74 patients), with 30% (9 patients) in the laparotomy group and 36.4% (16 patients) in the laparoscopic group achieving pregnancy during the follow-up period. Interestingly, the pregnancy rate was significantly higher in the laparoscopy group when considering incomplete surgical staging (complete laparoscopic exploration with incomplete surgery).

In conclusion, laparoscopy is widely used for fertility-sparing surgery in BOT patients, with good oncological outcomes. However, a higher recurrence risk should be taken into account, especially in case of a higher FIGO stage and incomplete staging. A minimally invasive approach with limited surgical gestures seems also to be associated with a good impact on obstetric outcomes. Indeed, laparoscopic FSS is the preferable approach in young patients with BOT who wish to preserve fertility.

### 4.3 Oncological Outcomes and Surgical Approach

BOT is typically diagnosed at an early stage, with a 5-year OS rate reaching 95–97% [48]. However, the prognosis is primarily influenced by recurrences, even long after the primary treatment, therefore a long-term follow-up is suggested [47].

In a large retrospective analysis including 950 patients, du Bois *et al.* [33] analyzed risk factors for BOT recurrence. The surgical approach was laparoscopy in 38.3% of cases, and laparotomy in 61.6%. The recurrence rate was 7.8%. At multivariate analysis, the authors found that higher stage, residual tumor, and incomplete staging are independent prognostic factors for recurrence. On the contrary, recurrence rate and OS are not affected by the type of surgical approach.

In an important retrospective study conducted by Wu *et al.* [34] the outcomes of 233 patients affected by BOT at various stages and submitted to different methods of surgery were analyzed in terms of five-year and ten-year OS and PFS. 16.7% of the patients were treated by laparoscopic approach and 83.3% by laparotomy, 30.9% underwent complete staging, while 62.2% received FSS. Five-year and ten-year OS were 97.6% and 96.4%, and PFS were 92.7% and 88.2% in the laparoscopic compared to the laparotomic group. Of the 21 patients who had a recurrence, 7 had an invasive carcinoma recurrence and 5 of them died from the disease. Four out of 5 patients who died were stage II or higher at first surgery, and only one had stage IC mucinous BOT with invasive relapse. The other 14 patients had recurrent borderline tumors or implants. Data showed no difference in recurrence-free survival (RFS) or OS between laparoscopic and laparotomic approaches and between fertility-sparing and non-sparing surgery. Higher stage, excisional type (cystectomy vs. adnexectomy), and higher serum CA125 level ( $\geq 144$  U/mL) were independent prognostic factors for 5-year PFS.

Mucinous borderline tumor (mBOT) represents a particular condition since they often present as large masses and are associated with a higher recurrence risk even in the form of invasive disease [47]. In a retrospective study by Koskas *et al.* [35], the management and outcome of 97 patients diagnosed with mBOT were analyzed to investigate prognostic factors for disease recurrence. 43% of patients underwent laparoscopy, and 56% received open laparotomy. There were 14 recurrences in 13 patients, 6 in the form of recurrent borderline tumors and 6 in the form of invasive disease. 5-year and 10-year DFS was, respectively, 81.6% and 77.3% in the laparoscopy compared to the laparotomic group. Of these 13 patients who relapsed, 8 had received unilateral cystectomy as initial surgery. Neither the surgical approach during surgery, perioperative tumor rupture, conservative surgery, nor incomplete staging were associated with an increased risk for recurrence. Cystectomy was the only factor significantly associated with the risk of recurrence.

A retrospective study conducted by Lenhard *et al.* [36] assessed long-term survival and relapse rate of 113 patients diagnosed with BOT. The surgical approach was laparoscopic in 15.9% of the patients and laparotomic in 84.1% of the patients. The mean follow-up time was  $9.6 \pm 6.6$  years. The overall 5-year and 10-year survival rates were 98.0% and 92.9%, respectively. During the follow-up period, relapse occurred in 10 patients (10.1%, 10/99). Among the various factors analyzed, only a higher FIGO stage at diagnosis (above IA) was significantly associated with relapse occurrence. Neither the choice between laparoscopic and laparotomic approach, nor the type of surgery (conservative or ultraconservative) versus radical surgery, showed any significant impact on oncological outcomes.

Camatte *et al.* [37] reviewed the clinical outcome after laparoscopic treatment of 34 patients affected by BOT. Among the 34 patients, 23 underwent primary surgery, while 11 patients received laparoscopic treatment for a BOT recurrence. After a median follow-up time of 45 months, six patients experienced a relapse, with three cases observed in each group. The median time to recurrence was 29 months. Notably, all patients were treated laparoscopically, and none had recurrent invasive cancer.

A study published in 2023 by Kipp *et al.* [38] analyzed the data of 42 women with BOT. Among these patients, 29 (69%) underwent laparoscopic surgery, while 13 (31%) received laparotomic surgery. The majority of women were diagnosed at FIGO stage I (85.8%). Four patients (9.6%) received FSS. The study observed two cases of relapse (4.8%), and one patient succumbed to recurrent low-grade ovarian carcinoma, which occurred 44 months after the primary surgery for a mucinous BOT. Interestingly, the study found no significant associations between the surgical approach (laparoscopic vs. laparotomic), advanced FIGO stage, incomplete staging, or peritoneal implants with a higher recurrence rate. These findings highlight the need for further research to understand the factors influencing recurrence in BOT cases.

In conclusion, BOT has optimal long-term survival, but the prognosis can be affected by the long-term risk of recurrence [36,47]. Therefore, a long follow-up is recommended for these patients. The relapse itself does not change the OS as it mostly recurs as BOT. Nevertheless, there's a risk of evolution to invasive carcinoma that appears to be higher in older patients [31] and in mucinous BOT [38]. In the case of mBOT a salpingo-oophorectomy may be preferred to the cystectomy. Despite international guidelines favoring open surgery as the standard of care, laparoscopy remains a reasonable option, even in cases of relapsed disease, as there is no significant correlation between the laparoscopic approach and the recurrence rate based on the most updated literature [37].

## 5. Conclusions

In conclusion, current guidelines recommend open laparotomy as the preferred approach for suspicious ovarian masses, but laparoscopy has gained popularity as a feasible and safe alternative for treating BOT. While some studies suggest a higher risk of cyst rupture during laparoscopy, it does not necessarily affect the oncological prognosis. Moreover, the use of an endo-bag, along with advanced laparoscopic skills, can help reduce the occurrence of tumor spillage. Laparoscopy is widely employed for FSS in BOT patients, demonstrating more favorable obstetric outcomes compared to open approach, without detrimental effect on OS and DFS. Although relapse does not significantly impact overall survival, a long-term risk of recurrence exists, but laparoscopic surgery does not appear to increase this risk. Finally, based on the existing retrospective evidence, laparoscopy emerges as a safe and viable choice for the management of BOT. However, additional confirmation through prospective studies is necessary to further establish laparoscopy efficacy and safety in BOT patients.

## Availability of Data and Materials

Data sharing is not applicable to this article, as no datasets were generated or analyzed during the current study.

## Author Contributions

VAC designed the study and reviewed it critically; IR, ES, GM analyzed the data, wrote manuscript and reviewed final version to be published; DS and ADF collected data and wrote manuscript; LM and MG performed the research, and collected data; CM, ML, AG analyzed the data; SC, SR, GV analyzed the data and reviewed the work critically. All authors contributed to editorial changes in the manuscript. All authors read and approved the final manuscript. All authors have participated sufficiently in the work and agreed to be accountable for all aspects of the work.

## Ethics Approval and Consent to Participate

Not applicable.

## Acknowledgment

We want to extend our heartfelt appreciation to everyone who supported us throughout the creation of this manuscript.

## Funding

This research received no external funding.

## Conflict of Interest

The authors declare no conflict of interest. Stefano Cianci is serving as one of the Editorial Board/Guest editors members of this journal; We declare that Stefano Cianci had no involvement in the peer review of this article and had

no access to information regarding its peer review. Full responsibility for the editorial process for this article was delegated to Michael H. Dahan and Valerio Gaetano Vellone.

## Supplementary Material

Supplementary material associated with this article can be found, in the online version, at <https://doi.org/10.31083/j.ceog5012277>.

## References

- [1] WHO Classification of Tumours Editorial Board ed. World Health Organization classification of tumours. 5th edn. Female-genital tumours. IARC Press: Lyon. 2020.
- [2] Vine MF, Ness RB, Calingaert B, Schildkraut JM, Berchuck A. Types and duration of symptoms prior to diagnosis of invasive or borderline ovarian tumor. *Gynecologic Oncology*. 2001; 83: 466–471.
- [3] Raimondo D, Raffone A, Scambia G, Maletta M, Lenzi J, Restaino S, *et al*. The impact of hysterectomy on oncological outcomes in postmenopausal patients with borderline ovarian tumors: A multicenter retrospective study. *Frontiers in Oncology*. 2022; 12: 1009341.
- [4] Gueli Alletti S, Perrone E, Creti A, Cianci S, Uccella S, Fedele C, *et al*. Feasibility and perioperative outcomes of percutaneous-assisted laparoscopic hysterectomy: A multicentric Italian experience. *European Journal of Obstetrics, Gynecology, and Reproductive Biology*. 2020; 245: 181–185.
- [5] Rossitto C, Cianci S, Gueli Alletti S, Perrone E, Pizzacalla S, Scambia G. Laparoscopic, minilaparoscopic, single-port and percutaneous hysterectomy: Comparison of perioperative outcomes of minimally invasive approaches in gynecologic surgery. *European Journal of Obstetrics, Gynecology, and Reproductive Biology*. 2017; 216: 125–129.
- [6] Seidman JD, Soslow RA, Vang R, Berman JJ, Stoler MH, Sherman ME, *et al*. Borderline ovarian tumors: diverse contemporary viewpoints on terminology and diagnostic criteria with illustrative images. *Human Pathology*. 2004; 35: 918–933.
- [7] Colombo N, Sessa C, du Bois A, Ledermann J, McCluggage WG, McNeish I, *et al*. ESMO-ESGO consensus conference recommendations on ovarian cancer: pathology and molecular biology, early and advanced stages, borderline tumours and recurrent disease. *Annals of Oncology*. 2019; 30: 672–705.
- [8] Bizzarri N, du Bois A, Fruscio R, De Felice F, De Iaco P, Casarin J, *et al*. Is there any therapeutic role of pelvic and para-aortic lymphadenectomy in apparent early stage epithelial ovarian cancer? *Gynecologic Oncology*. 2021; 160: 56–63.
- [9] Perrone E, Rossitto C, Fanfani F, Cianci S, Fagotti A, Uccella S, *et al*. Percutaneous-Assisted versus Laparoscopic Hysterectomy: A Prospective Comparison. *Gynecologic and Obstetric Investigation*. 2020; 85: 318–326.
- [10] Cianci S, Capozzi VA, Rosati A, Rumolo V, Corrado G, Uccella S, *et al*. Different Surgical Approaches for Early-Stage Ovarian Cancer Staging. A Large Monocentric Experience. *Frontiers in Medicine*. 2022; 9: 880681.
- [11] La Verde M, Riemma G, Tropea A, Biondi A, Cianci S. Ultraminimally invasive surgery in gynecological patients: a review of the literature. *Updates in Surgery*. 2022; 74: 843–855.
- [12] Cianci S, Rosati A, Rumolo V, Gueli Alletti S, Gallotta V, Turco LC, *et al*. Robotic Single-Port Platform in General, Urologic, and Gynecologic Surgeries: A Systematic Review of the Literature and Meta-analysis. *World Journal of Surgery*. 2019; 43: 2401–2419.
- [13] Maneo A, Vignali M, Chiari S, Colombo A, Mangioni C, Lan-

- doni F. Are borderline tumors of the ovary safely treated by laparoscopy? *Gynecologic Oncology*. 2004; 94: 387–392.
- [14] Cianci S, Perrone E, Rossitto C, Fanfani F, Tropea A, Biondi A, *et al.* Percutaneous-assisted vs. mini-laparoscopic hysterectomy: comparison of ultra-minimally invasive approaches. *Updates in Surgery*. 2021; 73: 2347–2354.
- [15] Della Corte L, Cafasso V, Mercorio A, Vizzielli G, Conte C, Giampaolino P. Editorial: Management of borderline ovarian tumor: The best treatment is a real challenge in the era of precision medicine. *Frontiers in Surgery*. 2023; 10: 1167561.
- [16] Ikeda Y, Yoshihara M, Yoshikawa N, Tamauchi S, Yokoi A, Nishino K, *et al.* Is cystectomy an option as conservative surgery for young patients with borderline ovarian tumor? A multi-institutional retrospective study. *International Journal of Gynecology and Obstetrics*. 2022; 157: 437–443.
- [17] Vasconcelos I, de Sousa Mendes M. Conservative surgery in ovarian borderline tumours: a meta-analysis with emphasis on recurrence risk. *European Journal of Cancer*. 2015; 51: 620–631.
- [18] Conte C, Pelligra S, Sarpietro G, Montana GD, Della Corte L, Bifulco G, *et al.* Hereditary Women's Cancer: Management and Risk-Reducing Surgery. *Medicina*. 2023; 59: 300.
- [19] Song T, Kim MK, Jung YW, Yun BS, Seong SJ, Choi CH, *et al.* Minimally invasive compared with open surgery in patients with borderline ovarian tumors. *Gynecologic Oncology*. 2017; 145: 508–512.
- [20] Romagnolo C, Gadducci A, Sartori E, Zola P, Maggino T. Management of borderline ovarian tumors: results of an Italian multicenter study. *Gynecologic Oncology*. 2006; 101: 255–260.
- [21] Fauvet R, Boccaro J, Dufournet C, Poncelet C, Daraï E. Laparoscopic management of borderline ovarian tumors: results of a French multicenter study. *Annals of Oncology*. 2005; 16: 403–410.
- [22] Page MJ, McKenzie JE, Bossuyt PM, Boutron I, Hoffmann TC, Mulrow CD, *et al.* The PRISMA 2020 statement: an updated guideline for reporting systematic reviews. *British Medical Journal*. 2021; 372: n71.
- [23] Ødegaard E, Staff AC, Langebrekke A, Engh V, Onsrud M. Surgery of borderline tumors of the ovary: retrospective comparison of short-term outcome after laparoscopy or laparotomy. *Acta Obstetrica et Gynecologica Scandinavica*. 2007; 86: 620–626.
- [24] Kang JH, Noh JJ, Jeong SY, Shim JI, Lee YY, Choi CH, *et al.* Feasibility of Single-Port Access (SPA) Laparoscopy for Large Ovarian Tumor Suspected to Be Borderline Ovarian Tumor. *Frontiers in Oncology*. 2020; 10: 583515.
- [25] Desfeux P, Camatte S, Chatellier G, Blanc B, Querleu D, Lécuru F. Impact of surgical approach on the management of macroscopic early ovarian borderline tumors. *Gynecologic Oncology*. 2005; 98: 390–395.
- [26] Jung HJ, Park JY, Kim DY, Suh DS, Kim JH, Kim YM, *et al.* Comparison of Laparoscopic and Open Surgery for Patients With Borderline Ovarian Tumors. *International Journal of Gynecological Cancer*. 2018; 28: 1657–1663.
- [27] Chen RF, Li J, Zhu TT, Yu HL, Lu X. Fertility-sparing surgery for young patients with borderline ovarian tumors (BOTs): single institution experience. *Journal of Ovarian Research*. 2016; 9: 16.
- [28] Uzan C, Kane A, Rey A, Gouy S, Duvillard P, Morice P. Outcomes after conservative treatment of advanced-stage serous borderline tumors of the ovary. *Annals of Oncology*. 2010; 21: 55–60.
- [29] Palomba S, Zupi E, Russo T, Falbo A, Del Negro S, Manguso F, *et al.* Comparison of two fertility-sparing approaches for bilateral borderline ovarian tumours: a randomized controlled study. *Human Reproduction*. 2007; 22: 578–585.
- [30] Palomba S, Falbo A, Del Negro S, Rocca M, Russo T, Cariati F, *et al.* Ultra-conservative fertility-sparing strategy for bilateral borderline ovarian tumours: an 11-year follow-up. *Human Reproduction*. 2010; 25: 1966–1972.
- [31] Trillsch F, Mahner S, Woelber L, Vettorazzi E, Reuss A, Ewald-Riegler N, *et al.* Age-dependent differences in borderline ovarian tumours (BOT) regarding clinical characteristics and outcome: results from a sub-analysis of the Arbeitsgemeinschaft Gynaekologische Onkologie (AGO) ROBOT study. *Annals of Oncology*. 2014; 25: 1320–1327.
- [32] Zhao J, Liu C, Liu J, Qu P. Short-term Outcomes and Pregnancy Rate After Laparoscopic Fertility-Sparing Surgery for Borderline Ovarian Tumors: A Single-Institute Experience. *International Journal of Gynecological Cancer*. 2018; 28: 274–278.
- [33] du Bois A, Ewald-Riegler N, de Gregorio N, Reuss A, Mahner S, Fotopoulou C, *et al.* Borderline tumours of the ovary: A cohort study of the Arbeitsgemeinschaft Gynäkologische Onkologie (AGO) Study Group. *European Journal of Cancer*. 2013; 49: 1905–1914.
- [34] Wu TI, Lee CL, Wu MY, Hsueh S, Huang KG, Yeh CJ, *et al.* Prognostic factors predicting recurrence in borderline ovarian tumors. *Gynecologic Oncology*. 2009; 114: 237–241.
- [35] Koskas M, Uzan C, Gouy S, Pautier P, Lhommé C, Haie-Meder C, *et al.* Prognostic factors of a large retrospective series of mucinous borderline tumors of the ovary (excluding peritoneal pseudomyxoma). *Annals of Surgical Oncology*. 2011; 18: 40–48.
- [36] Lenhard MS, Mitterer S, Kümper C, Stieber P, Mayr D, Ditsch N, *et al.* Long-term follow-up after ovarian borderline tumor: relapse and survival in a large patient cohort. *European Journal of Obstetrics, Gynecology, and Reproductive Biology*. 2009; 145: 189–194.
- [37] Camatte S, Morice P, Atallah D, Thoury A, Pautier P, Lhommé C, *et al.* Clinical outcome after laparoscopic pure management of borderline ovarian tumors: results of a series of 34 patients. *Annals of Oncology*. 2004; 15: 605–609.
- [38] Kipp B, Vidal A, Lenick D, Christmann-Schmid C. Management of Borderline ovarian tumors (BOT): results of a retrospective, single center study in Switzerland. *Journal of Ovarian Research*. 2023; 16: 20.
- [39] Berretta R, Rolla M, Patrelli TS, Gramellini D, Fadda GM, Nardelli GB. Incidence of port-site metastasis after laparoscopic management of borderline ovarian tumors: a series of 22 patients. *European Journal of Gynaecological Oncology*. 2009; 30: 300–302.
- [40] Kim HS, Ahn JH, Chung HH, Kim JW, Park NH, Song YS, *et al.* Impact of intraoperative rupture of the ovarian capsule on prognosis in patients with early-stage epithelial ovarian cancer: a meta-analysis. *European Journal of Surgical Oncology*. 2013; 39: 279–289.
- [41] Feghali EJ, Laganà AS, Daccache A, Bitar R, Garzon S, Uccella S, *et al.* Endobag use in laparoscopic gynecological surgeries: a systematic review. *Minimally Invasive Therapy & Allied Technologies*. 2022; 31: 698–703.
- [42] Giampaolino P, Della Corte L, Foreste V, Vitale SG, Chiofalo B, Cianci S, *et al.* Unraveling a difficult diagnosis: the tricks for early recognition of ovarian cancer. *Minerva Medica*. 2019; 110: 279–291.
- [43] Moro F, Baima Poma C, Zannoni GF, Vidal Urbinati A, Pasciuto T, Ludovisi M, *et al.* Imaging in gynecological disease (12): clinical and ultrasound features of invasive and non-invasive malignant serous ovarian tumors. *Ultrasound in Obstetrics & Gynecology*. 2017; 50: 788–799.
- [44] Capozzi VA, Scarpelli E, Monfardini L, Mandato VD, Merisio C, Uccella S, *et al.* Do Exophytic and Endophytic Patterns in Borderline Ovarian Tumors Have Different Prognostic Implications? A Large Multicentric Experience. *Journal of Clinical*

Medicine. 2023; 12: 3544.

- [45] Daraï E, Fauvet R, Uzan C, Gouy S, Duvillard P, Morice P. Fertility and borderline ovarian tumor: a systematic review of conservative management, risk of recurrence and alternative options. *Human Reproduction Update*. 2013; 19: 151–166.
- [46] Gueli Alletti S, Vizzielli G, Lafuenti L, Costantini B, Fagotti A, Fedele C, *et al.* Single-Institution Propensity-Matched Study to Evaluate the Psychological Effect of Minimally Invasive Interval Debulking Surgery Versus Standard Laparotomic Treatment: From Body to Mind and Back. *Journal of Minimally Invasive Gynecology*. 2018; 25: 816–822.
- [47] Morice P, Uzan C, Fauvet R, Gouy S, Duvillard P, Daraï E. Borderline ovarian tumour: pathological diagnostic dilemma and risk factors for invasive or lethal recurrence. *The Lancet. Oncology*. 2012; 13: e103–e115.
- [48] Lazarou A, Fotopoulou C, Coumbos A, Sehouli J, Vasiljeva J, Braicu I, *et al.* Long-term follow-up of borderline ovarian tumors clinical outcome and prognostic factors. *Anticancer Research*. 2014; 34: 6725–6730.