


GUIDELINES

International Dermoscopy Society consensus recommendations for the management of lentigo maligna

Ana-Maria Forsea^{1,2}  | Riccardo Pampena³ | Bengu Nisa Akay⁴  | Zoe Apalla⁵  | Giuseppe Argenziano⁶  | Giulia Briatico⁶  | Ralph Braun⁷ | Horacio Cabo⁸ | Raul Cabrera⁹ | Cristina Carrera^{10,11}  | Elisa Cinotti¹² | Claudio Conforti^{13,14}  | Enzo Errichetti¹⁵ | Gerardo Ferrara¹⁶ | Roberta Giuffrida¹⁷ | Stefania Guida^{18,19} | Pascale Guitera^{20,21} | Allan C. Halpern²²  | Stephen Heyes²³ | Rainer Hofmann-Wellenhof²⁴ | Angela M. Hong²⁰ | Natalia Jaimes²⁵ | Raimonds Karls²⁶ | Harald Kittler²⁷ | Teresa Kränke²⁸  | Konstantinos Liopyris²⁹  | Jie Liu³⁰  | Caterina Longo³¹ | Josep Malvehy^{32,33} | Ashfaq A. Marghoob³⁴ | Hoda Moneib³⁵ | David Moreno Ramirez³⁶ | Elvira Moscarella³⁷  | Eduardo Nagore^{38,39}  | Cristian Navarrete-Dechent^{40,41}  | John Paoli^{42,43}  | Giovanni Pellacani⁴⁴  | Ketty Peris^{45,46}  | Susana Puig⁴⁷  | Cliff Rosendahl⁴⁸ | Lidia Rudnicka⁴⁹  | Ahmed Sadek⁵⁰ | Philippe Saiag^{51,52} | Gabriel Salerni^{53,54} | Alon Scope^{55,56}  | Hans Peter Soyer⁵⁷ | Michela V. Starace^{58,59}  | Wilhelm Stolz⁶⁰ | David L. Swanson⁶¹ | Luc Thomas^{62,63,64}  | Philipp Tschandi²⁷  | Iris Zalaudek⁶⁵ | Aimilios Lallas⁶⁶ 

Correspondence

Aimilios Lallas, First Department of Dermatology, School of Medicine, Faculty of Health Sciences, Aristotle University, 124 Delfon Street, Thessaloniki, Greece.
Email: emlallas@gmail.com

Abstract

Lentigo maligna (LM) is a subtype of cutaneous melanoma in situ that develops on chronically sun-damaged skin in elderly individuals. Its diagnosis and management remain challenging due to its slow progression, frequent occurrence on cosmetically sensitive areas in frail individuals, and tendency for subclinical peripheral extension. Despite its potential for invasive transformation, the natural history of LM remains incompletely understood and evidence-based management strategies for this specific entity remain limited. This work aims to bridge the gap between scarce high-quality evidence and the clinicians' need for practical guidance on LM management by formulating evidence-based and expert consensus-driven recommendations for diagnosis, treatment and follow-up. Under the coordination of the International Dermoscopy Society, a global, multidisciplinary consortium of 53 experts—including dermatologists, dermato-oncologists, dermatologic surgeons, radiologists, radiotherapists, pathologists and epidemiologists—formulated recommendations through structured consensus, informed by a comprehensive review of current scientific evidence and clinical practice standards. Optimal management of LM requires accurate diagnosis and individualized treatment planning. Non-invasive skin imaging

For affiliations refer to page 13.

This is an open access article under the terms of the [Creative Commons Attribution-NonCommercial](https://creativecommons.org/licenses/by-nc/4.0/) License, which permits use, distribution and reproduction in any medium, provided the original work is properly cited and is not used for commercial purposes.

© 2026 The Author(s). *Journal of the European Academy of Dermatology and Venereology* published by John Wiley & Sons Ltd on behalf of European Academy of Dermatology and Venereology.

techniques, especially dermoscopy and reflectance confocal microscopy, aid in diagnosis, biopsy orientation, lesion delineation and post-treatment monitoring. Multiple partial biopsies help confirm diagnosis and rule out invasion. Complete surgical excision remains the first treatment option. No definitive safety margins can be recommended for standard surgery; margin-controlled techniques are preferable for large or ill-defined lesions. Topical imiquimod and radiotherapy are effective alternatives where surgery is unsuitable. Topical imiquimod is useful as primary, adjuvant or neoadjuvant therapy. Blind destructive methods should be avoided. Close clinical and imaging follow-up is needed. Patient-centred care, shared decision-making, and a multidisciplinary approach are critical for optimal outcomes. These international consensus recommendations summarize current best practices for LM management, offering practical, evidence-informed guidance to clinicians while acknowledging the potential of future research in refining these conclusions.

KEY WORDS

consensus, guidelines, lentigo maligna, management, melanoma, skin imaging

INTRODUCTION

Lentigo maligna (LM) is a subtype of cutaneous melanoma in situ, developing on chronically sun-exposed skin, particularly in the elderly.¹ Differential diagnosis and management of LM are challenging: it arises on cosmetically sensitive areas, often extends widely and subclinically into surrounding sun-damaged skin and typically affects elderly, fragile patients. LM usually follows an indolent course, remaining for years or decades within the epidermis. It can progress to invasive melanoma, but the rate and the timing of dermal invasion remain unknown, which likely explains why LM is overlooked in most melanoma guidelines that focus on invasive tumours.²⁻⁵ Correspondingly, randomized trials and large studies specific to LM are scarce, and most recommendations derive from limited case series or extrapolation from other melanoma types.

Scope

The current work aims to narrow the gap between limited high-quality evidence and clinicians' need for orientation and practical guidance on LM management. We do not attempt a comprehensive literature overview (already available elsewhere^{6,7}) but to provide practical recommendations for the diagnosis, treatment and follow-up of LM, based on the best available scientific evidence and the consensus from a worldwide expert consortium.

Target population

Dermatologists, general practitioners, other medical specialists and nursing staff involved in LM management.

Object

The work addresses LM, defined as a distinct form of melanoma in situ with characteristic histopathology, occurring

Why was the study undertaken? Summarize the main research question addressed by your study

- The diagnosis and management of lentigo maligna (LM) are challenging for clinicians, while incidence rates are increasing worldwide. There is scarce evidence-based information for the optimal management of LM, as very few randomized controlled trials address specifically this entity. Most data are extrapolated from studies in other forms of melanoma in situ or from invasive melanoma guidelines. Practical guidance for optimal LM management is needed.

What does this study add? Summarize the primary, original findings of the study, highlighting its novelty and significance

- This work supplements the best available evidence with the collective expertise of a global, multidisciplinary consortium of key opinion leaders in the field. It delivers pragmatic guidance for the diagnosis and management of LM. Proven dermoscopic and reflectance confocal microscopy criteria underpin diagnosis, delineation and follow-up assessment. Surgery is the first treatment option, with margin-controlled techniques preferred for complex lesions. Topical imiquimod and radiotherapy represent effective, patient-centred alternatives to surgery. Topical imiquimod may be used as primary, neoadjuvant or adjuvant treatment.

What are the implications of this study for disease understanding and/or clinical care? Summarize the novel perspective offered by the study

- This work bridges the gap between scarce high-quality evidence and the clinicians' need for

practical guidance on LM management. It does this through a wealth of practical information derived from the expertise of a worldwide multi-disciplinary expert consortium. This set of recommendations is potentially practice changing, as it shifts the focus of management from the surgical standard to a wider array of non-invasive, conservative alternatives that place the patient, personalized medicine and shared decision-making in the centre of care.

on chronically sun-exposed skin, typically on the head and neck, after the 4th decade of life.¹ The management of invasive melanoma arising from LM (Lentigo maligna melanoma, LMM) is not covered here, as it is detailed by existing guidelines for invasive melanoma.^{2–4}

Validity

These recommendations reflect the best published data and authors' expert opinion at the time of preparation. Future studies may modify their conclusions. These recommendations do not replace or supersede national guidelines or substitute physicians' judgement and should be tailored to individual patient characteristics.

METHODS

Consortium

We convened a broad consortium of 53 experts from 20 countries and all continents, coordinated by the International Dermoscopy Society (IDS). Participants were delegates of national/international medical societies, with prior contributions to melanoma and LM guidelines. Interdisciplinarity was ensured by including specialists in dermatology, dermatology, dermatology, radiology, radiotherapy, dermatologic surgery, pathology and epidemiology.

Literature search

A de novo search of Pubmed/Medline for English-language publications using the term 'lentigo maligna' was conducted, initially on January 2024, updated in September 2024 and July 2025. References from selected papers were also screened for additional relevant publications. Selection criteria included date of publication since year 2000, human subjects and English language. In vivo or in vitro studies and individual case reports were excluded. References were analysed for the strength of evidence using the Oxford Levels of Evidence (OCEBM).⁸

Recommendations formulation

The recommendations summarized in Table 1 are based on the highest quality available evidence (classified by Oxford levels of evidence), supplemented by expert opinion and consensus, and graded using the GRADE system.⁹ Strength of recommendations was classified as shown in Table 2. The evidence supporting each recommendation, the levels of evidence and the level of consensus are summarized in Table S1.

Consensus-building process

Contributing experts produced an initial draft. A hybrid consensus meeting was held subsequently in Sitges, Spain on 11 May 2024, where 43 participants revised the draft and the recommendations.

A second online meeting was held on 29 January 2025, where 29 participants, lead authors of each section, further revised the manuscript and produced the final version of the recommendations, requiring a minimum agreement rate of 90%. Recommendations failing this threshold were eliminated or reformulated. Final consensus on the recommendations and the management algorithm (Figure 1) was achieved in February 2025 via anonymized online voting by 44 experts using Google Forms. Agreement rates are shown in Table S1.

The manuscript, including literature updates, was finalized subsequently by all co-authors via email.

DEFINITION

Lentigo maligna represents a particular form of MIS, developing on chronically sun-damaged skin, usually on the head and neck, in the elderly. It manifests as a slowly enlarging, irregularly pigmented macule or patch. Histopathologically, it displays atypical melanocytic proliferation with mild cytologic atypia along the basal epidermal layer, often extending down adnexal structures (follicular epithelium), on a background of solar elastosis.¹ If untreated, LM can progress to LMM. Historically, terms such as Dubreuilh's melanosis circumscripta praecancerosa and Hutchinson's melanotic freckle have been used to denote this intraepidermal precursor to invasive melanoma.^{7,10}

EPIDEMIOLOGY

LM has a distinct epidemiologic pattern among melanoma subtypes. Incidence peaks at 65–80 years, with a female predominance (1.7:1), and lesions typically arise on sun-damaged head and neck skin, predominantly in whites.¹¹ SEER data (2000–2019) show a sharp rise in melanoma incidence, with the largest increase reported for LM.¹¹ In some areas, LM now surpasses superficial spreading melanoma as the commonest melanoma in situ, accounting for up to 75% of cases, whereas LMM remains relatively rare—4%–15%

TABLE 1 Summary of recommendations for the management of LM.

Recommendation	Strength
Recommendation 1. Diagnosis	Strength
Clinical examination and dermoscopy shall be used for the differential diagnosis between facial pigmented lesions.	Grade A
Recommendation 2. Diagnosis	Strength
The established LM dermoscopic criteria, including the "inverse approach," shall be used for diagnosis.	Grade A
Recommendation 3. Diagnosis	Strength
RCM examination, when available, should be performed to diagnose LM, for clinically and dermoscopically equivocal lesions	Grade B
Recommendation 4. Diagnosis	Strength
Dermoscopy and, when available, RCM may help in identifying areas of invasion in LM	Grade C
Recommendation 5. Non-invasive margins delineation	Strength
Wood's light may be used for the pre-surgical evaluation of margins in LM	Grade C
Recommendation 6. Non-invasive margins delineation	Strength
Dermoscopy may be used for pre-surgical evaluation of margins in LM	Grade C
Recommendation 7. Non-invasive margins delineation	Strength
Reflectance confocal microscopy should be used for pre-surgical evaluation of margins in LM, when available	Grade B
Recommendation 8. Histopathological diagnosis	Strength
The definitive diagnosis of LM shall be determined through histopathological evaluation	Grade A
Recommendation 9. Histopathological diagnosis	Strength
Detailed clinical information, preferably with photographs of the lesion, should be provided to the pathologist	Grade B
Recommendation 10. Biopsies techniques	Strength
Excision OR partial biopsies shall be used for the pathological diagnosis of suspected LM	Grade A
Recommendation 11. Biopsy techniques	Strength
Dermoscopy, and when available, RCM should guide the site selection for partial biopsies	Grade B
Recommendation 12. Treatment	Strength
Complete surgical excision of LM shall be performed to achieve negative histopathological margins.	Grade A
Recommendation 13. Treatment	Strength
Cryotherapy is not recommended for the treatment of LM	Grade B
Recommendation 14. Treatment	Strength
Laser therapy is not recommended for the treatment of LM	Grade B
Recommendation 15. Primary treatment	Strength
When surgical excision of LM is not feasible or desirable, radiotherapy should be considered as an alternative treatment	Grade B
Recommendation 16. Primary treatment	Strength
When surgical excision of LM is not feasible or desirable, topical imiquimod should be considered as an alternative treatment	Grade B
Recommendation 17. Adjuvant treatment	Strength
Topical Imiquimod should be considered as an adjuvant treatment after excision of LM with negative narrow margins (<2mm histopathologically)	Grade B
Recommendation 18. Adjuvant treatment	Strength
LM excised with positive margins should be treated with re-excision OR imiquimod OR radiotherapy.	Grade B
Recommendation 19. Neoadjuvant treatment	Strength
Topical imiquimod may be used for the neoadjuvant treatment of LM	Grade C
Recommendation 20. Active surveillance	Strength
For LM excised with positive margins, active surveillance may be used in selected cases	Grade C
Recommendation 21. Follow-up	Strength
Periodical clinical and dermoscopic follow-up shall be performed to identify local recurrences, disease progression and new primary tumors	Grade A

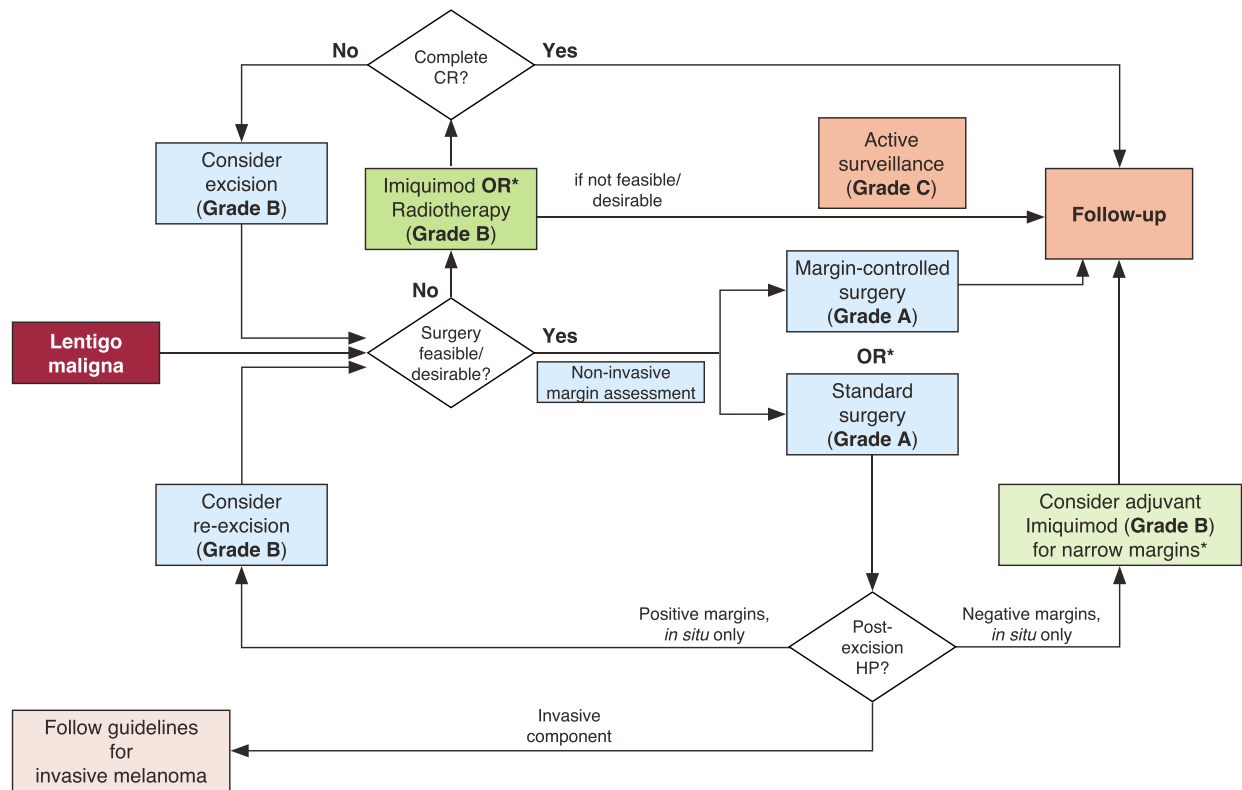
of invasive melanomas.^{12,13} The rising LM incidence is attributed to an aging population, increased UV exposure, improved diagnostic accuracy, and greater awareness. The

greater increase of LM incidence compared to LMM suggests a major role for early detection.^{14,15} Risk factors for LM include cumulative UV exposure, fair skin, actinic damage

TABLE 2 Recommendations grading.

Recommendation grade	Significance	Syntax
A	Strong recommendation	'shall'
B	Moderate recommendation	'should'
C	Weak recommendation	'may/can'
0	Recommendation pending. Currently not available or not sufficient evidence to make a recommendation in favor or against.	

Note: Strength of recommendations was graded based on the GRADE system.⁹



* See text for additional conditions/criteria of selection
CR, clinical remission; HP, histopathology.

FIGURE 1 Algorithm of LM management. +++ Grade A recommendation; ++ Grade B recommendation; + Grade C recommendation; *See text for additional conditions/criteria of selection; CR, clinical remission; LM, lentigo maligna; HP, histopathology; consensus rate: 95.3%.

and prior nonmelanoma skin cancer; prevalence is higher in regions of intense UV radiation (e.g. Australia, New Zealand, parts of the USA).^{16,17}

MOLECULAR CLASSIFICATION

WHO classifies LM in the ‘pathogenic pathway 2’, associated with cumulative sun-damage (CSD), high tumour mutation burden (TMB) and the UVR signature of C>T and CC>TT transitions.¹ LM may harbour driver mutations similar to other cutaneous melanomas, that is, *NRAS*, *BRAF* and *NFI*, or be triple-wild type. Multiple genetic aberrations, including *TERT* promoter mutations, *CDKN2A*

loss and Cyclin D1 amplifications, are frequently found. Amplifications or mutations in *KIT* occur in a subset of cases.^{18,19}

NRAS Q61 mutations are frequent in high CSD melanomas. *BRAF* mutations, overall present in up to 66% of melanomas, are less frequent in LM and often differ from the classic V600E substitution, although they still activate MAPK signalling.^{20,21} *NFI* mutations occur in approximately 15% of cutaneous melanomas, are associated with a strong UV signature and a high TMB and often co-occur with *RAS* alterations.²²

Despite proposed molecular progression models in melanoma,²¹ no specific molecular evidence for progression from LM to LMM has been found.

PROGNOSIS

LM progression to invasive LMM

Untreated LM can progress to LMM, but the rate and timing remain uncertain due to limited prospective monitoring studies. Reported progression rates range from 2% to 50% over 0–50 years.^{7,23} A SEER analysis estimated a lifetime risk of 2.2%–4.7% (annual risk 0.03%–0.14%).²⁴ A recent Australian prospective study found an annual progression rate of 3.5% and mean time to progression 28.3 years (95% CI: 20.0–40.5).²³ Progression appears non-linear and is influenced by age and lesion biology, making individual outcomes unpredictable.

LM mortality

Like other melanoma in situ (MIS), LM is rarely life-threatening. A SEER study of 137,872 MIS patients (mostly LM) reported 15-year melanoma-specific survival of 98.4% (95% CI, 98.3–98.5) and relative survival of 112.4% (95% CI, 112.0–112.8).²⁵ The melanoma-specific SMR was 1.89, whereas all-cause SMR was lower than the general population (0.68), likely reflecting increased medical surveillance. Mortality increased with age (7.4% in ≥ 80 vs. 1.4% in 60–69; adjusted HR 8.2, 95% CI 6.7–10.0).²⁵

A Swedish study found similar results²⁶: 10-year overall survival 77% in MIS patients vs. 72% in controls, lower mortality in women (HR 0.88) and slightly lower in men (HR 0.94). Patients had higher socio-economic status and fewer comorbidities, yet melanoma-related mortality remained 10-fold higher than in the general population.

LM patients have increased *risk of subsequent melanomas and skin cancers*. In SEER analysis, 4.3% of MIS patients developed a second primary invasive melanoma and 7.4% a second primary MIS.²⁵ A second invasive melanoma increased melanoma-specific mortality (HR 4.1, 95% CI 3.6–4.6), whereas a second MIS reduced it (HR 0.7, 95% CI 0.6–0.9).²⁵ Overall, MIS confers low melanoma-specific mortality, but higher than the general population. Age and progression to invasive melanoma are the main prognostic factors.

DIAGNOSIS

Clinical presentation

LM usually presents as a slow-growing solitary macule or patch with irregular borders and variable pigmentation, light brown to black, though amelanotic/hypomelanotic variants occur, especially in fair-skinned individuals.⁷ Over three-quarters arise on the head and neck, with subsite distribution varying by sex.²⁷ In a retrospective European series of 200 cases²⁸ cheek was the most common site (53.7%) and associated with female sex, whereas

scalp and nasal lesions (especially ala and tip) were twice as frequent in men. Solitary smaller macules on otherwise normal skin were linked to younger age (mean 67.7 ± 12.7 years), while lesions with surrounding freckles occurred later (mean 71.3 ± 11.6 years).

LM has to be clinically differentiated from solar lentigo (SL), lentigo simplex, ink spot lentigo, macular seborrheic keratosis (SK), pigmented actinic keratosis (PAK), lichen planus-like keratosis (LPLK) and pigmented superficial basal cell carcinoma. Furthermore, LM needs to be differentiated from invasive LMM and desmoplastic melanoma, which also arises on CSD skin and may associate with overlying LM.⁷ Clinical and dermoscopic photographic documentation is strongly recommended to facilitate clinical-histopathological correlation, treatment monitoring and follow-up.

Non-invasive imaging techniques for LM diagnosis

Dermoscopy

Dermoscopy significantly improves LM clinical diagnosis.^{29,30} Pigmented facial lesions typically show the so-called ‘pseudonetwork’,³¹ defined as structureless pigmentation interrupted by the non-pigmented follicular openings. The pseudonetwork corresponds to a hyperpigmented basal layer and is an unspecific feature.^{30–33} A progressive dermoscopic model has been proposed for LM,³⁰ based on the presumption that the LM arises from melanocytic stem cells of the hair follicles.³⁴ Thus, early LM displays asymmetric follicular openings, ‘circle within a circle’ around the follicle openings, or perifollicular linear projections (PLP) emanating radially from the follicle.^{30,35,36} With progression, grey dots, globules and streaks around the follicle aggregate in an annular-granular pattern.³⁷ Subsequently, streaks become longer and intersected, forming rhomboidal structures (i.e. angulated lines between hair follicles). When dermal invasion occurs (LMM), rhomboidal structures become broader and follicular openings are progressively obliterated by black or blue blotches. White scar-like and milky-red areas may also appear in amelanotic/hypomelanotic LM/LMM.³⁸ The dermoscopic features of LM are summarized in [Table 3](#).

Early dermoscopic LM features are often subtle, focal and challenging to recognize.³⁹ In addition, there is a significant overlap with features observed in PAK, SL, SK, and LPLK.⁴⁰ To address this problem, several quantitative models have been proposed.^{41,42}

A more intuitive alternative is the *inverse approach*, which relies on the identification of six non-melanoma criteria⁴³ ([Table 4](#)). The predominant presence of at least one of these features strongly suggests the diagnosis of SL/SK or PAK. Lesions lacking these features should be considered suspicious for LM.^{31,43} This approach was shown to improve sensitivity for LM from 51.5% to 83.6%, with specificity stable at approximately 85%.⁴⁴

TABLE 3 Dermoscopic criteria for the diagnosis of lentigo maligna.³⁹

Asymmetric pigmented follicular openings
Slate gray dots
Slate gray globules
Rhomboidal structures
Annular- granular pattern
Gray brown streaks
Dark/blue homogenous area
White scar-like areas
Milky red areas
Increased density of the vascular network
Red rhomboidal structures
Target-like patterns
Darkening at dermoscopic examination
Circle within a circle
Zigzag pattern
Perifollicular linear projections

Reflectance confocal microscopy

Used as a *second-line tool after dermoscopy*, RCM markedly improves sensitivity and specificity for LM/LMM. RCM helps distinguish LM from other facial pigmented lesions with atypical or equivocal dermoscopic features, evaluating amelanotic or hypomelanotic lesions, delineating the margins of LM preoperatively and guides biopsy of suspicious areas within larger lesions.^{45–48}

RCM features suggestive of LM include widespread atypical pagetoid cells (large round or dendritic hyperreflective cells in the upper epidermis), junctional atypical cells and nests, disruption of the dermal-epidermal junction with melanocytic proliferation, and atypical follicular melanocytic infiltration.^{47,49–51} A proposed RCM diagnostic score distinguishes LM from benign macules with a sensitivity of 85% and specificity of 76%⁵² (Table 5).

A meta-analysis on 498 patients reported RCM sensitivity 0.93 (95% CI: 0.85–0.97) and specificity 0.89 (95% CI: 0.81–0.94) for LM.⁵³ A later meta-analysis on 479 subjects found a higher specificity of RCM versus dermoscopy for LM (mean difference, MD, 19.10; 95% CI, 0.93–37.28, $p=0.04$) and a *trend to higher sensitivity* (MD: 14.56; 95% CI: 0.29–28.83; $p=0.05$).⁵⁴ RCM should be used *after dermoscopy* to maximize diagnostic yield. Its clinical use is limited by equipment cost, a steep learning curve and required expertise.

Wood's lamp

Wood's lamp examination offers a simple, inexpensive, non-invasive adjunctive tool for the evaluation of facial pigmented lesions. It may enhance the visualization of LM, the assessment of poorly defined margins, selection of biopsy site and surgical plan.^{55–57} It is less useful for amelanotic/hypomelanotic lesions, in heavily sun-damaged skin, where it can overestimate margins, and in deeper lesions.

TABLE 4 The dermoscopic “inverse approach” for the diagnosis of lentigo maligna.⁴³

Non-melanoma dermoscopic feature	Suggested diagnosis
Scales (pigmented or non-pigmented)	Actinic keratosis
White and wide follicular opening	Actinic keratosis
Erythema	Actinic keratosis
Reticular or parallel brown lines	Solar lentigo/seborrheic keratosis
Sharply demarcated border	Solar lentigo/seborrheic keratosis
Milia-like cysts/comedo-like openings	Solar lentigo/seborrheic keratosis

Note: The presence of one (or more) of these structures visible on dermoscopy as a predominant feature in the lesion is highly suggestive of actinic keratosis or solar lentigo/seborrheic keratosis. If none of these criteria can be seen as a predominant feature, then the lesion is assessed as suspicious for LM.

TABLE 5 RCM score for LM diagnosis.⁵²

	RCM features
Major criteria (+2 points each)	Non-edged papillae Round large pagetoid cells > 20 µm
Minor criteria (+1 point each)	≥3 atypical cells at DEJ in five 0.5 × 0.5 mm fields Follicular localization of atypical cells Nucleated cells in dermal papillae
Negative criterion (-1 point)	Broadened honeycomb pattern

Note: Score ≥2 indicates likely LM with sensitivity 85%, specificity 76%.

Non-invasive differentiation between LM and invasive LMM

Three studies have investigated dermoscopic features to discriminate LM from LMM.^{58,59}

The presence of <3 colours, light brown colour, angulated lines and a patchy network were associated with LM. By contrast, the presence of >2 colours, pink colour, rhomboidal structures, obliteration of hair follicles, shiny white structures, blue-white veil, black colour, irregular blotches and atypical vessels were linked to LMM.

Three RCM features were suggested to differentiate LM from LMM: epidermal and junctional disarray, large size of melanocytes and nests of melanocytes.⁶⁰ In another study, medusa head-like structures, dermal nests and nucleated cells within the dermal papillae were significantly associated with LMM.⁴⁷

Non-invasive margins estimation for lentigo maligna

LM often presents with ill-defined borders on the background of sun-damaged skin. The frequent subclinical extension drives a higher risk of incomplete surgical excision and higher post-surgery recurrence rates compared to other melanoma subtypes. One study reported a 21% rate of

histologically positive margins despite 6 mm clinical excision margins.⁶¹

Wood's lamp examination may help detect subclinical extension by enhancing pigment contrast, but it may overestimate margins in heavily sun-damaged skin or underestimate them in amelanotic/hypomelanotic lesions.^{56,57,62}

Dermoscopy of the peripheral marginal area of LM displays a thin-pigmented mesh or homogeneous brown areas, rather than the classic LM criteria, which predominate centrally. In a study of 26 LM/LMM cases, dermoscopy identified broader margins than Wood's lamp, which in turn highlighted broader margins than clinical evaluation.^{56,62}

RCM is the most accurate non-invasive tool for assessing LM subclinical spread. Features indicating margin involvement include atypical dendritic cells emerging from the lesion's trailing edge, the presence of ≥ 1 round cell $>20 \mu\text{m}$ in size or ≥ 3 dendritic or round cells regardless of cellular size connected to the main tumour.^{52,63}

A systematic review with 329 patients reported a 90% negative predictive value for RCM evaluation of margins involvement.⁶⁴ A meta-analysis including six studies with RCM showed that handheld-RCM decreased significantly both the rate of positive histopathological margins and the required number of stages in staged excisions.⁶⁵ The application of hand-held-RCM in pre-operative margin estimation is facilitated by using localization aids such as paper rings, surgical pens or superficial skin incisions.^{63,66–68}

Histopathologic diagnosis

Histopathology remains the diagnostic gold standard for LM. LM exhibits a lentiginous proliferation of atypical melanocytes along the basal epidermis, with hyperchromatic, irregular, usually spindle-shaped nuclei.^{7,69} The epidermis is typically flattened. Most cases exhibit minimal nesting, although some variants show rete ridge bridging. Follicular epithelium involvement is common and corresponds to dermoscopic grey circles.^{70,71} Surrounding skin shows UV-induced changes (solar elastosis, solar lentigines, papillary dermal melanophages corresponding to dermoscopic grey dots).^{69,72}

In partial biopsies, pagetoid tumour cell spread or moderate-to-strong dermal inflammation is significantly associated with the final diagnosis of invasive LMM.^{73,74} Pagetoid configuration is uncommon in LM and may prompt additional biopsies or immunostaining to avoid missing an invasive component.

Immunohistochemistry

If LM is suspected, immunohistochemical staining is recommended for diagnostic confirmation and margin control. Stains such as Melan-A (MART1), MITF, PRAME and

SOX10 help evaluate melanocyte number, arrangement, spread and morphology.^{75–79} Interpretation should be correlated with clinical findings and haematoxylin–eosin staining, as Melan-A, MITF and SOX10 may also highlight melanocytic pseudo-nests in lichenoid inflammation (e.g. LPLK), mimicking LM. Differentiating LM from SL- or UV-induced melanocytic hyperplasia (MH) is challenging, underscoring the necessity of thorough margin evaluation and clinical context to avoid misdiagnosis; MH often shows epithelioid melanocytes with vesicular nuclei and pigmented basal layer, unlike the reduced pigment from defective melanogenesis typically seen in LM.⁷⁷ PRAME can help assess excision margins.^{78–80}

Pathological assessment on frozen sections in Mohs surgery

Histopathologic evaluation of LM using frozen sections during Mohs micrographic surgery (MMS) is challenging and generally less accurate than for epithelial cancers,⁸¹ partly because freezing artefacts can obscure tissue architecture and cellular detail. Immunohistochemical staining improves MMS by increasing diagnostic accuracy and margin control.⁸² Ex vivo RCM, combined with immunofluorescence for melanocytic markers, is a promising new tool for postoperative margin assessment.⁸³

Biopsy techniques

Pre-biopsy clinical photography including anatomical landmarks is recommended to avoid site misidentification on follow-up.⁸⁴

Excisional biopsy (full-thickness, large punch or deep saucerization) is preferred for suspected melanoma, ideally with 1–3 mm margins of clinically/dermoscopically normal skin and >1 mm depth to enable accurate Breslow index measurement and T classification. The clinical and dermoscopic examination should guide the choice of biopsy technique.^{85,86}

In anatomically or cosmetically sensitive areas (e.g. eyelids, ears), large lesions or when non-surgical treatments (e.g. imiquimod) are planned, partial biopsies may be appropriate.⁸⁷ Shave biopsy allows examining larger areas, which is crucial for diagnosis of solitary or collision lesions but should be deep enough to assess dermal invasion. Generally, partial biopsies risk sampling bias due to limited area.⁸⁸ Ng et al.⁸⁹ reported false negative rates of 2.7% for excisional, 4.5% for shave and 23.3% for punch biopsies. Rates were lower for LM and head/neck melanomas (OR 1.3 and 1.0, respectively), supporting partial biopsies in those contexts. Multiple punch biopsies from suspicious areas, preferably guided by dermoscopy or RCM, can reduce false negative rates—three or four biopsies lower the probabilistic risk to 1.2% and 0.4%, respectively.

Clinician–pathologist collaboration

Accurate and reproducible diagnosis requires proper biopsy, comprehensive clinical information, pathologist expertise and strong clinicopathological correlation.⁷²

Essential clinical data include the patient's age, lesion's anatomical site, size, differential diagnoses, type of biopsy, previous therapies and prior biopsy results. If only partial biopsies were taken, clinical and dermoscopic photographs of the entire lesion are mandatory.

The pathologist's report should state the presence or absence of margin involvement after excision and specify macroscopic sectioning technique as this affects confidence in histologic margins assessment.⁹⁰

TREATMENT

Management of LM was historically surgical, but growing evidence now supports also the use of conservative therapies. The expanding treatment options warrant a multidisciplinary approach and shared decision-making with patients and caregivers.⁹¹ Management should be patient-centred, weighing comorbidities, risks and preferences, since many patients are elderly, frail or unable to tolerate extensive surgery or prolonged conservative treatment.

Primary treatment

Surgical treatment

No randomized trials compared surgical versus non-surgical treatments, nor do trials compare conventional excision, staged excision and MMS for LM. Nonetheless, guidelines from Europe, the United States and Australia consider conventional surgical excision with 5–10 mm clinical margins first-line for LM.^{4,84,92}

LM's subclinical spread and background atypia on chronically sun-damaged skin impede accurate margin estimation and often cause incomplete excision; a meta-analysis found 17% incomplete excisions with conventional 5-mm margins.⁶⁵ Risk factors for incomplete excision are sparsely studied, but head/neck LM with ill-defined borders or diameter ≥ 2 cm often requires larger margins, staged excision or MMS.⁶¹

Margin-controlled techniques (MCS) reduce incomplete excisions and likely recurrence. A meta-analysis of head/neck melanoma in situ (not LM-specific) reported local recurrence rates of 3.3% after conventional wide local excision, 1.3% after staged excision (including slow Mohs), and 0.7% after MMS, with mean follow-up of 3–5 years.⁹³

Intraoperative margin control uses fresh frozen tissue (MMS) or paraffin-embedded sections for 'slow Mohs' and other staged excision variants like mapped excisions, square method, perimeter technique, geometric staged excision, spaghetti technique and staged radial sections.^{94–99} Wider

adoption of MCS is limited by longer operations, higher costs and required expertise.

Dermoscopy, Wood's lamp and RCM improve preoperative margin delineation; postoperative immunostaining (notably nuclear markers MITF or SOX10) enhances histopathologic margin assessment.^{57,66,77,82,100}

Other ablative techniques

Various ablative modalities have been investigated for LM treatment. A major limitation is the lack of confirmed histological clearance, which increases the risk of recurrence. Although initial clinical outcomes may suggest lesion resolution, recurrence after months or even years is not uncommon.

Cryotherapy

Melanocytes are more cold-sensitive than keratinocytes, making cryotherapy a theoretical option. In a series of 30 patients (LM diameter 1.3–4.5 cm), aggressive open-spray cryotherapy with double freeze–thaw cycles at -40 to -50°C and ≥ 1 cm treatment margins (wider if ill-defined) produced a 6.6% recurrence rate at 3 years.¹⁰¹ The technique is simple and often cosmetically favorable but lacks histopathologic confirmation of clearance.¹⁰² Only ~10% of international experts view cryotherapy as a viable alternative to surgical excision.⁹⁰

Laser therapy

Several laser-based techniques have been used for LM treatment, including CO₂, argon, Q-switched ruby, Nd:YAG, alexandrite and their combinations.^{103,104} Available evidence is limited to anecdotal reports and small case series. A systematic review including nine studies (61 patients) reported a recurrence rate of 34.4%.¹⁰⁵ Combination of CO₂ laser with imiquimod did not increase the efficacy of CO₂ laser alone, with recurrence rates of approximately 50% at 6.8 years, despite initially favourable clinical response.¹⁰³

Laser therapy (notably CO₂ and 2940-nm Er:YAG) has been used when standard treatments are contraindicated or declined, but evidence for efficacy is limited.⁹² Due to high recurrence and poor margin control—likely from inadequate deep dermal penetration—clinical guidelines and our expert consensus do not recommend cryotherapy or laser for LM.^{6,27,90}

Radiation therapy

Radiation therapy (RT) is an option for large LM, when surgery would cause unacceptable functional/cosmetic deficits, and as adjuvant treatment for positive margins when further

surgery is not feasible.¹⁰⁶ Gross tumour volume can be estimated by dermoscopy, Wood's lamp, or more precisely by RCM.

Evidence was largely retrospective until a recent phase 3 randomized trial of RT vs. imiquimod in 126 patients with complex, non-surgical LM.¹⁰⁷ RT achieved a 95% biopsy-based response at 6 months but a 24% failure rate at 24 months; treatment was well tolerated. In a cohort of 593 patients treated with Grenz rays as primary therapy, partial surgery+RT, or radical excision + postoperative RT, clearance rates were 83%, 90% and 97%, respectively, at ~5 years median follow-up.¹⁰⁸

NCCN suggests regimens such as (i) 50–57.5 Gy in 20–23 fractions (4–5 weeks); (ii) 35 Gy in 5 fractions over 1 week for fields <3 cm²; (iii) 32 Gy in 4 fractions per week.³ Longer fractionation (≈2 Gy/fraction to 50–56 Gy) improves long-term cosmesis by reducing fibrosis. Radiotherapy-induced long-term skin changes occur in up to ~20% of patients. Radiation energy and technique should be tailored to lesion size, contour, and location. Clinical target volume generally adds 5–10 mm to the gross tumour volume, and superficial radiation to ~5 mm depth is typically used to treat follicular structures.¹⁰⁶

Topical treatment

Imiquimod

Imiquimod 5% cream is the most extensively studied topical treatment for LM. Imiquimod stimulates innate cutaneous immunity and the cytotoxic arm of the adaptive immune response.¹⁰⁹ It has frequent local and rare systemic adverse effects including erythema, erosions, ulcerations, vesicles, crust, pruritus and pain, flu-like systemic syndrome or distant inflammatory mucosal reactions.^{109,110}

Multiple studies report benefits of imiquimod for LM, but methodological heterogeneity and short follow-up have prevented strong evidence and clear recommendations.

A recent RCT comparing radiotherapy to 5% imiquimod showed a 95% response rate at 9 months post-randomization for imiquimod, with a 10.5% recurrence rate at 27 months versus 24% for radiotherapy.¹⁰⁸ The difference was not statistically significant due to under-recruitment during the SARS-CoV-2 pandemic, though the trend favoured imiquimod; RCM-measured treatment failure was significantly lower with imiquimod. The regimen was five applications/week for 12 weeks, with dosing adjusted for inflammation.^{108,110}

Four systematic reviews have evaluated imiquimod for LM.^{105,111–113} Vaienti et al.¹¹² reviewed 87 studies (1803 lesions), finding 62.8% overall clearance (56.9% histologic, 43.2% clinical); 107 lesions relapsed. Mora et al.¹¹¹ analysed 347 tumours from 45 studies, reporting 78.3% clinical and 76.2% histologic complete clearance; clinical recurrence was 2.3%, and longer regimens (>60 applications or >5/week) improved histologic clearance.

In conclusion, most studies report high clinical and histologic clearance and low recurrence with imiquimod, whether as primary therapy or for incompletely excised LM. Although long-term comparative data are limited, existing

evidence supports using imiquimod as an alternative primary treatment for selected patients when surgery is infeasible or undesirable. A regimen totaling at least 60 applications over ~12 weeks is recommended, with adjustments for side-effect intensity and extent.¹¹⁰

Imiquimod is not licensed for periocular use due to potential side effects (most commonly conjunctivitis and keratitis). Rare but serious complications include infective keratitis and preseptal cellulitis, with transient punctate keratitis and temporary blurred vision also reported. Scientific evidence and authors' experience suggests that imiquimod may also be used also periocular, with close supervision by a multidisciplinary team, with ophthalmology review at treatment initiation and as required thereafter. Ocular stinging and conjunctivitis are usually temporary and resolve after discontinuation of imiquimod. Topical antibiotics and corticosteroids are often used to support treatment continuation.^{110,114}

Topical retinoids

In one RCT,¹¹⁵ 90 patients with 91 LMs received either imiquimod 5% cream (5 days/week) or imiquimod plus tazarotene 0.1% gel (2 days/week) for 3 months, followed by staged excision to confirm margin clearance. In the monotherapy group (47 LMs), 42 completed the treatment, with a 64% complete response rate. In the combination group (44 LMs), 37 completed the treatment, with a 78% response rate; the difference was not statistically significant ($p=0.17$). No recurrences were observed after a mean follow-up of 42 months.

Ingenol mebutate and 5% 5-fluoro-uracil

Coleman et al.¹¹⁶ reported no benefit for topical 5% 5-fluorouracil in the treatment of LM. Montaudiè et al.¹¹⁷ performed a prospective single-arm phase 2 trial of Ingenol mebutate to treat LM and found no benefit.

ADJUVANT TREATMENT

Imiquimod 5% cream

Current evidence supports adjuvant imiquimod after surgery for LM. A retrospective multicentre study of 149 patients reported a 5.6% recurrence rate at mean follow-up 32.5 months for surgery followed by imiquimod (7×/week for 6 weeks), with no difference between narrow (<5 mm) and wider (>5 mm) clinical margins.¹¹⁸ When imiquimod was used for LM with positive excision margins, recurrence was 9.1% at mean follow-up 34 months after a mean treatment duration of 7.9 weeks.¹¹⁸

In a retrospective study including 63 patients with LM, 41 received adjuvant imiquimod (3–5×/week for 12 weeks) after surgery with narrow clinical or histologically positive margins.¹¹⁹ Clinical clearance was achieved in 94.4% after a mean follow-up of 43.1 months. Inflammation correlated significantly with clearance in primary, but not adjuvant, settings ($p=0.01$).

Kwak et al.¹²⁰ reported 93% clearance in 71 patients receiving adjuvant imiquimod; positive margins had lower clearance (83.3% vs. 100%, $p=0.01$) and treatment-associated inflammation correlated with higher response (94.1% vs. 66.7%, $p=0.02$). Additional case series showed similar benefits of adjuvant imiquimod after surgery.^{121,122} Thus, adjuvant imiquimod should be considered for patients with positive or narrow margins.

Radiotherapy

Hedblad et al.¹²³ treated 593 patients with LM/early LMM with Grenz ray therapy across different clinical scenarios: primary treatment ($n=350$), post-partial excision ($n=71$) and post-radical excision as prophylaxis ($n=172$). The complete clearance rates were 83%, 90% and 97%, respectively. Follow-up was >2 years in 425 patients, and >5 years in 241.

NEOADJUVANT TREATMENT

Topical imiquimod has been explored as a neoadjuvant therapy to reduce LM size before surgery, in order to render inoperable lesions resectable, or minimize surgical consequences. In a prospective study,¹²⁴ 334 LM patients received imiquimod 5 times weekly for 3–4 months (60 applications), followed by staged excision, starting with a 2 mm clinical margin. The average margin required for clearance was 3.5 mm, but 81% of cases were tumour-free after the first stage. The recurrence rate was 3.9% at 5.5 years, suggesting outcomes comparable to surgery alone, but with smaller defects.

A RCT¹⁰⁹ randomized 283 patients to either 4 weeks of daily imiquimod or placebo, followed by 5-mm margin excision. While no difference in the rate of positive margins was observed, lesion size significantly decreased in the imiquimod group, offering potential cosmetic benefits.

Neoadjuvant imiquimod carries risks of skip areas and requires prolonged (1–3 month) treatment with local side effects (pruritus, pain, inflammation); its impact on recurrence appears modest, but it may be useful to improve cosmesis in selected or anatomically challenging cases.

ACTIVE SURVEILLANCE

Active surveillance can be considered for selected LM patients who are elderly, frail or have severe comorbidities that preclude surgery or long-term topical therapy or for small early lesions in noncritical sites (excluding eyelids, ear, etc.). Decision should incorporate patient status, preferences, and goals.⁹¹ These patients require close clinical and dermoscopic monitoring and education of patients/caregivers for self-examination and prompt reporting of suspicious changes.^{3,4,125}

The recommendations for LM treatment are summarized in Figure 1.

FOLLOW-UP OF LM

Post-treatment follow-up for LM is essential for assessing treatment's outcomes and side effects, early detection of recurrence and secondary skin cancers and patients and family education on prevention and early detection.

LM carries a higher local recurrence risk than other MIS types, with rates up to 40% depending on treatment modality and margin status. Risk is higher after excisions with narrow margins (<0.2 mm histopathologically) versus wider ones (>0.5 mm histopathologically).¹²⁶ Chen et al.¹¹ reported a 0.94% cumulative incidence of progression to LMM after 10 years. Mean time to recurrence often exceeds 57 months. Median time to recurrence or re-treatment was 3.3 years, shortened to 1.7 years for second and 0.5 year for third recurrences.

Combining clinical inspection, Wood's lamp, dermoscopy and RCM aids detection of early recurrences or residual disease. Wood's lamp highlights residual or recurrent pigmentation.⁵⁷ Dermoscopy is routinely used in follow-up. Early recurrence signs include new or subtle homogeneous brown pigmentation and perifollicular pigmentation, but up to 95% of recurrent LM may lack classic dermoscopic features. Bluish-grey pigmentation may reflect transient melanophagia after successful topical treatment, rather than recurrence.¹²⁷

Baseline clinical and dermoscopic imaging of adjacent uninvolved skin and the contralateral face is advised. Any new palpable lesion warrants biopsy.

RCM helps detect residual or recurrent LM, especially after non-surgical treatments. A validated LM score includes features such as non-edged papillae, large, round, pagetoid cells, atypical junctional cells and follicular involvement.^{128–131}

Melanoma patients are at increased risk to develop a second primary melanoma or other skin cancer. This risk is further increased for LMM patients and generally for melanomas located on the face and neck.^{132,133} This underscores the need for prolonged follow-up for LM.

Patient education should emphasize photoprotection, avoiding intentional sun exposure/tanning, regular self-examination, prompt reporting of changes near the scar or treatment area (especially in the first 2 years), surveillance for secondary skin cancers and preventive measures for family members.

No high-quality evidence defines optimal follow-up schedule/duration for LM^{5,6}; follow-up should be individualized based on tumour stage (in situ vs. invasive; primary vs. recurrent), treatment modality (surgery, topical, radiotherapy), margin status and patient's risk factors (history of sunburn, CSD, personal/family history of skin cancer).⁹⁰ Follow-up duration must consider the high recurrence risk, which can occur up to 10 years post-treatment (median

latency \approx 3.8 years).¹³⁴ Monitoring should include clinical and dermoscopic examination of the primary tumour site and surrounding skin, RCM when available, whole body skin examination and dermoscopy for suspicious lesions, symptoms evaluation.

PREVENTION

Primary prevention aims to reduce LM incidence by minimizing risk factors and promoting protective behaviours, especially in high-risk individuals. This benefits patients and may also mitigate the growing public health burden.^{16,135,136}

Chronic ultraviolet radiation (UVR) exposure is the primary risk factor for LM, with older age, cumulative sun exposure, history of sunburn, fair, freckled skin and occupational exposure contributing to the risk.^{11,137–140} Prevention should focus on UVR protection and avoiding excessive sun exposure. This includes avoiding intentional sunbathing/tanning, limiting outdoor activities during peak solar radiation hours and using combined photoprotection measures when sun exposure is necessary. These include natural or structural shade, wide-brimmed hats covering ears and neck, protective clothing for exposed skin areas and broad-spectrum sunscreens for uncovered sites.^{136,141}

High-risk individuals should also pursue secondary prevention through self-examination, dermatological screening and prompt search of care for suspicious changes. Physicians should educate patients and caregivers on early LM signs.¹⁴²

CURRENT CHALLENGES AND FUTURE TRENDS

Epidemiology

Data on LM incidence and outcomes—particularly in patients not undergoing surgery and those with darker skin—are sparse. The reported rising incidence may reflect improved surveillance or lower biopsy threshold rather than an actual prevalence increase. Comprehensive national and regional registries are crucial for clarifying disease trajectories, enhancing early detection and informing public health interventions.

Clinical diagnosis

LM is diagnosed clinically through physical examination, dermoscopy and RCM. Non-invasive imaging enhances biopsy accuracy and preoperative margin assessment. However, RCM availability remains limited, and no current preoperative test reliably confirms or excludes dermal invasion (LMM) in flat lesions. Future tools, such as AI-assisted diagnostics, may further refine accuracy. Addressing these challenges requires ongoing research, technological

innovation and comprehensive training to optimize LM management and outcomes.

Pathology

Diagnostic accuracy for LM and related melanocytic proliferations in sun-damaged skin is a challenge, requiring pathologists' expertise. Standardization in specimen processing and margin evaluation is needed. Enhanced pathology training and access to second opinions can mitigate diagnostic variability and improve care quality.

Prognosis

Predicting which LM may progress remains challenging and is based on clinical/pathologic features that indicate a possible invasive component missed on sampling (i.e., large lesions and lesions with rows of contiguous melanocytes in the presence of epidermal clefts or more than 25% of the epidermal component composed of nests).^{74,127} While combined clinical/molecular biomarkers are theoretically promising, no specific predictive markers emerged to date.

Treatment

Literature on LM treatment is constrained by limited prospective studies and short follow-up durations, despite evidence that half of recurrences occur more than 4 years post-treatment. Surgical excision with 5–12 mm margins has been recommended, though not supported by substantial evidence, and margin guidelines remain non-standardized, while facial anatomy often limits excision extent. MMS demonstrates low recurrence rates but is not widely available.

Evidence increasingly supports the use of topical imiquimod for LM, with clinical clearance up to 90%.¹⁰⁸ A small but not negligible 1.8% of patients developed LMM within 1 year after imiquimod treatment.¹¹³ It remains unclear whether this represents true progression of imiquimod-resistant aggressive LM, or pre-existing, undiagnosed invasive LMM. The roles of imiquimod as adjuvant or neoadjuvant therapy are promising but require confirmation in further prospective studies.

CONCLUSION

We present herein recommendations for LM diagnosis and management agreed by worldwide opinion leaders and experts, reflecting current knowledge.

Optimal care, especially for complex cases, requires a multidisciplinary approach, integrating dermatology, surgery, radiation oncology and dermatopathology expertise, together with a patient-centred assessment of health, quality of

life and goals. Treatment options should be weighed through shared decision-making with patients and carers, and clear communication among all team members is essential to ensure optimal personalized care.

AUTHOR CONTRIBUTIONS

All authors listed meet the ICMJE criteria, including: substantial contributions to conception, design, data generation, analysis and interpretation, drafting and critically revising the article for important intellectual content, final approval of the version to be published and all agree to be accountable for all aspects of the work in ensuring that questions related to the accuracy or integrity of any part of the work are appropriately investigated and resolved.

AFFILIATIONS

- ¹Carol Davila University of Medicine and Pharmacy Bucharest, Oncologic Dermatology Department, Elias University Hospital, Bucharest, Romania
- ²Health and Medical University Potsdam, Potsdam, Germany
- ³Gaeta, Private Practice, Formia, Italy
- ⁴Department of Dermatology, Medicine Faculty, Ankara University, Ankara, Turkey
- ⁵School of Medicine, Aristotle University of Thessaloniki, Thessaloniki, Greece
- ⁶Dermatology Unit, University of Campania, Naples, Italy
- ⁷University of Zurich, Zurich, Switzerland
- ⁸Dermatology Section, Instituto de Investigaciones Medicas "A. Lanari", University of Buenos Aires, Buenos Aires, Argentina
- ⁹Department of Dermatology, Universidad del Desarrollo-Clinica Alemana de Santiago de Chile, Santiago, Chile
- ¹⁰Dermatology Service, Pharmacovigilance Group, Medicine Department, Hospital Clinic, University of Barcelona, Barcelona, Spain
- ¹¹Melanoma Group - IDIBAPS, Barcelona, Spain
- ¹²Dermatology Section, Department of Medical, Surgical, and Neurological Sciences, University Hospital of Siena, Siena, Italy
- ¹³IDI-IRCCS, Dermatological Research Hospital, Rome, Italy
- ¹⁴Department of Life Science, Health, and Health Profession, Link University of Rome, Rome, Italy
- ¹⁵Department of Medicine, Institute of Dermatology, University of Udine, Udine, Italy
- ¹⁶Anatomic Pathology and Cytopathology Unit, Istituto Nazionale Tumori IRCCS Fondazione 'G. Pascale', Naples, Italy
- ¹⁷Department of Clinical and Experimental Medicine, Dermatology, University of Messina, Messina, Italy
- ¹⁸School of Medicine, Vita-Salute San Raffaele University, Milan, Italy
- ¹⁹Dermatology Clinic, IRCCS San Raffaele Hospital, Milan, Italy
- ²⁰Melanoma Institute Australia, University of Sydney, Sydney, New South Wales, Australia
- ²¹Sydney Melanoma Diagnostic Centre, Royal Prince Alfred Hospital, Camperdown, New South Wales, Australia
- ²²Dermatology Service, Department of Medicine, Memorial Sloan Kettering Cancer Center, New York, New York, USA
- ²³Private Practice, Hampshire, UK
- ²⁴Department of Dermatology and Venereology, Medical University of Graz, Graz, Austria
- ²⁵Dr Phillip Frost Department of Dermatology & Cutaneous Surgery, Sylvester Comprehensive Cancer Center, University of Miami Miller School of Medicine, Miami, Florida, USA
- ²⁶Derma Clinic Riga, Riga, Latvia
- ²⁷Department of Dermatology, Medical University of Vienna, Vienna, Austria
- ²⁸Department of Dermatology and Venereology, Graz University Hospital, Graz, Austria
- ²⁹Department of Dermatology and Venereology, Andreas Sygros Hospital for Cutaneous Diseases, Athens, Greece
- ³⁰Department of Dermatology, Peking Union Medical College Hospital, Chinese Academy of Medical Science and Peking Union Medical College, Beijing, China
- ³¹Dermatology Department, University of Modena and Reggio Emilia, Modena, Italy
- ³²Dermatology Department, Hospital Clinic Barcelona, Barcelona, Spain
- ³³Instituto Carlos III, CIBER de Enfermedades Raras, Barcelona, Spain
- ³⁴Memorial Sloan Kettering Skin Cancer Center, Hauppauge, New York, USA
- ³⁵Faculty of Medicine, Ain Shams University, Cairo, Egypt

- ³⁶Dermatology Clinical Management Unit, Hospital Virgen de la Macarena, Seville, Spain
- ³⁷Dermatology Unit, Department of Mental Health and Preventive Medicine, University of Campania "Luigi Vanvitelli", Naples, Italy
- ³⁸Instituto Valenciano de Oncologia, Valencia, Spain
- ³⁹Universidad Catolica de Valencia, Valencia, Spain
- ⁴⁰Department of Dermatology, School of Medicine, Pontificia Universidad Católica de Chile, Santiago, Chile
- ⁴¹Millennium Institute for Intelligent Healthcare Engineering, Santiago, Chile
- ⁴²Department of Dermatology and Venereology, Institute of Clinical Sciences, Sahlgrenska Academy, University of Gothenburg, Gothenburg, Sweden
- ⁴³Department of Dermatology and Venereology, Region Västra Götaland, Sahlgrenska University Hospital, Gothenburg, Sweden
- ⁴⁴Dermatology Unit, Department of Clinical Internal, Anesthesiological and Cardiovascular Science, Sapienza University, Rome, Italy
- ⁴⁵Dermatology, Dipartimento di Medicina e Chirurgia Traslazionale, Catholic University of the Sacred Heart, Rome, Italy
- ⁴⁶Dermatology Unit, Dipartimento di Scienze Mediche e Chirurgiche, Fondazione Policlinico Universitario A. Gemelli-IRCCS, Rome, Italy
- ⁴⁷Dermatology Department, Hospital Clínic de Barcelona, Universitat de Barcelona, IDIBAPS, Barcelona, Spain
- ⁴⁸Mayne Academy of General Practice, Medical School, The University of Queensland, Brisbane, Australia
- ⁴⁹Department of Dermatology, Medical University of Warsaw, Warsaw, Poland
- ⁵⁰Cairo Hospital for Dermatology & Venereology (Al-Haud Al-Marsoud), Ministry of Health & Population, Cairo, Egypt
- ⁵¹Department of General and Oncologic Dermatology, Ambroise-Paré Hospital APHP, Paris, France
- ⁵²EA 4340 "Biomarkers in Cancerology and Hemato-Oncology", UVSQ, Université Paris-Saclay, Boulogne-Billancourt, France
- ⁵³Dermatology Department, Hospital Provincial del Centenario de Rosario - Universidad Nacional de Rosario, Rosario, Argentina
- ⁵⁴Grupo Centro, Rosario, Argentina
- ⁵⁵Gray Faculty of Medical & Health Sciences, Tel Aviv University, Tel Aviv, Israel
- ⁵⁶The Kittner Skin Cancer Screening & Research Institute, Sheba Medical Center, Ramat Gan, Israel
- ⁵⁷Frazer Institute, The University of Queensland, Dermatology Research Centre, Brisbane, Queensland, Australia
- ⁵⁸Dermatology Unit, IRCCS Azienda Ospedaliero-Universitaria di Bologna, Bologna, Italy
- ⁵⁹Department of Medical and Surgical Sciences, Alma Mater Studiorum University of Bologna, Italy
- ⁶⁰Department of Dermatology II, Munich Clinic and University Munich, Munich, Germany
- ⁶¹Department of Dermatology, Mayo Clinic Arizona, Phoenix, USA
- ⁶²Department of Dermatology, Centre Hospitalier Lyon Sud, Lyon, France
- ⁶³Lyon1 - Claude Bernard University Lyon, France
- ⁶⁴Lyon Cancer Research Center, UMR INSERM U1052 CNRS 5286 UCBL1, Lyon, France
- ⁶⁵Department of Dermatology and Venereology, University of Trieste, Trieste, Italy
- ⁶⁶Lallas First Department of Dermatology, School of Medicine, Faculty of Health Sciences, Aristotle University, Thessaloniki, Greece

ACKNOWLEDGEMENTS

The authors thank Marco Spadafora for his valuable assistance in the editorial preparation of the manuscript. The publication of this article in OA mode was financially supported by HEAL-Link.

FUNDING INFORMATION

All authors completed this work voluntarily and did not receive any honorarium or compensation. The IDS covered part of the travel costs for participation in Consensus meetings.

CONFLICT OF INTEREST STATEMENT

Consortium members declare no conflict of interest related to this work. All authors stated their conflicts of interest in the relevant forms.

DATA AVAILABILITY STATEMENT

Data sharing is not applicable to this article as no datasets were generated or analysed during the current study.

ETHICAL APPROVAL

Not applicable; no human or animal research included.

ETHICS STATEMENT

Not applicable; no patients data included.

ORCID

Ana-Maria Forsea  <https://orcid.org/0000-0002-1007-7883>

Bengu Nisa Akay  <https://orcid.org/0000-0002-4896-1666>

Zoe Apalla  <https://orcid.org/0000-0002-9255-8196>

Giuseppe Argenziano  <https://orcid.org/0000-0003-1413-8214>

Giulia Briatico  <https://orcid.org/0000-0003-0421-3241>


Cristina Carrera  <https://orcid.org/0000-0003-1608-8820>

Claudio Conforti  <https://orcid.org/0000-0001-5126-8873>

Allan C. Halpern  <https://orcid.org/0000-0001-7320-1901>

Teresa Kränke  <https://orcid.org/0000-0001-8406-6063>


Konstantinos Liopyris  <https://orcid.org/0000-0001-9566-8238>

Jie Liu  <https://orcid.org/0000-0001-8219-2429>


Elvira Moscarella  <https://orcid.org/0000-0001-5160-8997>

Eduardo Nagore  <https://orcid.org/0000-0003-3433-8707>

Cristian Navarrete-Dechent  <https://orcid.org/0000-0003-4040-3640>

John Paoli  <https://orcid.org/0000-0003-1326-8535>

Giovanni Pellacani  <https://orcid.org/0000-0002-7222-2951>

Ketty Peris  <https://orcid.org/0000-0003-1957-6600>

Susana Puig  <https://orcid.org/0000-0003-1337-9745>

Lidia Rudnicka  <https://orcid.org/0000-0002-8308-1023>

Alon Scope  <https://orcid.org/0000-0001-9160-7411>

Michela V. Starace  <https://orcid.org/0000-0002-3981-1527>

Luc Thomas  <https://orcid.org/0000-0003-1995-2434>

Philipp Tschandl  <https://orcid.org/0000-0003-0391-7810>

Aimilios Lallas  <https://orcid.org/0000-0002-7193-0964>

REFERENCES

- Elder DE, Massi D, Scolyer RA, Willemze R. WHO classification of skin tumours. Lyon, France: IARC Press; 2018.
- Amaral TOM, Arance A, Blank C, Chiarion-Sileni V, Donia M, Dummer R, et al. Cutaneous melanoma: ESMO clinical practice guideline for diagnosis, treatment and follow-up. *Ann Oncol*. 2025;36(1):10–30.
- NCCN Guidelines Version 2.2025 Melanoma: Cutaneous. USA: NCCN; 2025.
- Garbe C, Amaral T, Peris K, Hauschild A, Arenberger P, Basset-Seguín N, et al. European consensus-based interdisciplinary guideline for melanoma. Part 2: treatment – update 2024. *Eur J Cancer*. 2025;215:115153.
- Garbe C, Amaral T, Peris K, Hauschild A, Arenberger P, Basset-Seguín N, et al. European consensus-based interdisciplinary guideline for melanoma. Part 1: diagnostics – update 2024. *Eur J Cancer*. 2025;215:115152.
- Gupta S, Shaughnessy M, Rashid S, Stagner AM, Fewkes J, Marghoob AA, et al. Lentigo maligna part II: management. *J Am Acad Dermatol*. 2024;93(6):1399–410.
- Gupta S, Shaughnessy M, Rashid S, Stagner AM, Fewkes J, Marghoob AA, et al. Lentigo maligna part I: epidemiology, risk factors, and diagnosis. *J Am Acad Dermatol*. 2024;93(6):1383–96.
- Oxford Centre for Evidence-Based Medicine. [cited 2026 January 01]. Available from: <https://www.cebm.ox.ac.uk/resources/levels-of-evidence/ocebml-levels-of-evidence>.
- Introduction to GRADE Handbook Handbook for grading the quality of evidence and the strength of recommendations using the GRADE approach. Updated October 2013. [cited 2026 January 01]. Available from: <https://gdt.gradepro.org/app/handbook/handbook.html>.
- Scolyer RA, Long GV, Thompson JF. Evolving concepts in melanoma classification and their relevance to multidisciplinary melanoma patient care. *Mol Oncol*. 2011;5(2):124–36.
- Chen Q, Zheng M, Ling C. Incidence trends of lentigo maligna and lentigo maligna melanoma in the United States from 2000 to 2019. *Int J Dermatol*. 2024;63(5):647–54.
- Hemminki K, Zhang H, Czene K. Incidence trends and familial risks in invasive and in situ cutaneous melanoma by sun-exposed body sites. *Int J Cancer*. 2003;104(6):764–71.
- McKenna JK, Florell SR, Goldman GD, Bowen GM. Lentigo maligna/lentigo maligna melanoma: current state of diagnosis and treatment. *Dermatol Surg*. 2006;32(4):493–504.
- Coory M, Baade P, Aitken J, Smithers M, McLeod GR, Ring I. Trends for in situ and invasive melanoma in Queensland, Australia, 1982–2002. *Cancer Causes Control*. 2006;17(1):21–7.
- Buettner PG, Leiter U, Eigentler TK, Garbe C. Development of prognostic factors and survival in cutaneous melanoma over 25 years: an analysis of the central malignant melanoma registry of the German dermatological society. *Cancer*. 2005;103(3):616–24.
- Guitera P, Collgros H, Madronio CM, Goumas C, Mann GJ, Watts CG, et al. The steadily growing problem of lentigo maligna and lentigo maligna melanoma in Australia: population-based data on diagnosis and management. *Australas J Dermatol*. 2019;60(2):118–25.
- Mirzoyev SA, Knudson RM, Reed KB, Hou JL, Lohse CM, Frohm ML, et al. Incidence of lentigo maligna in Olmsted County, Minnesota, 1970 to 2007. *J Am Acad Dermatol*. 2014;70(3):443–8.
- Scatena C, Murtas D, Tomei S. Cutaneous melanoma classification: the importance of high-throughput genomic technologies. *Front Oncol*. 2021;11:635488.
- Hayward NK, Wilmott JS, Waddell N, Johansson PA, Field MA, Nones K, et al. Whole-genome landscapes of major melanoma subtypes. *Nature*. 2017;545(7653):175–80.
- Davies H, Bignell GR, Cox C, Stephens P, Edkins S, Clegg S, et al. Mutations of the BRAF gene in human cancer. *Nature*. 2002;417(6892):949–54.
- Shain AH, Yeh I, Kovalyshyn I, Sriharan A, Talevich E, Gagnon A, et al. The genetic evolution of melanoma from precursor lesions. *N Engl J Med*. 2015;373(20):1926–36.
- Nissan MH, Pratilas CA, Jones AM, Ramirez R, Won H, Liu C, et al. Loss of NF1 in cutaneous melanoma is associated with RAS activation and MEK dependence. *Cancer Res*. 2014;74(8):2340–50.
- Menzies SW, Liyanarachchi S, Coates E, Smith A, Cooke-Yarborough C, Lo S, et al. Estimated risk of progression of lentigo maligna to lentigo maligna melanoma. *Melanoma Res*. 2020;30(2):193–7.
- Weinstock MA, Sober AJ. The risk of progression of lentigo maligna to lentigo maligna melanoma. *Br J Dermatol*. 1987;116(3):303–10.
- Patel VR, Roberson ML, Pignone MP, Adamson AS. Risk of mortality after a diagnosis of melanoma in situ. *JAMA Dermatol*. 2023;159(7):703–10.
- Naeser Y, Mikiver R, Ingvar C, Lambe M, Ullenhag GJ. Survival in patients diagnosed with melanoma in situ compared to the general population. A Swedish population-based matched cohort study. *EClinicalMedicine*. 2023;65:102284.

27. DeWane ME, Kelsey A, Oliviero M, Rabinovitz H, Grant-Kels JM. Melanoma on chronically sun-damaged skin: lentigo maligna and desmoplastic melanoma. *J Am Acad Dermatol*. 2019;81(3):823–33.
28. Todorovic-Zivkovic D, Argenziano G, Lallas A, Thomas L, Ignjatovic A, Rabinovitz H, et al. Age, gender, and topography influence the clinical and dermoscopic appearance of lentigo maligna. *J Am Acad Dermatol*. 2015;72(5):801–8.
29. Fröhlich SM, Cazzaniga S, Kaufmann LS, Hunger RE, Seyed Jafari SM. A retrospective cohort study on patients with Lentigo Maligna melanoma. *Dermatology*. 2019;235(4):340–5.
30. Schiffner R, Schiffner-Rohe J, Vogt T, Landthaler M, Wlotzke U, Cognetta AB, et al. Improvement of early recognition of lentigo maligna using dermatoscopy. *J Am Acad Dermatol*. 2000;42(1 Pt 1):25–32.
31. Lallas A, Argenziano G, Moscarella E, Longo C, Simonetti V, Zalaudek I. Diagnosis and management of facial pigmented macules. *Clin Dermatol*. 2014;32(1):94–100.
32. Lallas A, Zalaudek I, Apalla Z, Longo C, Moscarella E, Piana S, et al. Management rules to detect melanoma. *Dermatology*. 2013;226(1):52–60.
33. Jorh RH, Stolz W. Lentigo maligna and lentigo maligna melanoma. *J Am Acad Dermatol*. 1997;37(3 Pt 1):512.
34. Gola M, Czajkowski R, Bajek A, Dura A, Drewa T. Melanocyte stem cells: biology and current aspects. *Med Sci Monit*. 2012;18(10):Ra155–a159.
35. Cognetta AB Jr, Stolz W, Katz B, Tullos J, Gossain S. Dermatoscopy of lentigo maligna. *Dermatol Clin*. 2001;19(2):307–18.
36. Navarrete-Dechent C, Jaimes N, Dusza SW, Liopyris K, Marchetti MA, Cordova M, et al. Perifollicular linear projections: a dermatoscopic criterion for the diagnosis of lentigo maligna on the face. *J Am Acad Dermatol*. 2024;90(1):52–7.
37. Schiffner R, Perusquia AM, Stolz W. One-year follow-up of a lentigo maligna: first dermoscopic signs of growth. *Br J Dermatol*. 2004;151(5):1087–9.
38. Pizzichetta MA, Polesel J, Perrot JL, Rubegni P, Fiorani D, Rizzo A, et al. Amelanotic/hypomelanotic lentigo maligna: dermoscopic and confocal features predicting diagnosis. *J Eur Acad Dermatol Venereol*. 2023;37(2):303–10.
39. Tschandl P, Rosendahl C, Kittler H. Dermatoscopy of flat pigmented facial lesions. *J Eur Acad Dermatol Venereol*. 2015;29(1):120–7.
40. Akay BN, Kocyigit P, Heper AO, Erdem C. Dermatoscopy of flat pigmented facial lesions: diagnostic challenge between pigmented actinic keratosis and lentigo maligna. *Br J Dermatol*. 2010;163(6):1212–7.
41. Carbone A, Ferrari A, Paolino G, Buccini P, De Simone P, Eibenschutz L, et al. Lentigo maligna of the face: a quantitative simple method to identify individual patient risk probability on dermatoscopy. *Australas J Dermatol*. 2017;58(4):286–91.
42. Tognetti L, Cartocci A, Żychowska M, Savarese I, Cinotti E, Pizzichetta MA, et al. A risk-scoring model for the differential diagnosis of lentigo maligna and other atypical pigmented facial lesions of the face: the facial iDScore. *J Eur Acad Dermatol Venereol*. 2023;37(11):2301–10.
43. Lallas A, Lallas K, Tschandl P, Kittler H, Apalla Z, Longo C, et al. The dermoscopic inverse approach significantly improves the accuracy of human readers for lentigo maligna diagnosis. *J Am Acad Dermatol*. 2021;84(2):381–9.
44. Tschandl P, Gambardella A, Boespflug A, Deinlein T, de Giorgi V, Kittler H, et al. Seven non-melanoma features to rule out facial melanoma. *Acta Derm Venereol*. 2017;97(10):1219–24.
45. Cinotti E, Labeille B, Debarbieux S, Carrera C, Lacarrubba F, Witkowski AM, et al. Dermoscopy vs. reflectance confocal microscopy for the diagnosis of lentigo maligna. *J Eur Acad Dermatol Venereol*. 2018;32(8):1284–91.
46. Pizzichetta MA, Polesel J, Perrot JL, Rubegni P, Stanganelli I, Magi S, et al. The combination of dermoscopy and reflectance confocal microscopy increases the diagnostic confidence of amelanotic/hypomelanotic lentigo maligna. *J Dermatol*. 2024;51(5):714–8.
47. Guida S, Alma A, Fiorito F, Megna A, Chester J, Kaleci S, et al. Lentigo maligna and lentigo maligna melanoma in vivo differentiation with dermoscopy and reflectance confocal microscopy: a retrospective, multicentre study. *J Eur Acad Dermatol Venereol*. 2023;37(11):2293–300.
48. Longo C, Sticchi A, Curti A, Kaleci S, Moscarella E, Argenziano G, et al. Lentigo maligna and lentigo maligna melanoma in patients younger than 50 years: a multicentre international clinical-dermoscopic study. *Clin Exp Dermatol*. 2024;49(2):128–34.
49. Cinotti E, Fiorani D, Labeille B, Gonzalez S, Debarbieux S, Agazzino M, et al. The integration of dermoscopy and reflectance confocal microscopy improves the diagnosis of lentigo maligna. *J Eur Acad Dermatol Venereol*. 2019;33(10):e372–e374.
50. Persechino F, De Carvalho N, Ciardo S, De Pace B, Casari A, Chester J, et al. Folliculotropism in pigmented facial macules: differential diagnosis with reflectance confocal microscopy. *Exp Dermatol*. 2018;27(3):227–32.
51. Melhoranse Gouveia B, Ferguson PM, Lo SN, Collgros H, Martin LK, Sinz C, et al. In vivo reflectance confocal microscopy role for early to advanced lentigo maligna melanoma spectrum: a systematic review and pooled analysis. *J Eur Acad Dermatol Venereol*. 2025;39(3):555–65.
52. Guitera P, Pellacani G, Crotty KA, Scolyer RA, Li LX, Bassoli S, et al. The impact of in vivo reflectance confocal microscopy on the diagnostic accuracy of lentigo maligna and equivocal pigmented and nonpigmented macules of the face. *J Invest Dermatol*. 2010;130(8):2080–91.
53. Hao T, Meng XF, Li CX. A meta-analysis comparing confocal microscopy and dermoscopy in diagnostic accuracy of lentigo maligna. *Skin Res Technol*. 2020;26(4):494–502.
54. Nie T, Jiang X, Zheng B, Zhang Y. Effect of reflectance confocal microscopy compared to dermoscopy in the diagnostic accuracy of lentigo maligna: a meta-analysis. *Int J Clin Pract*. 2021;75(8):e14346.
55. Zalaudek I, Marghoob AA, Scope A, Leinweber B, Ferrara G, Hofmann-Wellenhof R, et al. Three roots of melanoma. *Arch Dermatol*. 2008;144(10):1375–9.
56. Chen CS, Elias M, Busam K, Rajadhyaksha M, Marghoob AA. Multimodal in vivo optical imaging, including confocal microscopy, facilitates presurgical margin mapping for clinically complex lentigo maligna melanoma. *Br J Dermatol*. 2005;153(5):1031–6.
57. Navarro-Navarro I, Ortiz-Prieto A, Villegas-Romero I, Valenzuela-Ubiña S, Linares-Barrios M. Wood's lamp for delineating surgical margins in lentigo maligna and lentigo maligna melanoma. *Actas Dermosifiliogr*. 2022;113(6):642–5.
58. Pralong P, Bathelier E, Dalle S, Poulalhon N, Debarbieux S, Thomas L. Dermoscopy of lentigo maligna melanoma: report of 125 cases. *Br J Dermatol*. 2012;167(2):280–7.
59. Jaimes N, Marghoob AA, Rabinovitz H, Braun RP, Cameron A, Rosendahl C, et al. Clinical and dermoscopic characteristics of melanomas on nonfacial chronically sun-damaged skin. *J Am Acad Dermatol*. 2015;72(6):1027–35.
60. Gouveia BM, Carlos G, Wadell A, Sinz C, Ahmed T, Lo SN, et al. In vivo reflectance confocal microscopy can detect the invasive component of lentigo maligna melanoma: prospective analysis and case-control study. *J Eur Acad Dermatol Venereol*. 2023;37(7):1293–301.
61. Kunishige JH, Doan L, Brodland DG, Zitelli JA. Comparison of surgical margins for lentigo maligna versus melanoma in situ. *J Am Acad Dermatol*. 2019;81(1):204–12.
62. Robinson JK. Use of digital epiluminescence microscopy to help define the edge of lentigo maligna. *Arch Dermatol*. 2004;140(9):1095–100.
63. Yélamos O, Cordova M, Blank N, Kose K, Dusza SW, Lee E, et al. Correlation of handheld reflectance confocal microscopy with radial video mosaicing for margin mapping of lentigo maligna and lentigo maligna melanoma. *JAMA Dermatol*. 2017;153(12):1278–84.
64. Mesquita Y, Marques IR, Pera Calvi I, Cruz SA, Godoi A, Lapenda IL, et al. Reflectance confocal microscopy for margin mapping of

- melanoma of the lentigo maligna type: a systematic review and meta-analysis. *J Eur Acad Dermatol Venereol*. 2025;39(3):566–75.
65. Elshot YS, Tio DCK, van Haersma-de With ASE, Ouwkerk W, Zupan-Kajcovski B, Crijs MB, et al. Lentigo maligna (melanoma): a systematic review and meta-analysis on surgical techniques and presurgical mapping by reflectance confocal microscopy. *J Eur Acad Dermatol Venereol*. 2023;37(5):871–83.
 66. Navarrete-Dechent C, Cordova M, Aleissa S, Liopyris K, Dusza SW, Kose K, et al. Lentigo maligna melanoma mapping using reflectance confocal microscopy correlates with staged excision: a prospective study. *J Am Acad Dermatol*. 2023;88(2):371–9.
 67. Gao JM, Garioch JJ, Fadhil M, Tan E, Shah N, Moncrieff M. Planning slow Mohs excision margins for lentigo maligna: a retrospective nonrandomized cohort study comparing reflectance confocal microscopy margin mapping vs. visual inspection with dermoscopy. *Br J Dermatol*. 2021;184(6):1182–3.
 68. Pellacani G, De Carvalho N, Ciardo S, Ferrari B, Cesinaro AM, Farnetani F, et al. The smart approach: feasibility of lentigo maligna superficial margin assessment with hand-held reflectance confocal microscopy technology. *J Eur Acad Dermatol Venereol*. 2018;32(10):1687–94.
 69. Karponis D, Stratigos IA, Joshy J, Craig PJ, Mistry K, van Bodegraven B, et al. Lentigo maligna: a review. *Clin Exp Dermatol*. 2024;49(3):218–25.
 70. Dika E, Lambertini M, Patrizi A, Misciali C, Scarfi F, Pellacani G, et al. Folliculotropism in head and neck lentigo maligna and lentigo maligna melanoma. *J Dtsch Dermatol Ges*. 2021;19(2):223–9.
 71. Navarrete-Dechent C, Liopyris K, Cordova M, Busam KJ, Marghoob AA, Chen CJ. Reflectance confocal microscopic and En face histopathologic correlation of the Dermoscopic “circle within a circle” in Lentigo Maligna. *JAMA Dermatol*. 2018;154(9):1092–4.
 72. Fensterseifer GS, Lodi AP, Dantas ML, Boff AL, Lovatto L. Lentigo maligna of the face: the importance of clinical, Dermoscopic, and histological correlation. *Dermatol Pract Concept*. 2019;9(4):292–4.
 73. Aouidad I, Fargeas C, Romero P, Sei JF, Chaussade V, Beauchet A, et al. Histologic predictors of invasion in partially biopsied lentigo maligna melanoma. *J Am Acad Dermatol*. 2019;80(4):1150–2.
 74. Moreno A, Manrique-Silva E, Viros A, Requena C, Sanmartin O, Traves V, et al. Histologic features associated with an invasive component in lentigo maligna lesions. *JAMA Dermatol*. 2019;155(7):782–8.
 75. Siarov J, Neittaanmäki N, Mölne J, Gillstedt M, Paoli J. Digital quantification of melanocytic density in resection margins of lentigo maligna using SOX10 versus hematoxylin-eosin staining. *Am J Dermatopathol*. 2021;43(4):273–7.
 76. Levett K, Siatecka H, Diwan AH, Krishnan B, Huttenbach YT. Diagnostic utility of SOX10 immunostaining in benign lichenoid keratosis: a study of 21 cases. *J Cutan Pathol*. 2023;50(1):51–5.
 77. Speiser J, Tao J, Champlain A, Moy L, Janeczek M, Omman R, et al. Is melanocyte density our last hope? Comparison of histologic features of photodamaged skin and melanoma in situ after staged surgical excision with concurrent scouting biopsies. *J Cutan Pathol*. 2019;46(8):555–62.
 78. Wakefield C, O’Keefe L, Heffron C. Refining the application of PRAME – a useful marker in high CSD and acral melanoma subtypes. *Virchows Arch*. 2023;483(6):847–54.
 79. Gradecki SE, Valdes-Rodriguez R, Wick MR, Gru AA. PRAME immunohistochemistry as an adjunct for diagnosis and histological margin assessment in lentigo maligna. *Histopathology*. 2021;78(7):1000–8.
 80. Kuzbicki Ł, Brożyna AA. The detectability of intraepidermal melanocytes – a narrative review of immunohistochemical studies. *J Cutan Pathol*. 2022;49(12):1074–89.
 81. Punchihewa N, Odhavji S, Upjohn E, Bekhor P. Immunostained frozen sections vs traditional permanent paraffin sections for Lentigo Maligna treated With Mohs micrographic surgery. *Dermatol Surg*. 2022;48(1):43–6.
 82. Xia J, Patel H, Guo L, Hsu C, Revankar R, Torbeck R. The use of immunohistochemical staining in Mohs micrographic surgery for melanoma: a systematic review. *Arch Dermatol Res*. 2023;315(10):2769–72.
 83. Cinotti E, Belgrano V, Labeille B, Grivet D, Douchet C, Chaleur C, et al. In vivo and ex vivo confocal microscopy for the evaluation of surgical margins of melanoma. *J Biophotonics*. 2020;13(11):e202000179.
 84. Swetter SM, Tsao H, Bichakjian CK, Curiel-Lewandrowski C, Elder DE, Gershenwald JE, et al. Guidelines of care for the management of primary cutaneous melanoma. *J Am Acad Dermatol*. 2019;80(1):208–50.
 85. Stante M, De Giorgi V, Cappugi P, Giannotti B, Carli P. Non-invasive analysis of melanoma thickness by means of dermoscopy: a retrospective study. *Melanoma Res*. 2001;11(2):147–52.
 86. Bauer J, Metzler G, Rassner G, Garbe C, Blum A. Dermatoscopy turns histopathologist’s attention to the suspicious area in melanocytic lesions. *Arch Dermatol*. 2001;137(10):1338–40.
 87. Moscarella E, Pampena R, Palmiotti G, Bonamonte D, Brancaccio G, Piccolo V, et al. A meta-analysis on the influence of partial biopsy of primary melanoma on disease recurrence and patient survival. *J Eur Acad Dermatol Venereol*. 2020;34(2):279–84.
 88. Mills JK, White I, Diggs B, Fortino J, Vetto JT. Effect of biopsy type on outcomes in the treatment of primary cutaneous melanoma. *Am J Surg*. 2013;205(5):585–90; discussion 90.
 89. Ng JC, Swain S, Dowling JP, Wolfe R, Simpson P, Kelly JW. The impact of partial biopsy on histopathologic diagnosis of cutaneous melanoma: experience of an Australian tertiary referral service. *Arch Dermatol*. 2010;146(3):234–9.
 90. Longo C, Navarrete-Dechent C, Tschandl P, Apalla Z, Argenziano G, Braun RP, et al. Delphi consensus among international experts on the diagnosis, management, and surveillance for lentigo maligna. *Dermatol Pract Concept*. 2023;13(3):e2023244.
 91. Vaidya TS, Bander TS, Musthaq S, Lampley N 3rd, Lee EH, Nehal KS, et al. Validation of a patient decision aid for the treatment of lentigo maligna. *J Am Acad Dermatol*. 2021;84(6):1751–3.
 92. Robinson M, Primiero C, Guitera P, Hong A, Scolyer RA, Stretch JR, et al. Evidence-based clinical practice guidelines for the management of patients with lentigo maligna. *Dermatology*. 2020;236(2):111–6.
 93. Bittar PG, Bittar JM, Etkorn JR, Brewer JD, Aizman L, Shin TM, et al. Systematic review and meta-analysis of local recurrence rates of head and neck cutaneous melanomas after wide local excision, Mohs micrographic surgery, or staged excision. *J Am Acad Dermatol*. 2021;85(3):681–92.
 94. Johnson TM, Headington JT, Baker SR, Lowe L. Usefulness of the staged excision for lentigo maligna and lentigo maligna melanoma: the “square” procedure. *J Am Acad Dermatol*. 1997;37(5 Pt 1):758–64.
 95. Patel AN, Perkins W, Leach IH, Varma S. Johnson square procedure for lentigo maligna and lentigo maligna melanoma. *Clin Exp Dermatol*. 2014;39(5):570–6.
 96. Gaudy-Marqueste C, Perchenet AS, Taséi AM, Madjlessi N, Magalon G, Richard MA, et al. The “spaghetti technique”: an alternative to Mohs surgery or staged surgery for problematic lentiginous melanoma (lentigo maligna and acral lentiginous melanoma). *J Am Acad Dermatol*. 2011;64(1):113–8.
 97. Mahoney MH, Joseph M, Temple CL. The perimeter technique for lentigo maligna: an alternative to Mohs micrographic surgery. *J Surg Oncol*. 2005;91(2):120–5.
 98. Martinez-Molina M, Richarz N, Jaka A, Bassas-Vila J, Mora-Fernández V, Pi-Sunyer AQ, et al. Spaghetti technique versus wide local excision for lentigo maligna affecting the head and neck regions: surgical outcome and descriptive analysis of 79 cases from a single practice cohort. *Dermatol Pract Concept*. 2023;13(3):e2023193.
 99. Abdelmalek M, Loosmore MP, Hurt MA, Hruza G. Geometric staged excision for the treatment of lentigo maligna and lentigo maligna melanoma: a long-term experience with literature review. *Arch Dermatol*. 2012;148(5):599–604.

100. Dika E, Fanti PA, Christman H, Piraccini BM, Misciali C, Vaccari S, et al. Videodermatology-assisted Mohs micrographic surgery vs. other treatments for lentigo maligna in 54 patients with a long-term follow-up. *J Eur Acad Dermatol Venereol.* 2016;30(8):1440–1.
101. Kuflik EG, Gage AA. Cryosurgery for lentigo maligna. *J Am Acad Dermatol.* 1994;31(1):75–8.
102. Zalaudek I, Horn M, Richtig E, Hödl S, Kerl H, Smolle J. Local recurrence in melanoma in situ: influence of sex, age, site of involvement and therapeutic modalities. *Br J Dermatol.* 2003;148(4):703–8.
103. Kaur A, Javed MU, Venables B, Murison M, Yarrow J. Rate of recurrence following treatment of lentigo maligna with carbon dioxide laser alone or in combination with imiquimod: results of a long-term study. *J Plast Reconstr Aesthet Surg.* 2023;85:95–7.
104. Madan V, August PJ. Lentigo maligna – outcomes of treatment with Q-switched Nd:YAG and alexandrite lasers. *Dermatol Surg.* 2009;35(4):607–11; discussion 11–2.
105. Read T, Noonan C, David M, Wagels M, Foote M, Schaidler H, et al. A systematic review of non-surgical treatments for lentigo maligna. *J Eur Acad Dermatol Venereol.* 2016;30(5):748–53.
106. Hendrickx A, Cozzio A, Plasswilm L, Panje CM. Radiotherapy for lentigo maligna and lentigo maligna melanoma - a systematic review. *Radiat Oncol.* 2020;15(1):174.
107. Hong AM, Lo SN, Fogarty GB, Stretch J, Wang W, Penas PF, et al. A randomised, controlled, multicentre trial of imiquimod versus radiotherapy for lentigo maligna. *J Clin Oncol.* 2024;42(16_suppl):9502.
108. Hong AM, Lo SN, Fogarty GB, Stretch J, Wang W, Fernandez-Penas P, et al. Radiotherapy versus imiquimod for complex lentigo maligna: a phase 3 randomized clinical trial. *J Am Acad Dermatol.* 2025;93:1251–60.
109. Daude M, Dinulescu M, Nguyen JM, Maillard H, Le Duff F, Machel L, et al. Efficacy of imiquimod in the management of lentigo maligna. *J Eur Acad Dermatol Venereol.* 2023;37(9):1785–91.
110. Guitera P, Waddell A, Paton E, Fogarty GB, Hong A, Scolyer RA, et al. A practical guide on the use of imiquimod cream to treat lentigo maligna. *Australas J Dermatol.* 2021;62(4):478–85.
111. Mora AN, Karia PS, Nguyen BM. A quantitative systematic review of the efficacy of imiquimod monotherapy for lentigo maligna and an analysis of factors that affect tumor clearance. *J Am Acad Dermatol.* 2015;73(2):205–12.
112. Vaienti S, Calzari P, Nazzaro G. Topical treatment of melanoma in situ, lentigo maligna, and lentigo maligna melanoma with imiquimod cream: a systematic review of the literature. *Dermatol Ther (Heidelb).* 2023;13(10):2187–215.
113. Tio D, van der Woude J, Prinsen CAC, Jansma EP, Hoekzema R, van Montfrans C. A systematic review on the role of imiquimod in lentigo maligna and lentigo maligna melanoma: need for standardization of treatment schedule and outcome measures. *J Eur Acad Dermatol Venereol.* 2017;31(4):616–24.
114. Ghanem L, Sicorschi Gutu C, Mendoza-Millan DL, Barreiros Pungirum V, Cevallos-Cueva M, Almeida Sardinha C, et al. Imiquimod 5% for lentigo maligna of the head, neck and face: a systematic review and meta-analysis. *J Eur Acad Dermatol Venereol.* 2025. <https://doi.org/10.1111/jdv.70141>. Online ahead of print.
115. Hyde MA, Hadley ML, Tristani-Firouzi P, Goldgar D, Bowen GM. A randomized trial of the off-label use of Imiquimod, 5%, cream With vs without tazarotene, 0.1%, gel for the treatment of lentigo maligna, followed by conservative staged excisions. *Arch Dermatol.* 2012;148(5):592–6.
116. Coleman WP 3rd, Davis RS, Reed RJ, Kremenz ET. Treatment of lentigo maligna and lentigo maligna melanoma. *J Dermatol Surg Oncol.* 1980;6(6):476–9.
117. Montaudie H, Le Duff F, Butori C, Hofman V, Fontas E, Roger-Cruzet C, et al. Ingenol mebutate to treat lentigo maligna of the head (face and scalp): a prospective, multicenter, single-arm phase 2 trial indicates no benefit. *J Am Acad Dermatol.* 2020;82(3):731–3.
118. Lallas A, Moscarella E, Kittler H, Longo C, Thomas L, Zalaudek I, et al. Real-world experience of off-label use of imiquimod 5% as an adjuvant therapy after surgery or as a monotherapy for lentigo maligna. *Br J Dermatol.* 2021;185(3):675–7.
119. Swetter SM, Chen FW, Kim DD, Egbert BM. Imiquimod 5% cream as primary or adjuvant therapy for melanoma in situ, lentigo maligna type. *J Am Acad Dermatol.* 2015;72(6):1047–53.
120. Kwak R, Joyce C, Werchniak AE, Lin JY, Tsibris HC. Clinical and histologic features associated with lentigo maligna clearance after imiquimod treatment. *J Dermatolog Treat.* 2022;33(4):1995–9.
121. Chambers M, Swetter SM, Baker C, Saunders E, Chapman MS. Topical imiquimod for lentigo maligna: survival analysis of 103 cases with 17 years follow-up. *J Drugs Dermatol.* 2021;20(3):346–8.
122. Poveda-Montoyo I, Álvarez-Chinchilla P, Schneller-Pavelescu L, Hispán-Ocete P, Bañuls-Roca J. Series of fourteen cases of topical Imiquimod 5% in lentigo maligna: treatment modalities and clues for detecting recurrences. *Actas Dermosifiliogr.* 2022;113(4):407–12.
123. Hedblad MA, Mallbris L. Grenz ray treatment of lentigo maligna and early lentigo maligna melanoma. *J Am Acad Dermatol.* 2012;67(1):60–8.
124. Donigan JM, Hyde MA, Goldgar DE, Hadley ML, Bowling M, Bowen GM. Rate of recurrence of lentigo maligna treated with off-label neoadjuvant topical imiquimod, 5%, cream prior to conservatively staged excision. *JAMA Dermatol.* 2018;154(8):885–9.
125. Cancer Council Australia Melanoma Guidelines Working Party. Clinical practice guidelines for the diagnosis and management of melanoma. Sydney: Cancer Council Australia; 2023.
126. Garbe C, Amaral T, Peris K, Hauschild A, Arenberger P, Basset-Seguín N, et al. European consensus-based interdisciplinary guideline for melanoma. Part 1: diagnostics: update 2022. *Eur J Cancer.* 2022;170:236–55.
127. Star P, Rawson RV, Drummond M, Lo S, Scolyer RA, Guitera P. Lentigo maligna: defining margins and predictors of recurrence utilizing clinical, dermoscopic, confocal microscopy and histopathology features. *J Eur Acad Dermatol Venereol.* 2021;35(9):1811–20.
128. Nadiminti H, Scope A, Marghoob AA, Busam K, Nehal KS. Use of reflectance confocal microscopy to monitor response of lentigo maligna to nonsurgical treatment. *Dermatol Surg.* 2010;36(2):177–84.
129. Coco V, Perino F, Di Stefani A, Cappilli S, Peris K. Reflectance confocal microscopy and its role in the follow-up of a topical treatment for lentigo maligna. *Int J Dermatol.* 2021;60(2):196–200.
130. Alarcon I, Carrera C, Alos L, Palou J, Malveyh J, Puig S. In vivo reflectance confocal microscopy to monitor the response of lentigo maligna to imiquimod. *J Am Acad Dermatol.* 2014;71(1):49–55.
131. Soenen A, Vourc'h M, Khammari A, Nguyen J-M, Bossard C, Denis Musquer M, et al. Change in lentigo maligna score assessed by in vivo reflectance confocal microscopy after 1 month of imiquimod treatment for lentigo maligna management. *J Am Acad Dermatol.* 2022;86(5):1042–8.
132. Antoñanzas J, Morello-Vicente A, Garnacho-Saucedo GM, Redondo P, Aguado-Gil L, Salido-Vallejo R. Risk of second primary malignancies in melanoma survivors: a population-based study. *Cancers (Basel).* 2023;15(11):3056.
133. Espinosa P, Pfeiffer RM, Garcia-Casado Z, Requena C, Landi MT, Kumar R, et al. Risk factors for keratinocyte skin cancer in patients diagnosed with melanoma, a large retrospective study. *Eur J Cancer.* 2016;53:115–24.
134. Collgros H, Rodriguez-Lomba E, Regio Pereira A, Lo SN, Scolyer RA, Guitera P. Lentiginous melanoma (lentigo maligna and lentigo maligna melanoma) in Australia: clinicopathological characteristics, management and recurrence rates after 10-year follow-up at a tertiary centre. *J Eur Acad Dermatol Venereol.* 2021;35(6):1315–22.
135. Matas-Nadal C, Malveyh J, Ferreres JR, Boada A, Bodet D, Segura S, et al. Increasing incidence of lentigo maligna and lentigo maligna melanoma in Catalonia. *Int J Dermatol.* 2019;58(5):577–81.
136. Gordon L, Olsen C, Whiteman DC, Elliott TM, Janda M, Green A. Prevention versus early detection for long-term control of melanoma and keratinocyte carcinomas: a cost-effectiveness modelling study. *BMJ Open.* 2020;10(2):e034388.

137. Raimondi S, Suppa M, Gandini S. Melanoma epidemiology and sun exposure. *Acta Derm Venereol.* 2020;100(11):adv00136.
138. Gaudy-Marqueste C, Madjlessi N, Guillot B, Avril MF, Grob JJ. Risk factors in elderly people for lentigo maligna compared with other melanomas: a double case-control study. *Arch Dermatol.* 2009;145(4):418–23.
139. Mitsaki KS, Apalla Z, Lazaridou E, Lallas K, Lallas A. Risk factors of lentigo maligna as compared to other melanoma subtypes. *Int J Dermatol.* 2024;63(8):e157–e162.
140. Kvaskoff M, Siskind V, Green AC. Risk factors for lentigo maligna melanoma compared with superficial spreading melanoma: a case-control study in Australia. *Arch Dermatol.* 2012;148(2):164–70.
141. Garbe C, Forsea AM, Amaral T, Arenberger P, Autier P, Berwick M, et al. Skin cancers are the most frequent cancers in fair-skinned populations, but we can prevent them. *Eur J Cancer.* 2024;204:114074.
142. Badertscher N, Meier M, Rosemann T, Braun R, Cozzio A, Tag B, et al. The role of skin self-examination at the Swiss skin cancer day. *BMC Health Serv Res.* 2014;14:581.

SUPPORTING INFORMATION

Additional supporting information can be found online in the Supporting Information section at the end of this article.

How to cite this article: Forsea A-M, Pampena R, Akay BN, Apalla Z, Argenziano G, Briatico G, et al. International Dermoscopy Society consensus recommendations for the management of lentigo maligna. *J Eur Acad Dermatol Venereol.* 2026;00:1–18. <https://doi.org/10.1111/jdv.70406>