



## Full Length Article

# Clinical, laboratory and immunohistochemical characterization of in situ pulmonary arterial thrombosis in fatal COVID-19

Luca Quartuccio<sup>a,b,\*</sup>, Arianna Sonaglia<sup>a,b</sup>, Letizia Casarotto<sup>b,c</sup>, Dennis McGonagle<sup>d</sup>,  
Carla Di Loreto<sup>b,c</sup>, Enrico Pegolo<sup>c</sup>

<sup>a</sup> Division of Rheumatology, Academic Hospital "Santa Maria della Misericordia", ASUFC, Piazzale Santa Maria della Misericordia 15, 33100 Udine, Italy

<sup>b</sup> University of Udine, Department of Medicine (DAME), Via Colugna 50, 33100 Udine, Italy

<sup>c</sup> Institute of Anatomic Pathology, Academic Hospital "Santa Maria della Misericordia", ASUFC, Piazzale Santa Maria della Misericordia 15, 33100 Udine, Italy

<sup>d</sup> Leeds Institute of Rheumatic and Musculoskeletal Medicine, University of Leeds, Leeds LS7 4SA, UK



## ARTICLE INFO

## Keywords:

Coronavirus  
Thrombosis  
Inflammation  
Lung  
Artery

## ABSTRACT

**Background:** COVID-19 patients carry an increased rate of thrombosis. It is controversial to which extent thrombi in the pulmonary arterial tree really contribute to disease severity with hypoxemia secondary to microvascular/lung parenchymal damage with viral alveolitis considered to play the main role in critical disease.

**Objectives:** The primary objective was to compare post-mortem lung disease from fatal COVID-19 pneumonia in patients with macroscopically evident pulmonary arterial tree thrombosis and patients without, by characterizing the immunohistochemical nature of thrombi, and by comparing clinical and laboratory features of these patients with other COVID-19 patients who died but without evidence of pulmonary arterial thrombosis (controls).

**Patients and methods:** 13 COVID-19 pneumonia cases (mean age  $\pm$  standard deviation: 74  $\pm$  6.5 years) with macroscopically visible pulmonary arterial thrombosis were compared to 14 controls. Hematoxylin and Eosin stained slides were reviewed choosing those with visible pulmonary thrombi which were further characterized by immunohistochemistry, in particular for the inflammatory infiltrates. Ante mortem serum markers relevant to pulmonary embolism were evaluated in both groups.

**Results:** Twenty arterial thrombi (5 cases with multiple thrombi) were selected for study and were composed by white blood cells (WBC) [median, IQR range: 10 % (5–12.25)], mainly neutrophils [58 % (35.2–64.5)]. Cases with thrombosis showed significantly higher levels of platelet count [median, IQR range: 195000/mmc (157750–274,500) vs 143,500 (113000–175,250),  $p = 0.011$ ], LDH [854 U/L (731–1315) vs 539 (391.5–660),  $p = 0.003$ ] at admission, and D-dimer at ICU transfer [25,072 FEU (6951–50,531) vs 1024 (620–5501),  $p = 0.003$ ].

**Conclusions:** Immunothrombotically driven arterial thrombi in COVID-19 patients are associated with D-Dimer and LDH elevations, thus linking inflammation, coagulopathy and organ damage in fatal COVID-19.

## 1. Introduction

Severe Acute Respiratory Syndrome Coronavirus-2 (SARS-CoV-2), a novel betacoronavirus emerged in December 2019 and rapidly disseminated globally leading to the current COVID-19 pandemic. Despite best efforts to contain COVID-19, more than 5 million deaths have been recorded (OMS data from Health Emergency Dashboard at the beginning of December 2021) [1–4]. COVID-19 mortality is not yet completely understood since it was initially ascribed to acute respiratory distress

syndrome (ARDS) complicating underlying pneumonia, but an important role of immunologic response together with coagulation disorders linked to the infection that manifest as diffuse pulmonary vascular thrombosis and lung damage has been claimed [5,6].

Overall, one in five COVID-19 patients experienced acute pulmonary embolism as complication during hospitalization [7], and autopsy findings in patients with COVID-19 demonstrating pulmonary embolism in about 30 % of subjects [8]. In particular, COVID-19 patients could develop thrombotic complications because of the recruitment of

\* Corresponding author at: Division of Rheumatology, Department of Medicine, University of Udine, ASUFC, Via Colugna 50, 33100 Udine, Italy.  
E-mail address: [luca.quartuccio@uniud.it](mailto:luca.quartuccio@uniud.it) (L. Quartuccio).

immunologic effectors and cytokine production, which may trigger different coagulative pathways, involving both the extrinsic and intrinsic cascade as well as the complement system [5,6,9,12]. So, the above-mentioned pathways show the bridge between immunologic response and hypercoagulation status observed in SARS-CoV-2, referred to as the term “immunothrombosis” [6,11–13]. While the immunothrombotic process targets capillaries, smaller arterioles and venules, larger vessel involvement and especially pulmonary arterial tree involvement that mimics multiple pulmonary embolisms could be a major contributor to disease course, leading to the higher mortality on COVID-19 patients [12–14]. Compared to other respiratory infections, SARS-CoV-2 has a significantly stronger association with thromboembolic events, especially in critically ill patients; in fact, up to 60 % of severe cases develop the so-called COVID-19-associated Pulmonary Intravascular Coagulopathy (PIC) [13], showing increased D-Dimer levels, decreased PT or aPTT time with or without significant variations on platelet count [9,11,13–17].

Autopsy studies performed in different countries have contributed substantially to the understanding the pathogenesis of fatal COVID-19 [6,10–12,15,17–21].

Systemic coagulopathy, including thrombocytopenia, increased D-dimer, longer prothrombin time (PT), and longer activated partial thromboplastin time (APTT), has been associated with fatal thromboembolic events in vital organs, including lung and heart [22]. The pathological examination of pulmonary vasculature in COVID-19 patients showed diffuse alveolar damage (DAD) with concurrent thrombi formation, even in the microcirculation [12]. Some autopsy studies reported the combined presence of megakaryocytes and thrombi in the lung of COVID-19 patients [22,23], however, the implication of megakaryocytes in COVID-19 pulmonary coagulopathy and even in other pulmonary diseases is still debated [24].

Although many biomarkers have been proposed to estimate the thrombotic risk in COVID-19, a recent consensus statement from the International COVID-19 thrombosis biomarkers Colloquium recommended only C-Reactive Protein and D-dimer to assess the risk of venous thromboembolic events, both biomarkers being correlated to the disease severity [25]. Therefore, the inflammatory nature of thrombosis in COVID-19 has been widely accepted [26]. While venous thrombosis is well described in COVID-19, arterial thrombosis in hospitalized patients with COVID-19 is less investigated [27], and detailed pathological description of the pulmonary arterial tree thrombosis is still lacking.

In this context, the present study provided a post-mortem retrospective evaluation of pulmonary arterial tree macroscopically visible thrombosis in patients who died for COVID-19 since it is not well understood in relationship to overall cardiovascular pathology.

The primary objective of the study was to assess patients succumbing to COVID-19 who had pulmonary arterial thrombosis identified at autopsy. We characterized the histopathological and immunological nature of the thrombi, performing macroscopic and microscopic analyses. Then, we compared these results with data obtained from patients deceased for COVID-19 without evidence of pulmonary thrombosis, matching them for age, sex, and time between diagnosis and death to deeper characterize that subset of patients developing in situ pulmonary arterial thrombosis.

## 2. Materials and methods

From October 25, 2020 to April 7, 2021, consecutive patients (cases) died for COVID-19 with evidence of pulmonary arterial thrombosis at autopsy finding but without pathological signs of superimposed bronchopneumonia or peripheral venous thrombosis, and patients without pulmonary arterial thrombosis (controls) were selected.

An autopsy was performed in all the patients of the study (Supplemental file, Fig. S1). Peripheral veins were examined at post mortem examination, in particular the deep lower and upper limb vessels and the periprostatic/periuterine venous plexus. In all the patients there were no

macroscopic evidence of peripheral thrombosis. Cases who died for bronchopneumonia related to superimposed bacterial or fungal infection (based on autopsy findings) were excluded as well as those with secondary pulmonary thromboembolism due to peripheral thrombosis, trying to finally evaluate only patients with in situ pulmonary arterial thrombosis.

We then reviewed the hematoxylin and eosin (H&E) slides and choose those with clearly visible pulmonary thrombi. On each selected paraffin block we then performed further histochemical (elastic fibers, Masson's trichrome) and immunohistochemical (myeloperoxidase, CD68, CD61, CD31, CD20, CD3, CD4, and CD8) staining, discarding the very few cases in which thrombi were not present anymore in deeper sections.

Every single component of the thrombus was evaluated using the open-source software application QuPath (<https://qupath.github.io>) in terms of fibrin, red blood cells, platelets, and immune cells percentage after scanning the slides with Aperio System (Supplemental file, Fig. S2).

Furthermore, the thrombus area and the size (diameter) of every thrombosed vessel were measured.

In H&E stained slides we trained the program to recognize the various elements based on their pixels, using the selected areas in multiple slides to make it more precise. We then used the obtained pixel classification to determine the percentages of fibrin, red blood cells, and immune cells.

Since in H&E stained slides it is not possible to clearly distinguish platelets, which are admixed with red blood cells and fibrin, the percentage of platelets was determined using CD61 immunostaining.

The percentage of neutrophils was evaluated by examining the staining for myeloperoxidase and by doing an object classification analysis. Since the program, when using immunohistochemical stains as a reference, incorrectly considers some red blood cells as nucleated cells, the positivity was calibrated only on the immune cells. The same procedure was repeated for CD3 and CD20 staining.

The group of controls included 14 patients, matched for age, gender, and time from diagnosis to death, who died for COVID-19 and in whom pulmonary thrombi were excluded at the autopsy. Using our hospital database, we excluded previous thromboembolic events during hospitalization for SARS-CoV-2 infection. In the control group, patients showing superimposed bronchopneumonia were not excluded. Demographic, clinical characteristics and laboratory features of the cases and controls at hospital admission, and at ICU admission are reported respectively on Tables 1, 2, and 3.

### 2.1. Statistical analysis

Continuous variables have been evaluated with the three main percentiles (first quartile, median and third quartile), while categorical variables have been described by their absolute frequencies and percentages.

For univariable comparisons of the characteristics between groups, the Wilcoxon-Kruskal-Wallis test was used for continuous variables; Pearson's chi-square test was used for categorical variables.

ROC curve analyses were applied for those variables which had been selected by the univariable comparisons. Statistical significance was set at a p-value of 0.05.

## 3. Results

### 3.1. Characteristics of the cases

The group of the cases included 13 patients hospitalized and who died for respiratory failure in the context of COVID-19 DAD, in whom the autopsy finding demonstrated pulmonary arterial thrombi comprising 10 males and 3 females, with a mean age of  $74 \pm 6.5$  years (Table 1). All tested positive to SARS-CoV-2 between October 2020 and April 2021; positivity was assessed by detection of viral RNA on the

**Table 1**  
Demographic characteristics of the case and controls.

	Cases N = 13	Controls N = 14	P value
Age, mean (SD)	74.2 (6.5)	73.5 (7.3)	0.794
Sex (female)	3	1	0.326
Time from diagnosis to hospital admission, median (IQR)	3.5 (0–8.75)	0 (0–3)	0.185
Time from diagnosis to admission in ICU, median (IQR)	8 (1.25–12.75)	4 (3–6)	0.160
Days in ICU, median (IQR)	8.5 (2.25–15.5)	10.5 (7.75–12.25)	0.239
Time to death, median (IQR)	20 (11.5–25.25)	15 (11.75–18.25)	0.375
Superimposed infections, n(%)	4 (30.7)	10 (71.4)	0.08
Obesity, n(%)	2 (15.4)	5 (35.7)	0.22
Hypertension, n(%)	8 (61.5)	11 (78.6)	0.08
Diabetes, n(%)	4 (30.8)	6 (42.8)	0.51
COPD, n(%)	3 (23.1)	1 (7.1)	0.244
CKD, n(%)	2 (15.4)	4 (28.6)	0.41
Cardiovascular disease (ischemic), n(%)	1 (7.7)	4 (28.6)	0.16
History of arterial or venous thrombosis	1 (7.7)	1 (7.1)	0.96
Use of anticoagulant before COVID-19	2 (15.4)	1 (7.1)	0.49
Therapeutic heparin or anticoagulation	1 (7.7)	3 (21.4)	0.31
Corticosteroids (dexamethasone or methylprednisolone)	13 (100)	12 (85.7)	0.31

**Legend:** SD, standard deviation; IQR, interquartile range; ICU, intensive care unit; COPD, chronic obstructive pulmonary disease; CKD, chronic kidney disease.

**Table 2**  
Laboratory features at hospital admission.

	Cases		Controls		P-value
	Median	IQR	Median	IQR	
White blood cells, cell/mmc	6900	4327.5–10,445	5535	3795–7025	0.252
Neutrophils, cell/mmc	5345	2875–9060	4720	3165–5805	0.406
Lymphocytes, cell/mmc	580	397.5–770	680	445–1000	0.574
Platelets, cell/mmc	195,000	157,750–274,500	143,500	113,000–175,250	<b>0.011</b>
Haemoglobin, g/dL	14.15	10.15–15.1	13.5	11.575–15.175	0.899
INR	1.13	1.04–1.28	1.09	1.045–1.275	0.910
D-dimer, FEU	1136	645–3442	891	503.5–1600.5	0.412
C-reactive protein, mg/L	127.46	67.123–222.848	102	75.475–173	0.631
Procalcitonin, ng/ml	0.29	0.14–0.35	0.225	0.0475–0.3475	0.183
Lactate dehydrogenase, U/L	854	731–1315	539	391.5–660	<b>0.003</b>

**Legend:** FEU, fibrinogen-equivalent units; INR, international normalized ratio. Significant p-values are in bold.

**Table 3**  
Laboratory features at Intensive Care Unit admission.

	Cases		Controls		P-value
	Median	IQR	Median	IQR	
White blood cells, cell/mmc	11,790	7915–17,705	7655	6032.5–9995	0.083
Neutrophils, cell/mmc	9665	6867.5–15,762.5	6780	4622.5–10,372.5	0.157
Lymphocytes, cell/mmc	320	247.5–522.5	410	282.5–627.5	0.270
Platelets, cell/mmc	227,000	189,000–275,500	194,500	148,750–209,000	<b>0.046</b>
Haemoglobin, g/dL	12.6	11.9–13.55	11.6	10.475–13.35	0.477
INR	1.27	1.1775–1.47	1.12	1.0275–1.27	0.33
D-dimer, FEU	25,072	6951–50,531	1024	620–5501	<b>0.003</b>
C-reactive protein, mg/L	114.88	91.915–271.625	102.55	44.6–170.325	0.141
Procalcitonin, ng/ml	0.67	0.18–1.345	0.245	0.108–0.325	0.062
Lactate dehydrogenase, U/L	1099	702–1666	936	801–1118	0.588

**Legend:** FEU, fibrinogen-equivalent units; INR, international normalized ratio. Significant p-values are in bold.

nasopharyngeal swab, with a molecular test based on real-time polymerase-chain-reaction. In 4 cases a superimposed bacterial infection was reported during hospitalization, demonstrated by bronchoalveolar lavage, but bronchopneumonia was definitely excluded at the autopsy.

Three cases had a history of the previous thrombosis. All cases had received anticoagulant treatment during hospitalization: low molecular weight heparin in 12/13 (4/12 received therapeutic regimen due to atrial fibrillation or history of thrombosis before hospital admission, while in 8/12 it was prophylactic), while 1/13 continued oral anticoagulants for chronic atrial fibrillation. No one of these patients reported bleeding. Three cases had ischemic events during hospitalization, represented by non ST-segment elevation myocardial infarction (NSTEMI) in two, and cerebral ischemia in one; two of them were on prophylactic low-molecular-weight heparin (LMWH) while the other was on a

therapeutic regimen (started because of pulmonary thrombosis at chest computed tomography (CT) scan performed at hospital admission). Corticosteroid treatment was started in all patients, generally dexamethasone 6 mg day, except for 2 patients that required higher dosages. Antivirals were administered in 1/13 cases and in 1/14 controls, with no influence on the outcome.

At hospital admission, these patients showed bilateral COVID-19 pneumonia by CT scan without contrast medium, extended for 50%–75% of lung parenchyma in 11, while for more than 75% and less than 25% in the remaining two cases. Only 1/13 presented an increased diameter of pulmonary artery on CT scan. All but one patient with pulmonary arterial thrombosis as well as all controls were admitted to ICU. Pulmonary thrombosis was detected by contrast medium CT scan in 5 patients, who underwent the exam during their hospital stay.

**Table 4**  
ROC curve analysis for the significant laboratory features discriminating cases from controls.

	AUC	95%CI	Standard error	P value	Cut off value, sensitivity/specificity
Platelet count at hospital admission	0.738	0.516–0.960	0.113	0.059	NA
LDH at hospital admission	0.873	0.717–1.028	0.079	<b>0.004</b>	722.5 U/L, 81.8 %/90 %
Platelet count at ICU admission	0.754	0.543–0.965	0.108	<b>0.044</b>	NA
D-dimer at ICU admission	0.89	0.74–1.040	0.077	<b>0.005</b>	6332 FEU, 85.7 %/84.6 %

**Legend:** ICU, Intensive Care Unit; LDH lactate dehydrogenase; AUC, area under curve; CI, confidence Interval; FEU, fibrinogen-equivalent units; NA, not available. Significant p-values are in bold.

**3.2. Laboratory comparisons between cases and controls at different time points**

By comparing laboratory findings between cases and controls, platelet count [median, IQR range: 195000 (157750–274,500) vs 143,500 (113000–175,250),  $p = 0.011$ ] and LDH [854 (731–1315) vs 539 (391.5–660),  $p = 0.003$ ] were considerable higher in the cases at hospital admission, while D-dimer was significantly increased in the cases at ICU transfer [25,072 (6951–50,531) vs 1024 (620–5501),  $p = 0.003$ ] (Tables 2, 3). By ROC curve analysis for LDH at hospital admission and D-dimer at ICU admission, values of 722.5 U/L and 6332 FEU, respectively, resulted in a sensitivity/specificity of 81.8 %/90 %, and 85.7 %/84.6 %, for LDH and D-dimer, respectively (Table 4).

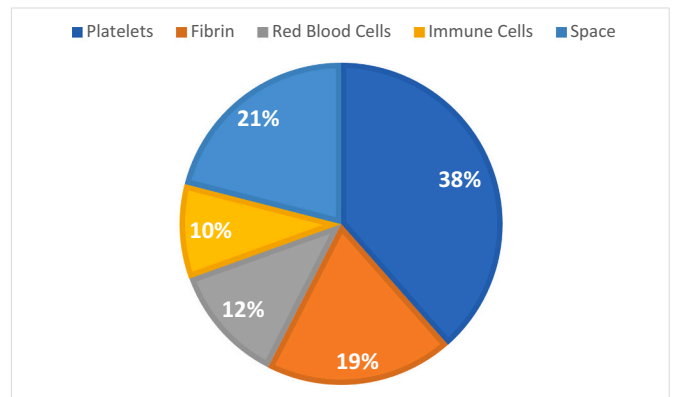
**3.3. Immune pathology of the thrombi**

Table 5 reports the characteristics of the twenty in situ thrombi observed in the 13 cases, with details on the immune cell composition. The vessel diameter confirmed that all the clots are arterial thrombi

**Table 5**  
Characteristics of the thrombi for each case.

N. clots	Diameter vessel (µm)	Platelet %	Red blood cell %	Fibrin %	Immune cells %	Area (µm <sup>2</sup> )	Neutrophil %	CD20%	CD3%	Case
1	2675,7128	63	5	18	11	32,385,681,7	85,9764	17,433	5466	1
2	261,3738	1	65	26	2	77,901,3	14,881			2
3	106,8633	11	35	55,5	3	8822,6	15	0	38,462	2
4	911,2586	32	10	46	7	3,295,055,2	76,956	9711	16,9811	3
5	529,288	42	2	49	5	292,862,7	47,2892	47,026	13,8055	4
6	1346,0654	46	13	31	6	1,642,137,6	35,4528	0,0599	12,2963	5
7	673,7511	38	11	13	29	548,193,1	64,5396	40,451	21,338	6
8	1038,8424	31	44	17	5	2,108,641,8	60,1751	12,777	20,0284	7
9	531,4716	41	31	15	9	5,228,761,5	61,5239	11,353	11,5144	7
10	649,5253	39	34	15	8	939,152,9	61,5239	13,461	36,064	8
11	838,844	34	38	8	13	5,922,414,5	67,7607	0,7012	18,598	8
12	204,3228	54	26	8	9	64,069,7	36,5826	17,699	43,956	8
13	1293,6189	32	58	30	13	1,656,298	34,2992	11,634	27,683	8
14	249,7134	13	4	79	2	106,701,7	49,4898			9
15	1251,1225	40	32	10	12	2,120,189	21,0707	14,776	79,831	10
16	486,2497	71	6	2	19	396,974,8	22,3626	45,825	8,3839	10
17	909,5728	67	5	18	8	1,201,399,5	55,6915	0,241	0,2383	11
18	1218,9298	4	7	67	12	2,277,915,3	65,443	14,205	69,035	12
19	297,5737	32	6	41	14	544,526,4	64,4909	2	45,455	13
20	1170,2552	70	6	19	4	4,690,693,9	64,1267	0,0261	29,089	13
Mean	832,22	38,05	21,90	28,38	9,55	3,275,419,66	50,23	2,08	7,80	
Median	756,30	38,50	12,00	18,50	8,50	1,421,768,55	57,93	1,38	5,47	
St. dev	589,45	20,50	19,24	21,26	6,40	7,079,613,56	20,90	2,39	6,65	
Q1	439,08	31,75	6,00	14,50	5,00	370,946,78	35,16	0,81	3,61	
Q3	1182,42	48,00	34,25	42,25	12,25	2,532,200,28	64,50	1,94	12,30	

**Legend:** Q1, I quartile; Q3, III quartile.



**Fig. 1.** Figure 1 depicts the median percentage of platelets, red blood cells, immune cells and fibrin of each arterial clot in COVID-19 patients. (For interpretation of the references to colour in this figure legend, the reader is referred to the web version of this article.)

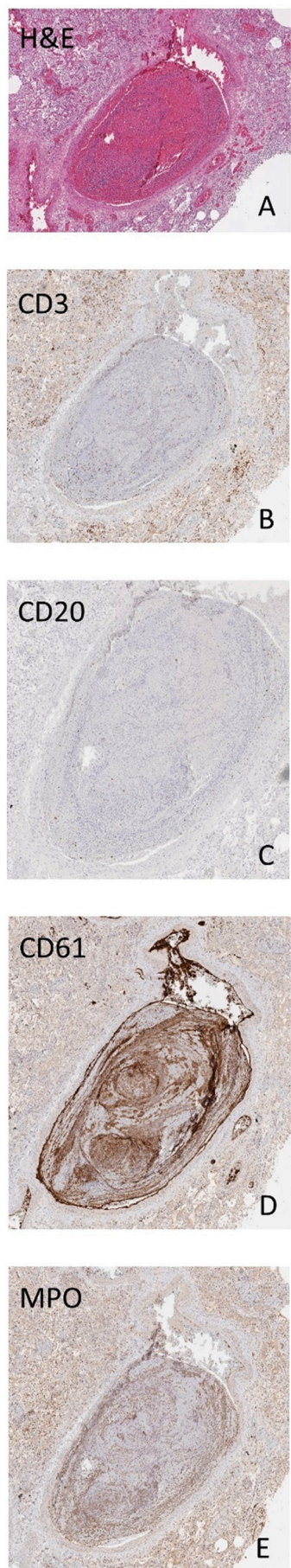
[median, IQR range: 756.30 µm (439.08–1182.42)], with no clot found in vessel less than or equal to 100 µm.

By immunohistochemistry, arterial thrombi were composed by white blood cells (WBC) [9.55 % (5–12.25)], mainly neutrophils [57.9 % (35.2–64.5)], followed by CD3+ lymphocytes [5.5 % (3.61–12.3)] and CD20+ lymphocytes [1.38 % (0.81–1.94)]; red blood cells [12 %, (6–34.25)], fibrin [19 % (14.5–42.25)], and platelets [38.5 %, (31.75–48)] completed the composition (Fig. 1). Megakaryocytes were not found. An example of the immunostaining study of the arterial thrombi has been reported in Fig. 2.

**4. Discussion**

Thrombosis is one of the most peculiar clinical manifestations of COVID-19, that distinguishes SARS-CoV-2 infection from other coronaviruses [13,16,28]. Pulmonary immunothrombosis is evident in over 90 % of severe disease cases [5], is independent of disease duration, and is much commoner than in influenza [28]. Histologic analysis of pulmonary vessels in patients with COVID-19 showed widespread thrombosis





**Fig. 2.** Images show an example of the morphological and immunochemistry study of the arterial thrombi, with Hematoxylin and Eosin staining (panel A), CD3 (panel B) and CD20 (panel C) immunostaining for lymphocytes, CD61 immunostaining for platelets (panel D) and myeloperoxidase (MPO) immunostaining for polymorphonuclear leukocytes (Panel E).

with microangiopathy [28], vessels of all size being involved, and the thrombotic material often grossly visible [29]. This pulmonary immunopathology has been well-reviewed and is being termed as PIC as opposed to overt DIC [30]. While deep venous thrombosis and pulmonary embolism are well documented in COVID-19, in situ pulmonary arterial thrombosis is much rarer and less investigated [6,13,14]. By adopting stringent exclusion criteria, only fatal COVID-19 cases with primary arterial thrombosis were studied, even if the absence of macroscopic peripheral thrombosis does not necessarily imply that the thrombi developed primarily in the pulmonary vessels. The present study highlights, for the first time, by in-depth immune pathology analysis, that pulmonary arterial thrombi are enriched by white blood cells, in particular neutrophils, supporting their inflammatory nature. White blood cell count herein resulted 6-times greater than common values seen in non-inflammatory thrombi, as recently reported in the literature [31]. Neutrophils as well as platelets are key modulators of thrombosis. Significant NETosis is found in patients with severe COVID-19 and is important in thrombus aetiology [32]. NETs can bind to platelets, triggering platelet activation, and through their citrullinated histone H3 (citH3) they can also interact with procoagulant von Willebrand factor (VWF) [33]. Also, pathological comparisons between SARS-CoV-2 and influenza-affected lung specimens showed that vascular neutrophil recruitment, NETosis, and immunothrombosis are typical features of severe COVID-19, but less prominent in influenza pneumonia [34]. Inflammation-induced-thrombosis is a well-described condition in other rheumatic diseases [35], especially in Behçet syndrome (BS) [36,37], where perivascular infiltrates in BS are predominantly constituted by neutrophils and lymphocytes [36]. Indeed, targeting neutrophil hyperactivation and systemic inflammation is key in the treatment of BS [36,38,39]. Hence, suppressing inflammation, rather than anticoagulation, is the mainstay of treatment for arterial involvement in BS (particularly referring to pulmonary arteries) [36]. Interestingly, some of the anti-cytokine therapies employed in BS, which have TNF, IL-1 or IL-6 as targets, have been also evaluated for the treatment of severe COVID-19 patients, with some positive results [40–42]. In that context, other inflammatory effectors under investigation are G-CSF and the GM-CSF [43,44], probably involved in triggering cytokine storm and in alveolar damage due to inadequate activation of macrophages. A monoclonal antibody against its receptor (mavrilimumab) seems to improve the outcomes in severe COVID-19 patients, attenuating lung hyper inflammation, but more data are mandatory [45,46].

Of note, all thrombi reported in our series were found in macrovessels (diameter > 100  $\mu\text{m}$ ), and no microthrombi nor megakaryocytes were identified. Microthrombi in COVID-19 autopsies may be found in many organs and are more frequent in patients with comorbidity, pulmonary embolism, and lung infarct [12]. Importantly, as exclusion criterion, in our series there were no macroscopic evidence of peripheral thrombosis, thus, this further supports the in situ formation of the arterial thrombi we found. Anyway, in a large retrospective US cohort, the risk of arterial thrombosis in COVID-19 was not higher than that reported in influenza [47], even if this comparison is still controversial.

Interestingly, in 75 published COVID-19 autopsies, pulmonary artery thrombosis/embolism was reported in 36 %, and the comparison of macroscopic autopsy findings showed a significantly higher rate of pulmonary macrothrombi in patients with COVID-19 in comparison to influenza A autopsies even though most patients received empiric thromboprophylaxis, as occurred in our series. This observation reinforces the concept of a SARS-related immune thrombosis with in situ clot formation [48,49]. Several randomized trials (e.g. REMAP-CAP, ATTACC, ACTIV-4a, and MICHELLE) [50–53] did not find significant

(caption on next column)

advantages from therapeutic anticoagulation in COVID-19 patients but they hypothesize that antithrombotic therapy might be important in some patients, even if that a possible subgroup was still not identified and no validated systems of stratification are available; furthermore, benefits of antithrombotic therapies may depend on the timing of treatment initiation, especially when thrombi could be already developed [53,54]. In this context, patients' risk stratification could be crucial, as applied in antiphospholipid syndrome, in which therapeutic interventions are individualized based on the thrombotic risk, ranging from antiplatelet agents to the association with anticoagulants [55,56].

Many autopsy studies found megakaryocytes to be numerically higher in COVID-19 patient lungs than in the lungs of other patients with ARDS, indicating active local platelet production, however, some studies did not report this finding [22]. Alveolar capillaries and microvasculature of the lung showed the presence of megakaryocytes, thus supporting the relationship with microthrombosis rather than with macrothrombosis [57], and possibly explaining why megakaryocytes were absent in our series.

Notably, our patients with pulmonary arterial thrombosis showed higher levels of LDH and platelet count at hospital admission, while significantly increased values of D-dimer when transferring to ICU. All of these laboratory alterations, even if no specific, link the hyper-inflammatory state with organ damage (mainly in the lung) and the hypercoagulable state.

Moreover, it seems that patients experiencing pulmonary arterial thrombosis may be a subgroup that develops more lung damage, inflammation, and hypercoagulability. Thus, LDH, D-dimer, and platelet count may be considered possible biomarkers of major thrombotic events, especially in the arterial pulmonary tree.

This study has some limitations, notably the small number of patients in both the case group and the control group. However, the characterization of pulmonary arterial thrombosis was done comprehensively by integrating data from different sources at different levels: clinical, laboratory, histopathological and immunological. In addition, we did not compare COVID-19 pulmonary arterial thrombi with arterial thrombi from other sources or with non-COVID-19 patients. However, the different composition of arterial and venous thrombi and pulmonary emboli has been extensively studied in a recent paper [22], which was used here for an indirect comparison. Finally, other markers of cardiac damage, such as troponin or creatine kinase, were not available in all the patients at different time points, and, therefore, they were not included in the statistical analyses.

In summary, based on histopathological and laboratory analyses, we confirm that pulmonary arterial thrombosis in COVID-19 is an immune-mediated inflammatory thrombosis. Some markers of inflammation, necrosis, and coagulation are markedly elevated in this group of patients dying from COVID-19 and this is linked to pulmonary artery immunothrombosis. Risk management of arterial thrombosis, as well as appropriate treatment of this complication are needed to tackle mortality in severe COVID-19.

## Funding

This research did not receive any specific grant from funding agencies in the public, commercial, or not-for-profit sectors.

## CRediT authorship contribution statement

All the coauthors made substantial contributions to all of the following: the conception and design of the study, analysis, and interpretation of data, drafting the article or revising it critically for important intellectual content, final approval of the version to be submitted.

## Declaration of competing interest

The authors declare that they have no known competing financial

interests or personal relationships that could have appeared to influence the work reported in this paper.

## Appendix A. Supplementary data

Supplementary data to this article can be found online at <https://doi.org/10.1016/j.thromres.2022.09.012>.

## References

- [1] W.J. Wiersinga, A. Rhodes, A.C. Cheng, S.J. Peacock, H.C. Prescott, Pathophysiology, transmission, diagnosis, and treatment of coronavirus disease 2019 (COVID-19): a review, *JAMA* 324 (8) (2020) 782–793.
- [2] E. Seyed Hosseini, N. Riahi Kashani, H. Nikzad, J. Azadbakht, H. Hassani Bafrani, Kashani H. Haddad, The novel coronavirus Disease-2019 (COVID-19): mechanism of action, detection, and recent therapeutic strategies, *Virology* 551 (2020) 1–9.
- [3] J. Baj, H. Karakula-Juchnowicz, G. Teresiński, G. Buszewicz, M. Ciesielka, E. Sitarz, et al., COVID-19: specific and non-specific clinical manifestations and symptoms: the current state of knowledge, *J. Clin. Med.* 9 (6) (2020) 1753.
- [4] A. Albini, G. Di Guardo, D.M. Noonan, M. Lombardo, The SARS-CoV-2 receptor, ACE-2, is expressed on many different cell types: implications for ACE-inhibitor- and angiotensin II receptor blocker-based cardiovascular therapies, *Intern. Emerg. Med.* 15 (5) (2020) 759–766.
- [5] N. Tang, D. Li, X. Wang, Z. Sun, Abnormal coagulation parameters are associated with poor prognosis in patients with novel coronavirus pneumonia, *J. Thromb. Haemost.* 18 (4) (2020) 844–847.
- [6] H. Bösmüller, M. Matter, F. Fend, A. Tzankov, The pulmonary pathology of COVID-19, *Virchows Arch.* 478 (1) (2021) 137–150.
- [7] M. Zuin, C. Bilato, L. Quadretti, M. Vatrano, M. Navaro, G. Rigatelli, et al., Tasso di embolia polmonare acuta nei pazienti ospedalizzati per COVID-19 in Italia. Metanalisi aggregata [Incidence of acute pulmonary embolism in hospitalized COVID-19 Italian patients. A pooled meta-analysis], *G Ital Cardiol* 23 (4) (2022) 233–243. Italian.
- [8] M. Zuin, M.M. Engelen, C. Bilato, T. Vanassche, G. Rigatelli, P. Verhamme, et al., Prevalence of acute pulmonary embolism at autopsy in patients with COVID-19, *Am. J. Cardiol.* 171 (2022) 159–164.
- [9] S.M. Morrissey, A.E. Geller, X. Hu, D. Trier, C. Ding, C.K. Klaes, et al., A specific low-density neutrophil population correlates with hypercoagulation and disease severity in hospitalized COVID-19 patients, *JCI Insight* 6 (9) (2021), 148435.
- [10] V. Deshmukh, R. Motwani, A. Kumar, C. Kumari, K. Raza, Histopathological observations in COVID-19: a systematic review, *J. Clin. Pathol.* 74 (2) (2021) 76–83.
- [11] S. Peiris, H. Mesa, A. Aysola, J. Manivel, J. Toledo, M. Borges-Sa, et al., Pathological findings in organs and tissues of patients with COVID-19: a systematic review, *PLoS One* 16 (4) (2021), e0250708.
- [12] R. Parra-Medina, S. Herrera, J. Mejía, Systematic review of microthrombi in COVID-19 autopsies, *Acta Haematol.* 144 (5) (2021) 476–483.
- [13] D. McGonagle, J.S. O'Donnell, K. Sharif, P. Emery, C. Bridgewood, Immune mechanisms of pulmonary intravascular coagulopathy in COVID-19 pneumonia, *Lancet Rheumatol.* 2 (7) (2020) e437–e445.
- [14] F. De Cobelli, D. Palumbo, F. Ciceri, G. Landoni, A. Ruggeri, P. Rovere-Querini, et al., Pulmonary vascular thrombosis in COVID-19 pneumonia, *J. Cardiothorac. Vasc. Anesth.* 35 (12) (2021) 3631–3641.
- [15] M. Leppkes, J. Knopf, E. Naschberger, A. Lindemann, J. Singh, I. Herrmann, et al., Vascular occlusion by neutrophil extracellular traps in COVID-19, *EBioMedicine* 58 (2020 Aug), 102925.
- [16] J.M. Connors, J.H. Levy, COVID-19 and its implications for thrombosis and anticoagulation, *Blood* 135 (23) (2020) 2033–2040.
- [17] M. Levi, J. Thachil, T. Iba, J.H. Levy, Coagulation abnormalities and thrombosis in patients with COVID-19, *Lancet Haematol.* 7 (6) (2020) e438–e440.
- [18] V. Sekhawat, A. Green, U. Mahadeva, COVID-19 autopsies: conclusions from international studies, *Diagn. Histopathol. (Oxf.)* 27 (3) (2021) 103–107.
- [19] A. Best Rocha, E. Stroberg, L.M. Barton, E.J. Duval, S. Mukhopadhyay, N. Yarid, et al., Detection of SARS-CoV-2 in formalin-fixed paraffin-embedded tissue sections using commercially available reagents, *Lab. Invest.* 100 (11) (2020) 1485–1489. <https://doi.org/10.1016/j.lfs.2022.120602>. Epub 2022 May 1 PMID: 35508253.
- [20] A. Bugra, T. Das, M.N. Arslan, N. Ziyade, Y. Buyuk, Postmortem pathological changes in extrapulmonary organs in SARS-CoV-2 rt-PCR-positive cases: a single-center experience, *Ir. J. Med. Sci.* 191 (1) (2022) 81–91.
- [21] S.E. Fox, A. Akmatbekov, J.L. Harbert, G. Li, J. Quincy Brown, R.S. Vander Heide, Pulmonary and cardiac pathology in African American patients with COVID-19: an autopsy series from New Orleans, *Lancet Respir. Med.* 8 (7) (2020) 681–686.
- [22] K. Dwiputra Hernugrahanto, D. Novembri Utomo, H. Hariman, N.C. Budhiparama, D. Medika Hertanto, D. Santoso, et al., Thromboembolic involvement and its possible pathogenesis in COVID-19 mortality: lesson from post-mortem reports, *Eur. Rev. Med. Pharmacol. Sci.* 25 (3) (2021) 1670–1679.
- [23] D.Y. Huang, G.M. Wang, Z.R. Ke, Y. Zhou, H.H. Yang, T.L. Ma, C.X. Guan, Megakaryocytes in pulmonary diseases, *Life Sci.* 301 (2022), 120602, <https://doi.org/10.1016/j.lfs.2022.120602>.
- [24] H. Bösmüller, M. Matter, F. Fend, A. Tzankov, The pulmonary pathology of COVID-19, *Virchows Arch.* 478 (1) (2021) 137–150.
- [25] D.A. Gorog, R.F. Storey, P.A. Gurbel, U.S. Tantry, J.S. Berger, M.Y. Chan, et al., Current and novel biomarkers of thrombotic risk in COVID-19: a consensus

- statement from the International COVID-19 Thrombosis Biomarkers Colloquium, *Nat. Rev. Cardiol.* 19 (2022) 475–495.
- [26] D. McGonagle, M.F. Kearney, A. O'Regan, J.S. O'Donnell, L. Quartuccio, A. Watad, et al., Therapeutic implications of ongoing alveolar viral replication in COVID-19, *Lancet Rheumatol.* 4 (2) (2022) e135–e144.
- [27] M. Candeloro, S. Schulman, Arterial thrombotic events in hospitalized COVID-19 patients: a short review and meta-analysis, *Semin. Thromb. Hemost.* 6 (2022 Jul), <https://doi.org/10.1055/s-0042-1749661>.
- [28] M. Ackermann, S.E. Verleden, M. Kuehnel, A. Haverich, T. Welte, F. Laenger, et al., Pulmonary vascular endothelialitis, thrombosis, and angiogenesis in Covid-19, *N. Engl. J. Med.* 383 (2) (2020) 120–128.
- [29] S.F. Lax, K. Skok, P. Zechner, H.H. Kessler, N. Kaufmann, C. Koelblinger, et al., Pulmonary arterial thrombosis in COVID-19 with fatal outcome: results from a prospective, single-center, clinicopathologic case series, *Ann. Intern. Med.* 173 (5) (2020) 350–361.
- [30] D. McGonagle, K. Sharif, A. O'Regan, C. Bridgewood, The role of cytokines including Interleukin-6 in COVID-19 induced pneumonia and macrophage activation syndrome-like disease, *Autoimmun. Rev.* 19 (6) (2020), 102537.
- [31] I.N. Chernysh, C. Nagaswami, S. Kosolapova, A.D. Peshkova, A. Cuker, D.B. Cines, et al., The distinctive structure and composition of arterial and venous thrombi and pulmonary emboli, *Sci. Rep.* 10 (1) (2020) 5112.
- [32] E. Folco, T. Mawson, A. Vromman, B. Bernardes-Souza, G. Franck, O. Persson, et al., Neutrophil extracellular traps induce endothelial cell activation and tissue factor production through interleukin-1 $\alpha$  and cathepsin G, *Arterioscler. Thromb. Vasc. Biol.* 38 (2018) 1901–1912.
- [33] D.D. Wagner, L.A. Heger, Thromboinflammation: from atherosclerosis to COVID-19, *Arterioscler. Thromb. Vasc. Biol.* 8 (2022 Jul), <https://doi.org/10.1161/ATVBAHA.122.317162>.
- [34] L. Nicolai, A. Leunig, S. Brambs, R. Kaiser, M. Joppich, M.L. Hoffknecht, et al., Vascular neutrophilic inflammation and immunothrombosis distinguish severe COVID-19 from influenza pneumonia, *J. Thromb. Haemost.* 19 (2) (2021) 574–581.
- [35] F. Cacciapaglia, F.R. Spinelli, M. Piga, G.L. Erre, G. Sakellariou, A. Manfredi, et al., Estimated 10-year cardiovascular risk in a large Italian cohort of rheumatoid arthritis patients: data from the Cardiovascular Obesity and Rheumatic Disease (CORDIS) Study Group, *Eur. J. Intern. Med.* 96 (2022) 60–65.
- [36] G. Emmi, A. Bettiol, E. Silvestri, G. Di Scala, M. Becatti, C. Fiorillo, et al., Vascular Behçet's syndrome: an update, *Intern. Emerg. Med.* 14 (5) (2019) 645–652.
- [37] A. Bettiol, D. Prisco, G. Emmi, Behçet: the syndrome, *Rheumatology* 59 (Suppl 3) (2020) iii101–iii107.
- [38] C. Angelidis, Z. Kotsialou, C. Kossyvakis, A.-R. Vrettou, A. Zacharoulis, F. Kolokathis, et al., Colchicine pharmacokinetics and mechanism of action, *Curr. Pharm. Des.* 24 (6) (2018) 659–663.
- [39] O. Karadag, E.C. Bolek, Management of Behçet's syndrome, *Rheumatology* 59 (Suppl 3) (2020) iii108–iii117.
- [40] E. Kyriazopoulou, T. Huet, G. Cavalli, A. Gori, M. Kyprianou, P. Pickkers, et al., Effect of anakinra on mortality in patients with COVID-19: a systematic review and patient-level meta-analysis, *Lancet Rheumatol.* 3 (10) (2021) e690–e697.
- [41] M. Soy, G. Keser, P. Atagündüz, F. Tabak, I. Atagündüz, S. Kayhan, Cytokine storm in COVID-19: pathogenesis and overview of anti-inflammatory agents used in treatment, *Clin. Rheumatol.* 39 (7) (2020) 2085–2094.
- [42] R. Borie, L. Savale, A. Dossier, J. Ghosn, C. Taillé, B. Visseaux, et al., Glucocorticoids with low-dose anti-IL1 anakinra rescue in severe non-ICU COVID-19 infection: a cohort study, *PLoS One* 15 (12) (2020), e0243961.
- [43] A. Bonaventura, A. Vecchié, T.S. Wang, E. Lee, P.C. Cremer, B. Carey, et al., Targeting GM-CSF in COVID-19 pneumonia: rationale and strategies, *Front. Immunol.* 11 (2020) 1625.
- [44] P. Vijayvargiya, Z. Esquer Garrigos, N.E. Castillo Almeida, P.R. Gurram, R. W. Stevens, R.R. Razonable, Treatment considerations for COVID-19: a critical review of the evidence (or lack thereof), *Mayo Clin. Proc.* 95 (7) (2020) 1454–1466.
- [45] P.C. Cremer, A. Abbate, K. Hudock, C. McWilliams, J. Mehta, S.Y. Chang, et al., Mavrilimumab in patients with severe COVID-19 pneumonia and systemic hyperinflammation (MASH-COVID): an investigator initiated, multicentre, double-blind, randomised, placebo-controlled trial, *Lancet Rheumatol.* 3 (6) (2021) e410–e418.
- [46] G. De Luca, G. Cavalli, C. Campochiaro, E. Della-Torre, P. Angelillo, A. Tomelleri, et al., GM-CSF blockade with mavrilimumab in severe COVID-19 pneumonia and systemic hyperinflammation: a single-centre, prospective cohort study, *Lancet Rheumatol.* 2 (8) (2020) e465–e473.
- [47] A. Ward, A. Sarraju, D. Lee, K. Bhasin, S. Gad, R. Beutel, et al., COVID-19 is associated with higher risk of venous thrombosis, but not arterial thrombosis, compared with influenza: insights from a large US cohort, *PLoS One* 17 (1) (2022), e0261786.
- [48] N.M. Burkhard-Koren, M. Haberecker, U. Maccio, F. Ruschitzka, R.A. Schuepbach, A.S. Zinkernagel, et al., Higher prevalence of pulmonary macrothrombi in SARS-CoV-2 than in influenza a: autopsy results from 'Spanish flu' 1918/1919 in Switzerland to coronavirus disease 2019, *J. Pathol. Clin. Res.* 7 (2) (2021) 135–143.
- [49] S.F. Lax, K. Skok, P. Zechner, H.H. Kessler, N. Kaufmann, C. Koelblinger, et al., Pulmonary arterial thrombosis in COVID-19 with fatal outcome: results from a prospective, single-center, clinicopathologic case series, *Ann. Intern. Med.* 173 (5) (2020) 350–361.
- [50] ATTACC Investigators, ACTIV-4a Investigators, REMAP-CAP Investigators, P. R. Lawler, E.C. Goligher, J.S. Berger, Therapeutic anticoagulation with heparin in noncritically ill patients with Covid-19, *N. Engl. J. Med.* 385 (9) (2021) 790–802.
- [51] B.L. Houston, P.R. Lawler, E.C. Goligher, M.E. Farkouh, C. Bradbury, M. Carrier, et al., Anti-thrombotic therapy to ameliorate complications of COVID-19 (ATTACC): study design and methodology for an international, adaptive Bayesian randomized controlled trial, *Clin. Trials* 17 (5) (2020) 491–500.
- [52] REMAP-CAP Investigators, ACTIV-4a Investigators, ATTACC Investigators, E. C. Goligher, C.A. Bradbury, McVerry BJ, Therapeutic Anticoagulation with Heparin in Critically Ill Patients with Covid-19, *N. Engl. J. Med.* 385 (9) (2021) 777–789.
- [53] E. Ramacciotti, L. Barile Agati, D. Calderaro, V.C.R. Aguiar, A.C. Spyropoulos, C.C. C. de Oliveira, et al., Rivaroxaban versus no anticoagulation for post-discharge thromboprophylaxis after hospitalisation for COVID-19 (MICHELLE): an open-label, multicentre, randomised, controlled trial, *Lancet* 399 (10319) (2022) 50–59.
- [54] RECOVERY Collaborative Group, Aspirin in patients admitted to hospital with COVID-19 (RECOVERY): a randomised, controlled, open-label, platform trial, *Lancet* 399 (10320) (2022) 143–151.
- [55] I. Calcaterra, A. Tufano, R. Lupoli, G. Iannuzzo, G. Emmi, M.N.D. Di Minno, Cardiovascular disease and antiphospholipid syndrome: how to predict and how to treat? *Pol. Arch. Intern. Med.* 131 (2) (2021) 161–170.
- [56] M.G. Tektonidou, L. Andreoli, M. Limper, A. Tincani, M.M. Ward, Management of thrombotic and obstetric antiphospholipid syndrome: a systematic literature review informing the EULAR recommendations for the management of antiphospholipid syndrome in adults, *RMD Open* 5 (1) (2019), e000924.
- [57] A.V. Rapkiewicz, X. Mai, S.E. Carsons, S. Pittaluga, D.E. Kleiner, J.S. Berger, et al., Megakaryocytes and platelet-fibrin thrombi characterize multi-organ thrombosis at autopsy in COVID-19: a case series, *EclinicalMedicine* 24 (2020), 100434.