



UNIVERSITÀ
DEGLI STUDI
DI UDINE

Università degli studi di Udine

Cytoreductive Surgery and Hyperthermic Intrathoracic
Chemotherapy by Video-Assisted Surgery for Pleural

Original

Availability:

This version is available <http://hdl.handle.net/11390/1231464> since 2022-09-04T20:19:40Z

Publisher:

Published

DOI:

Terms of use:

The institutional repository of the University of Udine (<http://air.uniud.it>) is provided by ARIC services. The aim is to enable open access to all the world.

Publisher copyright

(Article begins on next page)



Cytoreductive Surgery and Hyperthermic Intrathoracic Chemotherapy by Video-Assisted Surgery for Pleural Malignancies: Technical Aspects and Safety Profile

Francesco Londero^{1*}, Gianluca Masullo^{1*}, William Grossi¹, Elisa De Franceschi¹, Jacqueline Cinel¹, Nicola Vernaccin², Nunzio Davide de Manna¹, Stefano Bacchetti², Igor Vendramin¹, Gianluigi Adan², Angelo Morelli¹ and Enrico Maria Pasqual^{2*}

¹Department of Cardiothoracic Surgery, Azienda Sanitaria Universitaria Friuli Centrale, University Hospital Santa Maria della Misericordia, Italy

²Department of General Surgery, Center for Advanced Surgical Oncology, Azienda Sanitaria Universitaria Friuli Centrale, University Hospital Santa Maria della Misericordia, Italy

*These authors contributed equally to this work

Abstract

Background: Pleural malignancies are challenging conditions in terms of possibility of cure. Recent growing interest towards Hyperthermic Intrathoracic Chemotherapy (HITHOC) after Cytoreductive Surgery (CRS) has been referred. Minimally invasive approach (VATS) may be suggest in this context but evidence is still lacking.

Methods: A preliminary experience in seven patients submitted to cytoreductive surgery and HITHOC is described, with a focus on technical aspects related to VATS approach, operating median time and postoperative complication.

Results: A triportal VATS approach has been employed in all cases. Median time of surgery including pleural perfusion was 200 min (range 165 to 370). Mean blood loss was 217 cc (range 100 and 600). Thirty days mortality was nothing.

Conclusion: VATS cytoreductive surgery and HITHOC is a safe procedure and could be proposed in the setting of a multimodality strategy employing adjuvant radio-chemotherapy in referral centers.

Keywords: Pleura; Mesothelioma; Thymoma; HITHOC; Cytoreductive surgery; VATS

OPEN ACCESS

*Correspondence:

Enrico Maria Pasqual, Department of General Surgery, Center for Advanced Surgical Oncology, Azienda Sanitaria Universitaria Friuli Centrale, University Hospital Santa Maria della Misericordia, Udine, Italy, E-mail: enricomaria.pasqual@uniud.it

Received Date: 26 Aug 2021

Accepted Date: 13 Oct 2021

Published Date: 25 Oct 2021

Citation:

Londero F, Masullo G, Grossi W, De Franceschi E, Cinel J, Vernaccini N, et al. Cytoreductive Surgery and Hyperthermic Intrathoracic Chemotherapy by Video-Assisted Surgery for Pleural Malignancies: Technical Aspects and Safety Profile. *Clin Surg*. 2021; 6: 3339.

Copyright © 2021 Enrico Maria Pasqual. This is an open access article distributed under the Creative Commons Attribution License, which permits unrestricted use, distribution, and reproduction in any medium, provided the original work is properly cited.

Introduction

Pleural malignancies, both of primary or metastatic are challenging conditions in terms of possibility of cure. Malignant Pleural Mesothelioma (MPM) is still considered a fatal disease, despite the combination of aggressive surgical procedures and systemic treatments, with a median survival time of 1 year [1]. Pleural metastases from distant tumors usually represent a terminal stage of disease, and their treatments are focused on reducing symptoms related to the presence of pleural effusion and reduction of respiratory function [2]. In patients with thymic malignancies, development of pleural metastases after radical resection of the primary is usually a consequence of exfoliation of cells from the thymoma or local seeding during surgical manipulation and in this context no curative treatment is available [3]. In the last two decades increasing attention has been paid to the application of protocols implying Cytoreductive Surgery (CRS) and intraoperative intrathoracic administration of Heated Chemotherapy (HITHOC), in the attempt of maximizing the cytotoxic effects of the employed drugs. Several papers showed promising results in terms of local control of disease and prolongation of life when treating MPM and pleural metastases from thymic tumors [3-5]. In the large majority of studies the surgical procedures were carried on through an open approach, while scarce information is available regarding the application of video-assisted thoracic surgery. We hereby present the description of our technique of CRS and HITHOC using a VATS approach and report our preliminary experience with a short series of patients submitted to Pleurectomy/Decortication (P/D) and HITHOC by VATS for mesothelioma and pleural metastases from thymic tumors, with a focus on safety and tolerability of the procedure.

Materials and Methods

Approval was waived by the local Ethics Committee due to the retrospective nature of the study, according to National Laws regulating observational retrospective studies (Italian law nr. 11960, released on 13/07/2004). However, all patients gave their written consent for use of their personal data for scientific purposes. We included all patients submitted to pleurectomy/decortication and intracavitary chemohyperthermia for MPM and pleural metastases from thymic tumors in a single institution (Santa Maria della Misericordia University Hospital, Udine, Italy) in the interval January 2015 - December 2018.

Patients selection

All patients were discussed at our local multidisciplinary board involving oncologists, chest physicians, thoracic oncology surgeons, radiologists, radiation oncologists and pathologists. General prerequisites for being enrolled for surgery were: 1) performance status 0-1; 2) adequate respiratory function at preoperative spirometry; 3) normal cardiac function. For MPM, patients were proposed for surgery in case of histology proven MPM with unilateral disease, clinical stage 1 - based on radiological tomographic investigations and diagnostic thoracoscopy - and lesions considered technically resectable. For thymoma pleural metastases, patients were enrolled for surgery when all visible lesions were deemed resectable, in case of unilateral disease and absence of other localizations due to neoplastic spread.

Surgical procedures

Patients were intubated with a double lumen tube to allow selective lung exclusion from ventilation during surgery. Patients were therefore posed in a contralateral decubitus and a 4 cm long utility port was performed in the 5th intercostal space on the anterior axillary line. A 30° 10 mm camera was then inserted through the utility port, and after verifying the correct lung deflation and identifying the lower landmark represented by the diaphragm, two further 2 cm long ports were practiced under camera vision, usually in the 8th intercostal space on the posterior axillary line and in the 7th intercostal space on the middle-anterior axillary line (Figure 1A). Subsequently, a complete surgical removal of the parietal and mediastinal pleura was performed; when present, diaphragmatic nodules were excised with enough margins to guarantee a macroscopic complete resection. During mediastinal pleura removal, attention was paid to preserve the phrenic nerve and the vascular structures, unless they were macroscopically involved by tumor deposits. The lung was routinely explored on its surface and within fissures to rule out visceral pleura seeding: in case of macroscopic nodules, these were resected with wedge resections - for larger and deeper deposits - or diathermy - for nodules up to 3 mm large. All specimens were removed from the pleural cavity with a disposable retrieval bag in order to avoid seeding through the surgical ports. Eventually a further resection of the muscular and fat tissue around the ports was performed in order to prevent tumor recurrence at this level.

Intrapleural heated chemotherapy perfusion

After completion of the CRS, three chest tubes were inserted under camera vision through the surgical ports; the lung was partially re-expanded and kept semi-inflated during pleural lavage [1]. Chest drains were positioned as follows (Figure 1B): two drains were positioned respectively anteriorly with a paramediastinic course and posteriorly behind the pulmonary hylum to the pulmonary apex.

The course of the third drain within the chest cavity was as lateral as possible, in order to be as high as possible while the patient was laying on his/her contralateral decubitus on the operative table. This was done with the aim of guaranteeing a complete exposure of the lung surface and the inner layer of the pleural cavity to the action of the chemotherapeutic agent. The tubes were then connected to the extracorporeal circuit (RAND-Performer LRT®, RAND S.r.l. - Medtronic, Medolla (MO), Italy) and intrapleural perfusion started. The circuit was composed by 4 roller pumps, a fluid heater plate, and a reservoir. In the first phase of HITHOC the paramediastinic drains were used as inflow catheters to fill the cavity with 38°C 0.9% saline. When the fluid started to flow outwards through the lateral drain and after stabilization of the circuit flow, the lavage saline was further heated until reaching the final 42°C temperature and cisplatin was progressively added to the infusion solution at the dose of 100 mg/m² of body surface, this latter calculated according to the Mosteller formula [6]. Subsequently, a continuous flow pleural lavage was carried out for 1 h at the average speed of 1 L/min. The perfusate temperature was monitored using 4 thermal probes posed on the perfusion system respectively just before and after the heater and on the inflow and outflow catheters within 30 cm from the patient's skin. Patients' central temperature was monitored with a thermal probe connected to the urinary catheter, routinely inserted before surgical incision. At the end of pleural lavage, the fluid containing the chemotherapy agent was completely drained out, the cavity washed with pure 0.9% saline and chest drains connected to a standard drain system (Pleurevac®) under mild suction (-15 cmH₂O). Eventually, according to respiratory and circulatory parameters, the patient was transferred to Intensive Care Unit (ICU) department or extubated and transferred to surgical ward.

Post-operative monitoring and follow-up

Patients were systematically hydrated with 1 ml/kg/h 0.9% NaCl for the first 2 days post-operatively. During in-hospital stay patients were monitored with daily full blood count and renal function test for the first 5 days in order to identify early signs of nephrotoxicity. After discharge patients were followed up with CT scan every 3 months for the first 2 years, and every 6 months for 5 years thereafter. The primary outcome we investigated on was safety of HITHOC, with particular referral to renal function impairment due to cisplatin administration.

Results

Patients' characteristics

During the time interval seven patients underwent CRS and HITHOC for MPM or pleural metastases from thymoma and were therefore included in the study. Preoperative characteristics of patients are reported in Table 1. Five patients had MPM, and two were operated on for unilateral pleural metastases from thymoma. All patients were identified as American Society of Anesthesiology (ASA) score 3.

Surgical procedures

All surgical procedures were performed via a triportal VATS approach. Median time of surgery including pleural perfusion was 200 min (range 165 to 370). In order to guarantee a macroscopic radical resection, in both cases of thymoma metastases a partial resection of the diaphragm and multiple pulmonary wedge resections were carried out and confirmed tumor deposits at histology report. In 1 case of MPM a partial resection of the diaphragm was necessary to guarantee macroscopic resection of tumor and in another case a

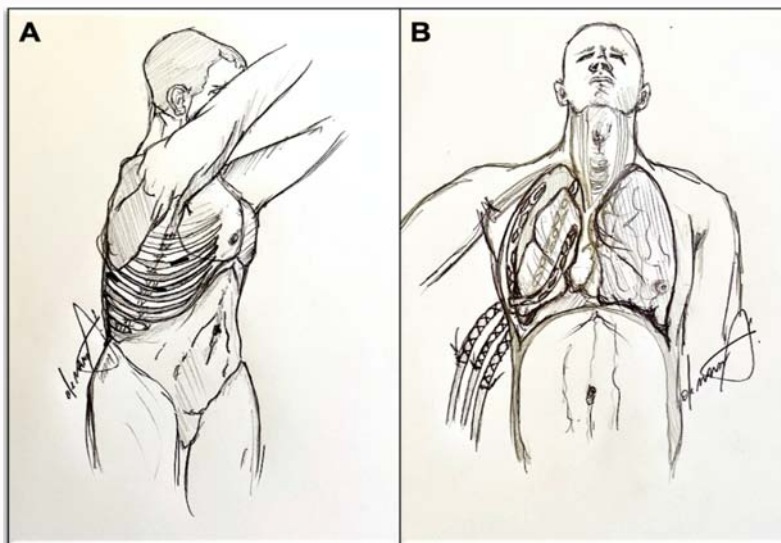


Figure 1: A. Position of patient and surgical ports. B. Position of chest drains for HITHOC.

Table 1: Patients' and tumors' characteristics.

	Age	Gender	Tumor/Histology	Comorbidities	Neoad	Ad
1	59	M	MPM, epithelioid	Previousbladdercancer	None	CT+RT
2	72	M	MPM, epithelioid	Hypertension, previousgastric GIST	None	None
3	69	M	MPM, biphasic	Hypertension	None	CT+RT
4	77	F	Thymoma, B2	COPD, Reumathoidarthritis, SLE	None	CT
5	76	M	MPM, epithelioid	Arteriopathy, COPD, previous colon cancer	None	CT+RT
6	79	M	MPM, epithelioid	AF, DM, hypertension	CT	CT
7	66	M	Thymoma, B2	Hypertension, DM	None	none

Abbreviations: AF: Atrial Fibrillation; COPD: Chronic Obstructive Pulmonary Disease; CT: Chemotherapy; DM: Diabetes Mellitus; F: Female; GIST: Gastrointestinal Stromal Tumor; M: Male; MPM: Malignant Pleural Mesothelioma; RT: Radiotherapy; SLE: Systemic Lupus Erythematosus

Table 2: Outcomes.

	TOS (min)	ICU Duration (days)	Drain Removal (days)	In-Hospital Stay (days)	Complications	Post-operative PS* (Karnofsky)	Post-operative Pain* (NRS)
1	370	0	5	7	Late DiaphragmaticHernia	80	1
2	200	0	7	12	None	90	0
3	295	0	5	6	None	90	2
4	230	1	5	6	None	80	4
5	165	2	12	13	None	90	3
6	190	2	15	19	Haemoptisis	80	4
7	190	1	6	17	ARF	80	2

Abbreviations: ARF: Acute Renal Failure; ICU: Intensive Care Unit; NRS: Numeric Rating Scale; PS: Performance Status; TOS: Time of Surgery

*Assessed at 2 weeks after discharge

wedge resection was performed to remove a visceral pleura nodule with invasion of lung parenchyma. Estimated blood loss ranged between 100 and 600 cc (mean 217 cc).

Outcomes

Post-operative outcomes and morbidity are reported in Table 2. Thirty-day mortality was nothing. One MPM patient developed a late diaphragmatic hernia and underwent surgical repair 1 year after the cytoreductive surgery. Only one thymoma patient developed acute renal failure on post-operative day 2, treated with intravenous administration of saline and diuretics with progressive normalization of creatinine levels and no need for further medical treatment or dialysis. Another MPM patient required blood transfusions for early post-operative anemia, but no further treatment was required. At

two weeks after discharge, patients presented almost uniformly good clinical conditions and pain control.

Discussion

Pleural malignancies, both from primary and secondary origin are challenging conditions that benefit the most from a multidisciplinary approach. However, even with the best adherence of the patient to the proposed treatment plan, progression of disease is the most frequent eventuality. MPM is almost always a lethal disease, where no treatment has demonstrated a full effectiveness in preventing progression and death [7]. In early stages, where the tumor is localized to the parietal or visceral pleura, a surgical resection may be proposed in the setting of a multimodality treatment. Surgical treatment consists of two

main approaches: Pleurectomy/Decortication (P/D), consisting in the removal of all pleural surface, or Extrapleural Pneumonectomy (EPP), that reckons on en-bloc removal of all pleural layers, ipsilateral lung, pericardium and diaphragm, these two latter subsequently reconstructed with prosthetic patches. This approach is burdened with high post-operative mortality and morbidity and is therefore usually reserved for high volume specialized centers with strict patient's selection criteria [8]. Although EPP is a more extensive treatment and should theoretically guarantee a higher radicality, it has not been demonstrated to improve survival compared with less extensive interventions [8]. Therefore, it is evident how surgery alone cannot guarantee a radical microscopic resection and should only be proposed in the context of a multimodality treatment with chemo-radiotherapy [9]. MPM is sensitive to radiotherapy, but the tumor spreading pattern usually involves or get in close proximity with vital organs (heart, spinal cord) making it unlikely to deliver a therapeutic dose without significant side effects [7]. On the other hand chemotherapy, mainly with a combination therapy, has shown to be effective in prolonging time to progression and median survival [10] but the relative benefits may be counterbalanced by a significant impairment of quality of life [7]. Thymomas are relatively rare and usually indolent tumors, with an excellent prognosis in early stages after surgical resection [11]. In a minority of cases the tumor may recur, as a consequence of local spreading or surgical manipulation. Development of pleural metastases from thymoma configures a stage IV of disease where 10 years-OS, from nearly 100% of stage I-II, may decrease to 30% [12]. Response rates to chemotherapy are around 44% when the association of cisplatin/doxorubicin/cyclophosphamide is used [13], while in selected cases patients may still benefit of a multimodality treatment including repeated surgical resection [14]. In the perspective of maximizing the intrapleural cytotoxic effect of chemotherapy and reducing the systemic side effects of the drugs, in the last two decades an increasing application of HITHOC has been observed [15,16]. HITHOC is based on the perfusion of the pleural cavity with drugs that exert a direct cytotoxic effect on tumor cells. The most commonly used protocols employ cisplatin alone [17] or in combination with doxorubicin [1,15]. The use of mild hyperthermic perfusate enhances the cytotoxic effect of the drug and its penetration into tumoral deposits [18,19] and is known to induce apoptosis in both healthy and tumor cells [20,21]. Pharmacokinetics studies demonstrated that during HITHOC the chemotherapeutic agent is only partially absorbed by the systemic circulation, maximizing the local effect and reducing the incidence of adverse events related to its systemic toxicity [1]. The median depth of penetration of heated cisplatin was demonstrated to be as high as 3 mm to 4 mm [22], thus suggesting that it may be actually effective on microscopic residual disease following cytoreductive surgery. Cisplatin is partially absorbed by the lungs and soft tissues of the pleural cavity and gradually released into the systemic circulation [23] but pharmacokinetics investigations outlined that the drug concentration in the pleural fluid can reach a value >50-fold higher than in the serum [24]. This should maximize the therapeutic effect of cisplatin on the affected surfaces limiting the occurrence of systemic side-effects, namely acute renal failure. The frequency of renal impairment ranges widely between 3% to 57% after HITHOC [25] and seems to occur less frequently with adequate preservation of the kidney, through intravenous infusion of fluid and employment of nephroprotective drugs [25]. In our short series, probably due to the systematic use of a nephroprotection protocol in the first days after surgical procedures, a transient acute renal failure occurred in only 1 case (14.3%) and resolved within 14 days with no

need for major interventions. In our opinion this emphasizes the low impact that chemotherapy pleural lavage after standard cytoreductive surgery may have on the patients' general conditions, mainly when the surgical procedure is carried out through a minimally invasive approach. The use of HITHOC following P/D for MPM seem to offer a beneficial effect on reducing tumor progression and prolonging survival in several experiences [16,26]. VATS had a revolutionary effect on the practice of thoracic surgery, since when it was demonstrated that complex surgical resections could be performed with lower invasiveness without affecting the oncological effectiveness of the treatment [27]. Therefore, even in the context of pleural malignant disease, VATS should in our opinion gain an increasing application considering the low detrimental impact on the patients' general conditions and the increased chance to adhere to adjuvant treatments. VATS has the advantage of allowing a well-defined, complete and magnified exploration of the pleural cavity and, in our opinion, this might improve the detection of pleural implants and increase the completeness and precision of pleurectomy. However, since to date no prospective study assessed the comparative results of pleurectomy performed through an open versus a thoracoscopic approach, this statement should be interpreted with caution. Future research should prospectively assess the effectiveness of HITHOC compared with simple cytoreductive surgery in the context of a multimodality treatment and the role of VATS compared with standard open thoracotomy in the treatment of pleural malignancies.

Conclusion

HITHOC is a safe and effective adjuvant of CRS for the treatment of primary and metastatic pleural tumors in the setting of a multimodality treatment. The low invasiveness of this practice may improve the patient's adherence to adjuvant treatment protocols and therefore increase the chances of tumor control. In this context VATS may offer a valid and less invasive alternative to thoracotomy that may amplify the overall positive effects on the patient's outcome, but more research is needed on this topic.

References

1. de Bree E, van Ruth S, Baas P. Cytoreductive surgery and intraoperative hyperthermic intrathoracic chemotherapy in patients with malignant pleural mesothelioma or pleural metastases of thymoma. *Chest*. 2002;121(2):480-7.
2. Lee YC, Light RW, Musk AW. Management of malignant pleural mesothelioma: A critical review. *Current opinion in pulmonary medicine*. 2000;6(4):267-74.
3. Yu L, Jing Y, Ma S, Li F, Zhang YF. Cytoreductive surgery combined with hyperthermic intrapleural chemotherapy to treat thymoma or thymic carcinoma with pleural dissemination. *Onco Targets Ther*. 2013;6:517-21.
4. Ambrogi MC, Korasidis S, Lucchi M. Pleural recurrence of thymoma: Surgical resection followed by hyperthermic intrathoracic perfusion chemotherapy†. *Eur J Cardiothorac Surg*. 2016;49(1):321-6.
5. Refaely Y, Simansky DA, Paley M, Gottfried M, Yellin A. Resection and perfusion thermochemotherapy: A new approach for the treatment of thymic malignancies with pleural spread. *Ann Thorac Surg*. 2001;72(2):366-70.
6. Mosteller RD. Simplified calculation of body-surface area. *N Engl J Med*. 1987;317(17):1098.
7. Treasure T, Sedrakyan A. Pleural mesothelioma: Little evidence, still time to do trials. *Lancet (London, England)*. 2004;364(9440):1183-5.
8. Cao C, Tian D, Park J, Allan J, Pataky KA, Yan TD. A systematic review and

- meta-analysis of surgical treatments for malignant pleural mesothelioma. *Lung Cancer* (Amsterdam, Netherlands). 2014;83(2):240-5.
9. Kuribayashi K, Doi H, Kijima T. Types of surgery post-neoadjuvant chemotherapy for pleural mesothelioma. *Expert Rev Respir Med*. 2019;13(12):1189-94.
 10. Vogelzang NJ, Rusthoven JJ, Symanowski J, et al. Phase III study of pemetrexed in combination with cisplatin versus cisplatin alone in patients with malignant pleural mesothelioma. *J Clin Oncol*. 2003;21(14):2636-44.
 11. Dettterbeck FC, Parsons AM. Management of stage I and II thymoma. *Thorac Surg Clin*. 2011;21(1):59-67, vi-vii.
 12. Okumura M, Miyoshi S, Takeuchi Y. Results of surgical treatment of thymomas with special reference to the involved organs. *J Thorac Cardiovasc Surg*. 1999;117(3):605-13.
 13. Park S, Park IK, Kim YT. Comparison of neoadjuvant chemotherapy followed by surgery to upfront surgery for thymic malignancy. *Ann Thorac Surg*. 2019;107(2):355-62.
 14. Murakawa T, Karasaki T, Kitano K. Invasive thymoma disseminated into the pleural cavity: Mid-term results of surgical resection. *Eur J Cardiothorac Surg*. 2015;47(3):567-72.
 15. Ambrogi MC, Bertoglio P, Aprile V. Diaphragm and lung-preserving surgery with hyperthermic chemotherapy for malignant pleural mesothelioma: A 10-year experience. *J Thorac Cardiovasc Surg*. 2018;155(4):1857-66.e2.
 16. Sugarbaker DJ, Gill RR, Yeap BY. Hyperthermic intraoperative pleural cisplatin chemotherapy extends interval to recurrence and survival among low-risk patients with malignant pleural mesothelioma undergoing surgical macroscopic complete resection. *J Thorac Cardiovasc Surg*. 2013;145(4):955-63.
 17. Kodama K, Higashiyama M, Okami J. Cytoreductive surgery and post-operative heated pleural chemotherapy for the management of pleural surface malignancy. *Int J Hyperthermia*. 2013;29(7):653-62.
 18. van der Heijden AG, Verhaegh G, Jansen CF, Schalken JA, Witjes JA. Effect of hyperthermia on the cytotoxicity of 4 chemotherapeutic agents currently used for the treatment of transitional cell carcinoma of the bladder: An *in vitro* study. *J Urol*. 2005;173(4):1375-80.
 19. Ratto GB, Civalleri D, Esposito M. Pleural space perfusion with cisplatin in the multimodality treatment of malignant mesothelioma: A feasibility and pharmacokinetic study. *J Thorac Cardiovasc Surg*. 1999;117(4):759-65.
 20. Falkowska-Podstawka M, Wernicki A. Heat shock proteins in health and disease. *Pol J Vet Sci*. 2003;6(1):61-70.
 21. Qi D, Hu Y, Li J. Hyperthermia induces apoptosis of 786-O cells through suppressing Ku80 expression. *PLoS One*. 2015;10(4):e0122977.
 22. Ried M, Lehle K, Neu R. Assessment of cisplatin concentration and depth of penetration in human lung tissue after hyperthermic exposure. *Eur J Cardiothorac Surg*. 2015;47(3):563-6.
 23. Rusch VW, Niedzwiecki D, Tao Y. Intrapleural cisplatin and mitomycin for malignant mesothelioma following pleurectomy: Pharmacokinetic studies. *J Clin Oncol*. 1992;10(6):1001-6.
 24. Ried M, Potzger T, Braune N. Local and systemic exposure of cisplatin during hyperthermic intrathoracic chemotherapy perfusion after pleurectomy and decortication for treatment of pleural malignancies. *J Surg Oncol*. 2013;107(7):735-40.
 25. Markowiak T, Kerner N, Neu R. Adequate nephroprotection reduces renal complications after hyperthermic intrathoracic chemotherapy. *J Surg Oncol*. 2019;120(7):1220-6.
 26. Richards WG, Zellos L, Bueno R. Phase I to II study of pleurectomy/decortication and intraoperative intracavitary hyperthermic cisplatin lavage for mesothelioma. *J Clin Oncol*. 2006;24(10):1561-7.
 27. Klapper J, D'Amico TA. VATS versus open surgery for lung cancer resection: Moving toward a minimally invasive approach. *J Natl Compr Canc Netw*. 2015;13(2):162-4.