

Vol 5, Issue 4, Oct-Dec 2014

Indian Dermatology Online Journal

www.idoj.in



Publication of IADVL

Lichen striatus associated with psoriasis vulgaris treated with oral acitretin

Enzo Errichetti, Giuseppe Stinco, Giusto Trevisan¹, Pasquale Patrone

Departments of Experimental and Clinical Medicine, Institute of Dermatology, University of Udine, Udine, ¹Department of Dermatology, University of Trieste, Trieste, Italy

ABSTRACT

Lichen striatus (LS) is an uncommon dermatosis of unknown etiology that presents as a continuous or interrupted linear band of pink, tan, red or skin-colored papules in a blaschkoid distribution. The lesions are generally solitary and unilateral, but unusual extensive cases with multiple and bilateral lesions have been also described. Albeit LS is typically an asymptomatic and self-limited dermatosis, it may cause a significant psychological distress in some patients, thus requiring an appropriate therapy. Topical steroid is the most commonly used treatment but it is not always effective. We report a case of LS unresponsive to topical steroid therapy associated with psoriasis vulgaris successfully treated with oral acitretin.

Key words: Acitretin, lichen striatus, psoriasis, therapy, treatment

INTRODUCTION

Lichen striatus (LS) is an uncommon, asymptomatic, self-limiting dermatosis which lasts an average of nine months and usually occurs in children, although it is also rarely seen in adults. It often arises without a clear trigger, but some cases would appear to be related to several possible precipitating events such as infections and, more rarely, cutaneous injury, trauma, hypersensitivity, or other unspecified factors.^[1] LS typically presents as a continuous or interrupted linear band of pink, tan, red, or skin-colored papules that follow Blaschko's lines,^[1,2] which represent the pathways of cutaneous cell migration during embryonic development.^[3] The lesions are generally solitary and unilateral, but unusual cases with multiple and bilateral lesions have been rarely reported.^[1,2] Topical steroid is the most commonly used medication for the treatment of LS. However, this therapy is not always effective and its prolonged use may be associated with certain adverse effects including cutaneous atrophy.^[4] Other anecdotal therapies include oral corticosteroid, photodynamic therapy, topical calcineurin inhibitors, and oral acitretin.^[4,5]

We report a case of LS unresponsive to topical steroid therapy associated with psoriasis vulgaris, successfully treated with oral acitretin.

CASE REPORT

A 61-year-old woman was admitted for an asymptomatic linear skin eruption of the right lower limb that had started about four weeks earlier. During this period of time, the lesions had been treated with a topical corticosteroid (mometasone furoate cream 0.1% once a day) without any significant improvement. Skin examination revealed linearly arranged erythematous papules on and along the right lower limb following the line of Blaschko [Figure 1a]. Histopathologic examination of a papule revealed parakeratosis, acanthosis, piecemeal disappearance of the stratum granulosum, lymphocytic exocytosis, mild spongiosis, and a superficial and deep perivascular, lichenoid, perifollicular, and perieccrine infiltrate of lymphocytes and histiocytes [Figure 1b]. On the basis of the clinical and histological data, a diagnosis of LS was made. In addition to LS, she had chronic plaque psoriasis of 15 years duration mainly localized to the elbows and scalp that had progressively extended to her arms and trunk [Figure 2a] over the past three months. For this psoriatic exacerbation, the patient had been applying an ointment containing calcipotriol 50 µg/g and betamethasone dipropionate 0.5 mg/g (once a day) with only slight improvement. Since the woman had already used methotrexate and

Access this article online

Website: www.idoj.in

DOI: 10.4103/2229-5178.142521

Quick Response Code:



Address for

correspondence:

Prof. Giuseppe Stinco,
Institute of Dermatology,
University of Udine,
Ospedale "San Michele",
Piazza Rodolone,
1, 33013-Gemona del
Friuli (Udine), Italy.
E-mail: giuseppe.
stinco@uniud.it

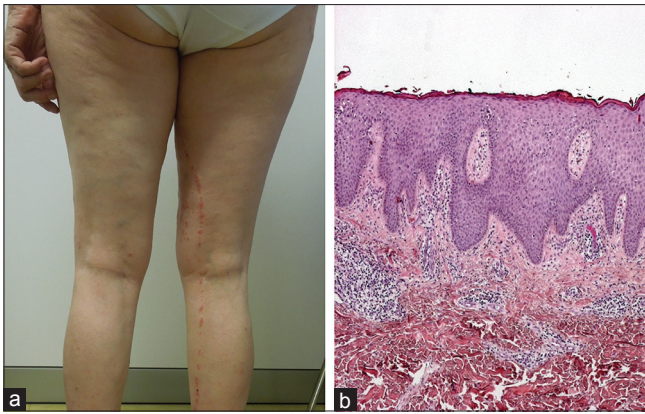


Figure 1: Linearly arranged erythematous papules on and along the right lower limb following the line of Blaschko (a) Parakeratosis, acanthosis, piecemeal disappearance of the stratum granulosum and spongiosis. Inflammatory chronic infiltrates are also observed in the epidermis and around the vessels and skin appendages in the superficial dermis (H and E, $\times 20$) (b)

cyclosporine in the past with poor tolerance, we decided to start oral acitretin (0.5 mg/kg/day). Interestingly, we found that LS regressed completely and rapidly after only four weeks [Figure 2b]. The patient continued therapy with acitretin at the same dosage for other two weeks; thereafter, the drug was tapered over the subsequent four weeks due to resolution of psoriatic lesions. No recurrence of LS and psoriasis was observed during the subsequent four-month follow-up period.

DISCUSSION

The association between LS and psoriasis is a rare event, since, to the best of our knowledge, there are only two well-documented published reports in the literature.^[6,7] The first case was a 2-year-old boy with a LS localized to his left half of the body who developed an unusual form of unilateral eruptive psoriasis limited to the right half of the body 2 weeks later. The authors stressed that a common, but unknown, triggering factor may have been involved.^[6] The second report described a 58-year-old man suffering from plaque psoriasis who developed LS at the third session of narrow-band ultraviolet B phototherapy instituted for a psoriatic exacerbation that had manifested 5 months earlier. In this case, the authors hypothesized that the association between two dermatoses was a mere coincidence.^[7] We believe that also in our case the association between the two dermatoses is casual, since a wide time gap between the appearance of each.

Although LS is an asymptomatic and self-limited dermatosis, it may cause a significant psychological distress in some patients, thus requiring an appropriate therapy. Several treatments have been reported with various degrees of success including oral and topical corticosteroid, photodynamic therapy, topical calcineurin inhibitors, and oral acitretin.^[4,5] Regarding this last therapy, there is only one report describing an extensive case

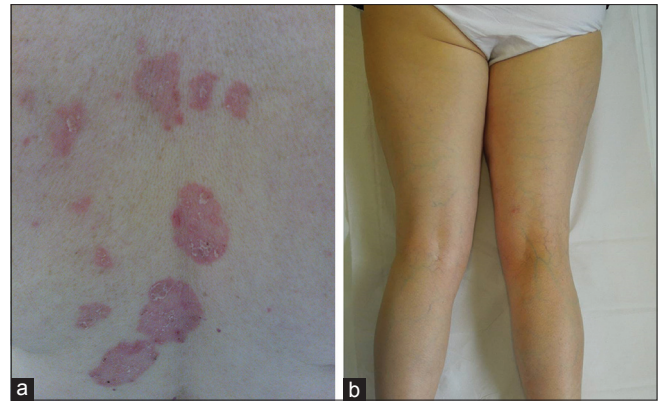

Figure 2: Several psoriatic plaques of the back (a) Complete regression of lichen striatus after 4 weeks of oral acitretin therapy (b)

of LS markedly improved over the course of a few weeks with an attack dose of 0.6 mg/kg/die.^[5]

In our case of LS, the patient was found to be resistant to topical steroid treatment while she had a complete and rapid response to oral acitretin. The exact mechanism of action of this drug in LS is unclear.

LS has been considered to be the consequence of an acquired stimulus that induces a loss of immune tolerance to embryologically abnormal clones, resulting in a T-cell-mediated inflammatory reaction,^[1,2] which causing the typical Blaschko linear lesions histopathologically characterized by lichenoid, lymphocytic infiltrate with overlying epidermal acanthosis, dyskeratosis, hyperkeratosis, occasional parakeratosis, and lymphocytic exocytosis.^[1,8]

Therefore, it can be assumed that therapeutic efficacy of acitretin is attributable to its effect on cutaneous immunomodulation as well as epithelial cell proliferation and differentiation.^[9]

In conclusion, the clinical improvements observed in this report tend to further support the efficacy of oral acitretin in the treatment of LS and suggest its use not only in extensive and unaesthetic forms but also in cases unresponsive to steroid therapy. Further studies and reports are however needed in order to confirm these findings.

REFERENCES

1. Patrizi A, Neri I, Fiorentini C, Bonci A, Ricci G. Lichen striatus: Clinical and laboratory features of 115 children. *Pediatr Dermatol* 2004;21:197-204.
2. Hauber K, Rose C, Bröcker EB, Hamm H. Lichen striatus: Clinical features and follow-up in 12 patients. *Eur J Dermatol* 2000;10:536-9.
3. Taieb A, el Youbi A, Grosshans E, Maleville J. Lichen striatus: A Blaschko linear acquired inflammatory skin eruption. *J Am Acad Dermatol* 1991;25:637-42.
4. Park JY, Kim YC. Lichen striatus successfully treated with photodynamic therapy. *Clin Exp Dermatol* 2012;37:570-2.

5. Reiter H, Feldmann R, Breier F, Happle R, Gschnait F. Lichen striatus or Blaschkitis in the adults. Variations of the same entity? *Hautarzt* 2000;51:770-3.
6. Menni S, Grimalt R, Caputo R. Unilateral eruptive psoriasis and lichen striatus. *Pediatr Dermatol* 1991;8:322-4.
7. Gökdemir G, Sakiz D, Göksu F, Kivanç-Altunay I. Lichen striatus associated with chronic plaque psoriasis in an adult. *J Eur Acad Dermatol Venereol* 2003;17:617-9.
8. Patrone P, Patrizi A, Bonci A, Passarini B. Lichen striatus: A clinical and histological study of 8 cases. *G Ital Dermatol Venereol* 1990;125:267-70.
9. Menter A, Korman NJ, Elmetts CA, Feldman SR, Gelfand JM, Gordon KB, *et al.* Guidelines of care for the management of psoriasis and psoriatic arthritis: Section 4. Guidelines of care for the management and treatment of psoriasis with traditional systemic agents. *J Am Acad Dermatol* 2009;61:451-85.

Cite this article as: Errichetti E, Stinco G, Trevisan G, Patrone P. Lichen striatus associated with psoriasis vulgaris treated with oral acitretin. *Indian Dermatol Online J* 2014;5:501-3.

Source of Support: Nil, **Conflict of Interest:** None declared.