



**Peer Reviewed**

**Title:**

Sporotrichoid Mycobacterium marinum infection in an elderly woman

**Journal Issue:**

[Dermatology Online Journal, 21\(5\)](#)

**Author:**

[di Meo, Nicola](#), University of Trieste, Italy  
[Stinco, Giuseppe](#), University of Udine, Italy  
[Trevisini, Sara](#), University of Trieste, Italy  
[De Marchi, Sergio](#), University of Trieste, Italy  
[Albano, Antonio](#), University of Trieste, Italy  
[Trevisan, Giusto](#), University of Trieste, Italy

**Publication Date:**

2015

**Permalink:**

<http://escholarship.org/uc/item/0sj418qp>

**Local Identifier:**

doj\_27528

**Abstract:**

We describe the case of an elderly woman who acquired a Mycobacterium marinum infection following skin exposure to the bacteria through a small wound on her right ring finger, obtained while preparing fish. The resultant sporotrichoid nodules of the right hand and the distal forearm, refractory to the initial therapy with doxycycline and rifampicin, were successfully treated with oral regimen of clarithromycin.

**Copyright Information:**



Copyright 2015 by the article author(s). This work is made available under the terms of the Creative Commons Attribution-NonCommercial-NoDerivs4.0 license, <http://creativecommons.org/licenses/by-nc-nd/4.0/>



Photo vignette

Sporotrichoid *Mycobacterium marinum* infection in an elderly woman

Nicola di Meo<sup>1</sup>, Giuseppe Stinco<sup>2</sup>, Sara Trevisini<sup>1</sup>, Sergio De Marchi<sup>1</sup>, Antonio Albano<sup>1</sup>, Giusto Trevisan<sup>1</sup>

Dermatology Online Journal 21 (5): 11

<sup>1</sup>Department of Dermatology and Venereology, University of Trieste, Italy

<sup>2</sup>Department of Experimental and Clinical Medicine, Institute of Dermatology, University of Udine, Italy

Correspondence:

Nicola di Meo  
University of Trieste  
nickdimeo@libero.it

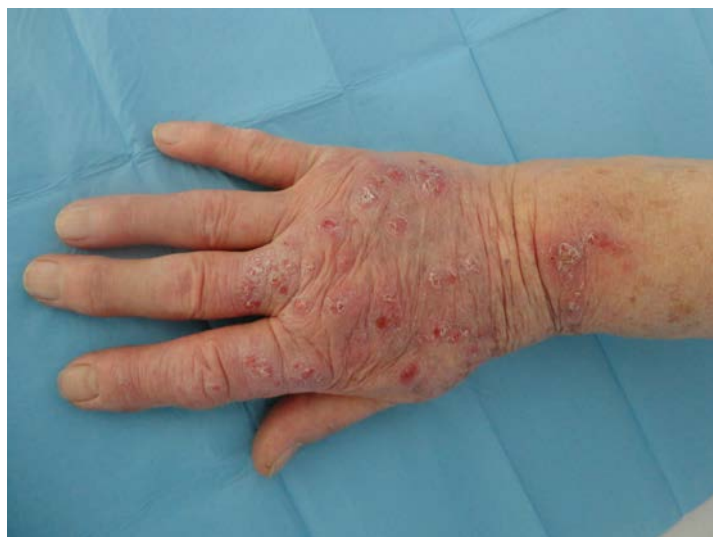---

**Abstract**

We describe the case of an elderly woman who acquired a *Mycobacterium marinum* infection following skin exposure to the bacteria through a small wound on her right ring finger, obtained while preparing fish. The resultant sporotrichoid nodules of the right hand and the distal forearm, refractory to the initial therapy with doxycycline and rifampicin, were successfully treated with oral regimen of clarithromycin.

**Case synopsis**

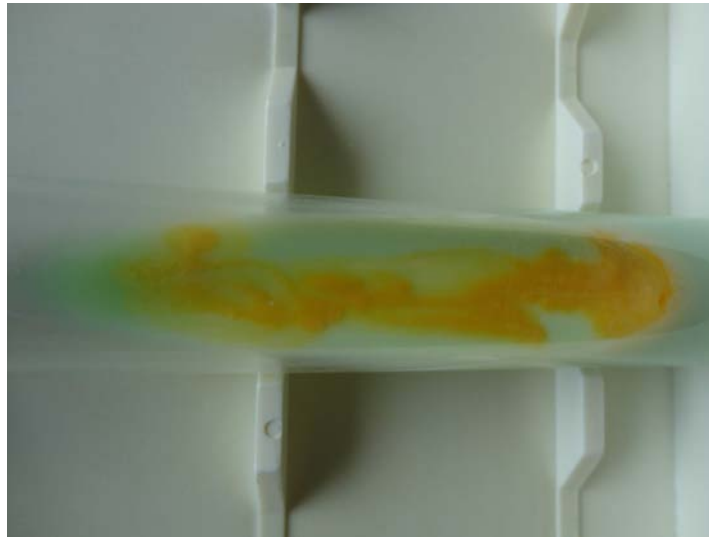
An otherwise healthy 85-year-old woman presented with a 2-month history of deep erythema, subcutaneous nodules, and a painful and swollen right upper limb. Upon physical examination, the patient had erythema and edema with nodules, some of them ulcerated, and crusts all over her right hand and distal forearm (Figure 1). There was no lymphadenopathy and the patient denied fever, arthralgia, or any systemic symptoms. She recalled that she had wounded her second finger of the right hand while she was preparing fish and that the initial nodule had appeared near the initial trauma site after 2-3 weeks. The disease had progressed and other nodules appeared in a sporotrichoid pattern following lymphatic drainage. Before our visit, the patient had already been treated with empiric antibiotics such as amoxicillin for two weeks and ciprofloxacin for another two weeks without



**Figure 1.** Clinical aspects. Erythema and edema with nodules, some of them ulcerated, and crusts all over the hand

experiencing any clinical improvement. Biochemical and hematological findings were normal. Blood cultures, Quantiferon and human immunodeficiency virus antibody tests were negative. Chest x-rays showed no lung or pleural lesions. Three skin biopsies were performed from healthy skin surrounding the nodules and from the nodules themselves. Histological exam demonstrated a neutrophilic and histiocytic granuloma with no caseous necrosis with multinucleated giant cell infiltration (Figure 2). In routine cultures all special stains, including PAS, were negative for bacterial or fungal infection. A Lowenstein Jensen culture was performed at a temperature between 28 °C and 32 °C. Cutaneous *M. marinum* infection was suspected; while awaiting culture results, the patient was

empirically treated with doxycycline (200mg per day) and rifampicin (450mg once a day). After 4 weeks there was no regression of lesions and the culture was still negative, but this therapy was continued.



**Figure 2.** The culture from the biopsy specimen grew out a strain of *Mm*, identified through *Mm* PCR technique (hsp60 and 16s RNA)

Proof of the diagnosis was obtained two weeks later when the culture from the biopsy specimen showed a strain of *Mm*, identified through PCR-technique (hsp60 and 16s RNA) (Figure 3). The organism was sensitive to clarithromycin and amikacin and resistant to doxycycline, minocycline, and rifampicin. Doxycycline and rifampicin were discontinued and combination therapy with oral clarithromycin (500mg twice a day) and topical amikacin (gel 5%, once a day) was started. After 4 weeks of therapy the skin lesions completely disappeared. However, we continued antibiotics for 2 months after the lesions had healed to prevent recurrence. There was no recurrence when examined after 12 months of follow up.

## Discussion

*Mycobacterium marinum* (*Mm*) is a slow-growing atypical mycobacteria that is found in fresh or saltwater in many parts of the world. It typically infects fish, but can also affect frogs, eels, and oysters. In humans *Mm* infection is rare and occurs most commonly in individuals with occupational and recreational exposure to fresh or salt water as a result of skin contact with the bacteria through a small cut or skin scrape [1]. *Mm* infection primarily is localized in the skin at the inoculation site. It commonly appears 2-3 weeks after exposure as a solitary papulo-nodule, a granulomatous nodule with central ulceration, a verrucous plaque with central clearing, or sporotrichoid lesions on areas exposed to trauma [2,3]. The infection is often unrecognized and the frequently delayed diagnosis may be caused by the indolent nature of early lesions, incomplete history of exposure to fresh or salt water, atypical manifestations related to partial therapy, negative results of inappropriate cultures, and low awareness of atypical mycobacterial skin infection among clinicians [1,4]. As in all mycobacterial disease of the skin, the diagnosis requires a high index of suspicion. A careful history and the presence of tuberculoid granulomata in histopathology specimens are suggestive [4]. Proof of the diagnosis can only be obtained by the demonstration of *Mm* in culture from a biopsy specimen. Tetracycline, minocycline, doxycycline, rifampicin, trimethoprim-sulfamethoxazole, ethambutol, and clarithromycin have been used for the treatment of *Mm* infection but there is still no consensus protocol for the optimal choice of antimicrobial agents and treatment duration [1,5].

People at highest risk include home-aquarium hobbyists, aquarium workers, marine biologists, fishermen, and oyster workers. For this reason, the infection is not usually contracted by elderly people [6,7]. Our patient did not belong to any of these at risk categories but she acquired the infection as a result of skin contact with the bacteria through a wound that she obtained while preparing fish. Another interesting point in this case report is that the lesions, refractory to initial therapy with doxycycline and rifampicin, were successfully treated with a regimen of oral clarithromycin combined with topical amikacin to prevent superinfection. There is no proven treatment of choice because *Mm* is naturally multi-drug resistant and treatment is based primarily on personal experience and preference without the benefit of large studies. Widely used antibacterials include tetracyclines (mostly minocycline and doxycycline), trimethoprim-sulfamethoxazole, rifampicin, ethambutol, and clarithromycin. In cases of severe infections, including those with a sporotrichoid distribution pattern, a combination of antibiotics seems to be the recommended regimen [4]. Clarithromycin is bactericidal against *Mm*. The combination of ethambutol (15mg per kg body weight daily) and clarythomycin (500mg twice a day), which has synergistic activities in vitro, has been recommended for the treatment of persistent lesions [5]. Ethambutol is considered one of the first-line supplemental agents in the treatment of tuberculosis. Although this drug is infrequently toxic, several cases of retrobulbar optic neuritis have been described. Therefore patients should be tested monthly (and whenever there is a subjective visual change) for visual acuity and red-green color discrimination. In a recent nationwide population-based study, Chen et al. [8] reported that aging patients have increased risk of ethanol-induced optic neuropathy. Therefore we decided to introduce a single regimen with clarithromycin, which has been safe and effective for our elderly patient.

## References

1. Kahn FA, Khakoo R: Non tuberculous mycobacterial cutaneous infections: an updated review. *Cutis* 2011;88:194-200. PMID: 22106729
2. Cheung JPY, Fung B, Ip WY, Chow SP. Mycobacterium marinum infection of the hand and wrist. *Journal of Orthopaedic Surgery* 2012;20: 214-8. PMID: 22933682
3. El Amrani MH, Adoui M, Patey O, Asselineau A. Upper extremity Mycobacterium marinum infection. *Orthopaedics and Traumatology: Surgery and Research* 2010; 96: 706-711. PMID: 20813602
4. Weitzul S, Eichhorn PJ, Pandya AG. Nontuberculous mycobacterial infections. *Dermatol Clin* 2000;18:359-377. PMID: 10791163
5. Jogi R, Tyring SK. Therapy of nontuberculous mycobacterial infections. *Dermatol Ther.* 2004;17:491-498. PMID: 15571497
6. Petrini B. Mycobacterium marinum: ubiquitous agent of waterborne granulomatous skin infections. *Eur J Clin Microbiol Infect Dis.* 2006; 25: 609-13. PMID: 17047903
7. Bonamonte D, De Vito D, Vestita M, Delvecchio S, Ranieri LD, Santantonio M, Angelini G. Aquarium-borne Mycobacterium marinum skin infection. Report of 15 cases and review of the literature. *Eur J Dermatol.* 2013; 23:510-6. PMID: 24002023
8. Chen HY, Lai SW, Mou CH, Chen PC and Wang IJ. Ethambutol-induced optic neuropathy: a nationwide population-based study from Taiwan. *Br J Ophthalmol* 2012;96:1368-1371. PMID: 22960095