



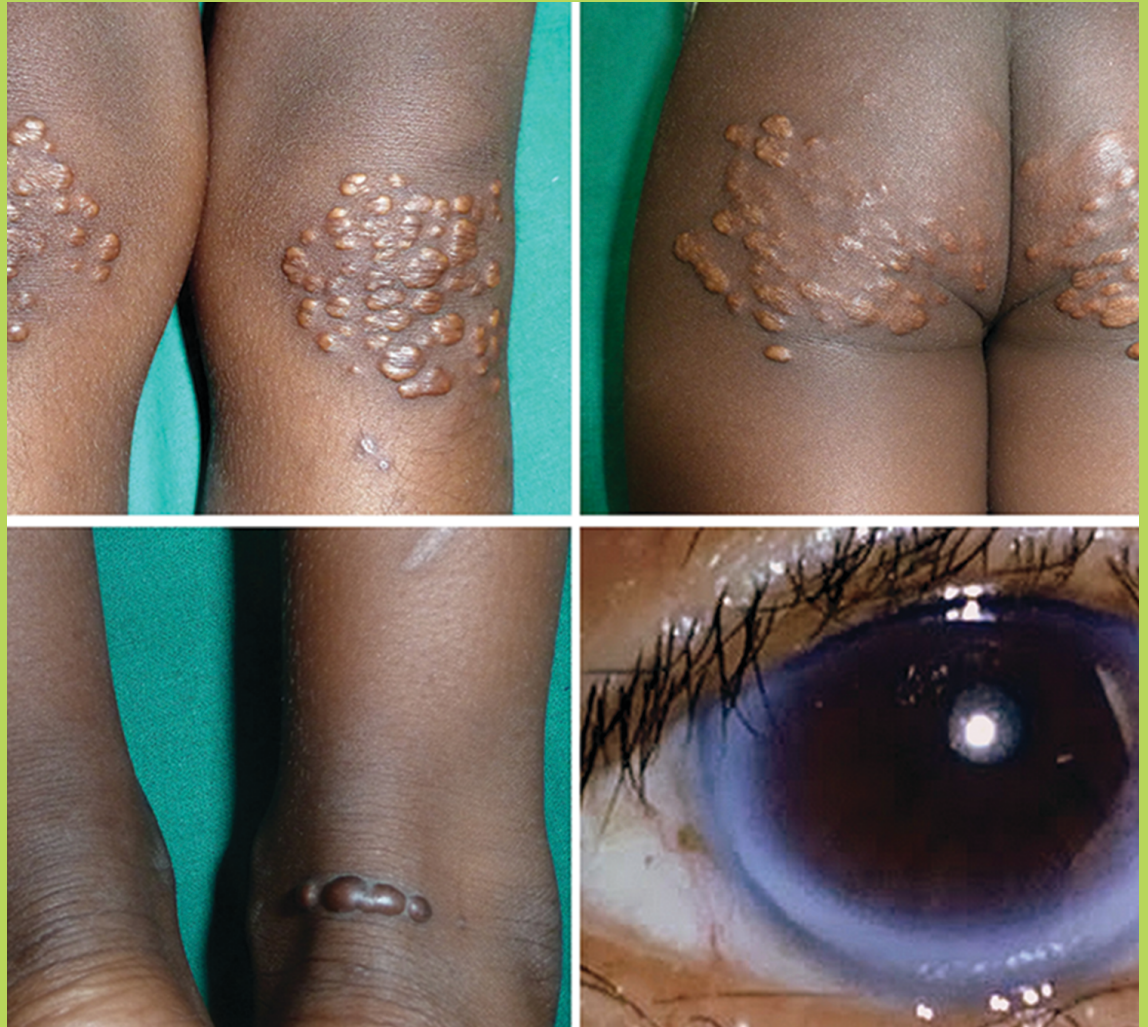
IJDVL
An IADVL Publication

Indian Journal of Dermatology, Venereology & Leprology

Volume 80

Issue 4

July-August
2014



In the Issue...

- A new occlusive patch test system comparable to IQ and Finn chambers
- Factors affecting the duration of phase I of dexamethasone – cyclophosphamide pulse therapy
- Intermediate doses of rituximab used as adjuvant therapy in refractory pemphigus
- Clinical features of primary cicatricial alopecia in Chinese patients
- Comparison of acquired bilateral nevus of Ota-like macules in men and women
- Lyme disease in Haryana, India
- *Trichosporon inkin* and *Trichosporon mucoides* as unusual causes of white piedra of scalp hair

www.ijdvl.com

ISSN 0378-6323



Wolters Kluwer
Health

Medknow

Electrochemotherapy for a locally advanced basal cell carcinoma on the forehead

Sir,

Electrochemotherapy (ECT) is an effective loco-regional therapy for solid skin cancers with a high overall objective response rate and good cosmetic results. It is used for the treatment of cutaneous and subcutaneous tumour nodules where standard treatments have failed or proved to be inappropriate. It is mainly indicated in melanoma, Kaposi sarcoma, and cutaneous or subcutaneous metastases. Recent studies have focused on its role in the treatment of cutaneous tumours, in particular basal cell carcinoma (BCC) and squamous cell carcinoma of the head and neck.^[1,2]

This therapeutic modality is based on the combination of electroporation and the administration of cytotoxic low permeability drugs. Electroporation uses pulsed, high-intensity electric fields to temporarily increase cell membrane permeability by creation of pores, thereby allowing non-permeable chemotherapeutic agents to enter the cells. These electric pulses also increase the cytotoxicity of the drugs. Bleomycin and cisplatin are the two commonly used drugs in this method.^[3] The clinical procedures for a standardized, efficient and safe electric pulse and drug administration protocol for electrochemotherapy are provided by the results of a multicenter European Standard Operating Procedure of Electrochemotherapy (ESOPE).^[4] We report our experience in a case of basal cell carcinoma.

A 54-year-old man presented with a pigmented and deep infiltrating plaque localized over the forehead. The lesion represented a relapsed basal cell carcinoma confirmed by histopathology [Figure 1a and b]. He was operated with Moh's surgical technique one year earlier, but the lesion relapsed at the same site [Figure 2a]. We offered electrochemotherapy as a treatment option as he refused surgical intervention. A bolus of bleomycin and an electrical pulse generator was used under general anesthesia following the ESOPE guidelines. Bleomycin was administered intravenously in a dosage of 30000 IU followed by the application of electric pulses directly over the tumour. We used a linear field of 20 mm and the median time of treatment was 30 minutes. The procedure was

well tolerated and led to a rapid clinical regression of the lesion. At one year of follow up, mild scarring with hyperpigmentation was seen over the treated site [Figure 2b]. There was no evidence of relapse on histopathological and dermoscopic examination.

Basal cell carcinoma is the most common cutaneous malignant neoplasm, accounting for up to 80% of non melanoma skin cancers and has an estimated annual incidence of 0.1 to 0.5% in the United States. Surgery is the standard treatment but in some cases there could be a progression or relapse of the disease. Treatment must be individualized according to the patient and depends upon the location, size, tumour sub-type, patient preferences and on the cost effectiveness of therapy. Due to the location, there was a risk of facial nerve damage during surgery. Biological therapies such as epidermal growth factor receptor or Hedgehog inhibitor are costly^[5]. Electrochemotherapy is a low risk therapeutic option with good clinical and aesthetic results. Its use in locally advanced basal cell carcinoma has not been standardized yet. It has been reported that electrochemotherapy with bleomycin sulphate gave the best response rates in basal cell carcinoma among a variety of primary and secondary skin tumours with a complete response in up to 94.4% of cases after one treatment session.^[5]

Potential contraindications to this technique include poor renal function, arrhythmia, pacemaker use and pulmonary fibrosis. A number of studies have shown that electrochemotherapy is associated with a good overall response rate. Gargiulo *et al.*,^[2] reported no recurrences during a mean follow-up of 20 months in a non-randomised study of 34 patients including 20 patients with BCC, and improved local tumour control with repeated electrochemotherapy. The only side effects reported are mild and transient erythema and oedema which resolve within 24 hours. In peculiar locations such as the orbit or eye muscles, electrochemotherapy does not cause significant dysfunctional outcome. A septal cartilage perforation was reported in 1 patient receiving treatment in the right nasal vestibule.^[2]

Therapeutic response occurs without any increased morbidity for the patient with tissue-sparing and low risk due to the minimal dose of chemotherapy, local anaesthesia, absence of surgical wounds, good aesthetic results, brief hospitalization and high compliance of the patient. Furthermore, the absence of systemic side effects and low immunosuppression even with repeated doses make this a suitable technique for elderly

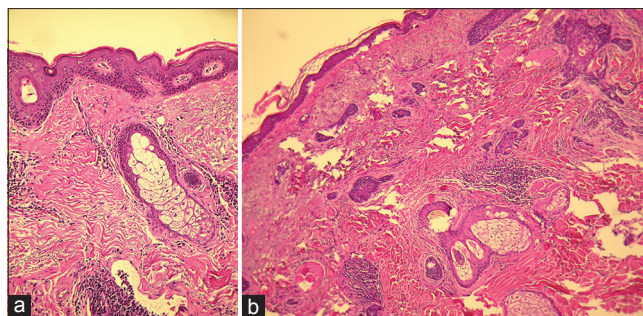


Figure 1: (a) Basal cell carcinoma (H and E, x40). (b) Infiltrative growth of basal cell carcinoma (H and E, x40)

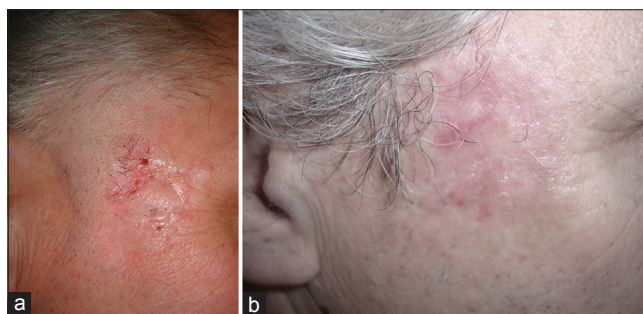


Figure 2: (a) A deep, infiltrating plaque localized over the forehead. (b) Post-electrochemotherapy, at one year follow up, with mild scarring and hyperpigmentation

patients with poor general condition or co-morbidities. In conclusion, this technique appears to be well tolerated, safe and repeatable. In our case, this approach gave very satisfying results with no recurrence and a good aesthetic outcome at follow up one year later. Our experience, along with that of others, demonstrates that electrochemotherapy with intravenous or intra-tumour bleomycin is an effective treatment option for patients with advanced basal cell carcinoma.

**Alessandro Gatti, Giuseppe Stinco¹,
Nicola di Meo, Cecilia Noal, Vincezo Maione¹,
Giusto Trevisan**

Department of Dermatology and Venereology, University of Trieste,
¹Department of Experimental and Clinical Medicine, DISM,
Institute of Dermatology, University of Udine, Italy

Address for correspondence: Dr. Nicola di Meo,
Department of Dermatology, Maggiore Hospital of Trieste,
IV Floor Palazzina Infettivi, University of Trieste,
Trieste, Italia - 34151.
E-mail: nickdimeo@libero.it

REFERENCES

1. Mevio N, Bertino G, Occhini A, Scelsi D, Tagliabue M, Mura F, *et al.* Electrochemotherapy for the treatment of recurrent head and neck cancers: Preliminary results. *Tumori* 2012;98:308-13.
2. Gargiulo M, Papa A, Capasso P, Moio M, Cubicciotti E, Parascandolo S. Electrochemotherapy for non-melanoma head

and neck cancers: Clinical outcomes in 25 patients. *Ann Surg* 2012;255:1158-64.

3. Reinhold U. Electrochemotherapy for primary skin cancer and skin metastasis related to other malignancies. *Anticancer Drugs* 2011;22:711-8.
4. Testori A, Tosti G, Martinoli C, Spadola G, Cataldo F, Verrecchia F, *et al.* Electrochemotherapy for cutaneous and subcutaneous tumor lesions: A novel therapeutic approach. *Dermatol Ther* 2010;23:651-61.
5. Ali FR, Lear JT. Systemic treatments for basal cell carcinoma (BCC): The advent of dermato-oncology in BCC. *Br J Dermatol* 2013;169:53-7.

Access this article online	
Quick Response Code:	Website: www.ijdvl.com
	DOI: 10.4103/0378-6323.136989

New features on the journal's website

Optimized content for mobile and hand-held devices

HTML pages have been optimized of mobile and other hand-held devices (such as iPad, Kindle, iPod) for faster browsing speed.

Click on **[Mobile Full text]** from Table of Contents page.

This is simple HTML version for faster download on mobiles (if viewed on desktop, it will be automatically redirected to full HTML version)

E-Pub for hand-held devices

EPUB is an open e-book standard recommended by The International Digital Publishing Forum which is designed for reflowable content i.e. the text display can be optimized for a particular display device.


Click on **[EPub]** from Table of Contents page.

There are various e-Pub readers such as for Windows: Digital Editions, OS X: Calibre/Bookworm, iPhone/iPod Touch/iPad: Stanza, and Linux: Calibre/Bookworm.

E-Book for desktop

One can also see the entire issue as printed here in a 'flip book' version on desktops.

Links are available from Current Issue as well as Archives pages.

Click on  View as eBook