



Management of vertebral osteomyelitis over an eight-year period: The UDIPROVE (UDIne PROtocol on VERtebral osteomyelitis)



Alessandro Russo^a, Elena Graziano^a, Alessia Carnelutti^a, Massimo Sponza^b, Barbara Cadeo^a, Assunta Sartor^c, Elda Righi^d, Matteo Bassetti^{e,*}

^a Infectious Diseases Clinic, Department of Medicine, University of Udine and Azienda Sanitaria Universitaria Integrata di Udine, Udine, Italy

^b Division of Vascular and Interventional Radiology, University of Udine and Azienda Sanitaria Universitaria Integrata di Udine, Udine, Italy

^c Microbiology Unit, Azienda Sanitaria Universitaria Integrata di Udine, Udine, Italy

^d Infectious Diseases, Department of Diagnostics and Public Health, University of Verona, Verona, Italy

^e Infectious Diseases Clinic, Department of Health Sciences, University of Genoa, Genoa and Hospital Policlinico San Martino - IRCCS, Genoa, Italy

ARTICLE INFO

Article history:

Received 13 August 2019

Received in revised form 7 October 2019

Accepted 11 October 2019

Corresponding Editor: Eskild Petersen, Aarhus, Denmark

Keywords:

Vertebral osteomyelitis

Vertebral biopsy

C-reactive protein

FDG-PET/CT

MRI

ABSTRACT

Objectives: Vertebral osteomyelitis (VO) is a compelling clinical entity for clinicians because of its insidious and indolent course, which makes diagnosis difficult.

Methods: All patients with a suspected diagnosis of VO were analyzed over an 8-year period (January 2009 to January 2017). The UDIPROVE protocol (UDIne PROtocol on VERtebral osteomyelitis) was applied in all cases. The primary endpoint was the performance of the UDIPROVE protocol to obtain the causal bacteria of infection.

Results: During the study period, 133 episodes of confirmed VO were observed. The etiology of infection was obtained in 73.6% of cases: 70.5% were gram-positive, 16.3% were gram-negative, and 13.2% were mycobacteria. ¹⁸F-Fluorodeoxyglucose positron emission tomography/computed tomography (FDG-PET/CT) showed that for tubercular VO, the median standard uptake value (SUV) was higher when compared with VO caused by other bacteria. Clinical cure at the end of therapy was reported in 85.7% of patients. Previous antimicrobial therapy and a delay of more than 5 days in performing biopsy were associated with an undiagnosed etiology of VO. Targeted antibacterial therapy and follow-up with FDG-PET/CT were associated with clinical cure at the end of therapy, while the involvement of more than two vertebrae and inadequate drainage were associated with failure.

Conclusions: Rigorous application of the UDIPROVE protocol allowed the causative pathogens of VO to be obtained – at about twice the rate reported in the literature. The use of FDG-PET/CT for the follow-up of infection was more reliable when compared to magnetic resonance imaging (MRI).

© 2019 The Authors. Published by Elsevier Ltd on behalf of International Society for Infectious Diseases. This is an open access article under the CC BY-NC-ND license (<http://creativecommons.org/licenses/by-nc-nd/4.0/>).

Introduction

Vertebral osteomyelitis (VO) is a compelling clinical entity for clinicians because of its insidious and indolent course, which makes diagnosis difficult. The diagnosis of VO can often be delayed by several months and the disease may initially be misdiagnosed and mismanaged as a degenerative process. Consequently, patients often develop destructive lesions or neurological complications. In this setting, an elevated C-reactive protein (CRP) level in patients

with back pain, although not specific, has a sensitivity that can range from 94% to 100% (Zimmerli, 2010; Gupta et al., 2014).

Overall, the etiology of infection in VO is obtained in less than 40% of cases, making the choice of antimicrobial regimen and duration of therapy challenging (Chew and Kline, 2001). With the exception of septic patients and patients with neurological compromise, empiric antimicrobial therapy should be withheld whenever possible until a microbiological diagnosis is confirmed. An image-guided aspiration biopsy is recommended for patients with suspected VO when a microbiological diagnosis has not been established by blood cultures (BC) or serological tests; however, the rate of diagnosis with an image-guided biopsy, as reported in the literature, is about 30–40% (Berbari et al., 2015).

No indications for follow-up with magnetic resonance imaging (MRI) in patients with VO who have a favorable clinical and

* Corresponding author at: Infectious Diseases Clinic, Department of Health Sciences, University of Genoa, Genoa and Hospital Policlinico San Martino - IRCCS, Genoa, Italy.

E-mail address: Matteo.Bassetti@hsanmartino.it (M. Bassetti).

laboratory response to antimicrobial therapy are recommended in the international guidelines (Berbari et al., 2015), considering the limits of the method. Thus, the role of positron emission tomography (PET) has been assessed over recent years, considering its high sensitivity for detecting osteomyelitis. A negative PET scan excludes the diagnosis of osteomyelitis, including VO (Ohtori et al., 2010; Hungenbach et al., 2013).

The aim of this study was to investigate the rigorous application of the UDIPROVE protocol (UDine PROtocol on VERtebral osteomyelitis) to obtain the causative pathogens of VO with vertebral biopsy, and the role of ^{18}F -fluorodeoxyglucose PET/computed tomography (FDG-PET/CT) in the diagnosis and follow-up of infection and comparison with MRI.

Materials and methods

Study design

This was a prospective observational study conducted in a large tertiary level hospital in Italy over an 8-year period (January 2009 to January 2017). During the study period, all consecutive adult patients (age ≥ 18 years) with a suspected diagnosis of VO were analyzed. The UDIPROVE protocol was applied in all cases, as reported in Figure 1. The study was preapproved by the local ethics committee and was conducted in accordance with the principles of the Declaration of Helsinki.

Data collection and definitions

Patient data were collected prospectively from the medical records, computerized hospital databases, and/or clinical charts using a standard form. These included demographic characteristics, clinical and laboratory findings, baseline comorbidities, radiological findings, relapse of infection, microbiological data, the Charlson Comorbidity Index, date and type of surgery (if performed), source of infection, persistent bacteremia, development of septic shock, duration of hospital stay, duration of definitive antibiotic therapy, clinical treatment failure, and 30-day mortality.

At the time of diagnosis, the patients underwent MRI and/or FDG-PET/CT (first visit). All patients who underwent FDG-PET/CT were on a low carbohydrate-fat allowed diet for 24 h before the FDG-PET/CT was performed; they fasted for the 6 h prior to ^{18}F -FDG injection, according to the local protocol.

The following definitions were established prior to data analysis: ‘relapse’ was defined as a new diagnosis of VO caused by the same organism after clinical and microbiological resolution of a previously treated episode of VO; ‘time to biopsy’ was defined as the number of days that elapsed between the diagnosis of VO and the vertebral biopsy (when performed); ‘persistent infection’ was defined in the case of a patient still being treated for VO at the 3-month follow-up, without resolution of the described symptoms; ‘clinical treatment failure’ was defined as a lack of response to the definitive antimicrobial regimen, as reflected by the presence of any of the following after ≥ 45 days of therapy: ongoing fever, leukocytosis, or other clinical signs of infection that could not be attributed to causes other than VO; ‘30-day mortality’ was defined as death from any cause within the 30 days following the diagnosis of VO.

Synchronous or metastatic foci of infection were identified by means of clinical and imaging examinations. When present, fluid collections and abscesses were drained and the fluid cultured. Coagulase-negative staphylococci (CoNS) and other skin commensals were considered etiologically irrelevant unless they were isolated from two or more sets of BC and their causative role was consistent with clinical data. Adequate control of the source of infection was defined as the removal of any preexisting contaminated central venous catheter, as well as the drainage of vertebral abscesses or other fluid collections, with these being performed within 24 h after the onset of infection. Patients who were diagnosed with VO based on at least one imaging study and/or blood or tissue culture results were treated according to the Infectious Diseases Society of America (IDSA) guidelines for vertebral osteomyelitis (Berbari et al., 2015). Three months after inclusion (second visit), all surviving patients underwent MRI and/or FDG-PET/CT.

Endpoints and statistical analysis

The primary endpoint was the performance of the UDIPROVE protocol to obtain the causal bacteria of infection. Secondary endpoints were the role of FDG-PET/CT in diagnosis and follow-up and the analysis of clinical cure at the end of therapy.

Between-group differences were assessed with the Chi-square test or Fisher’s exact test (for categorical variables) and the two-tailed *t*-test or Mann–Whitney test (for continuous variables), as appropriate. Univariate and multivariate analyses were used to

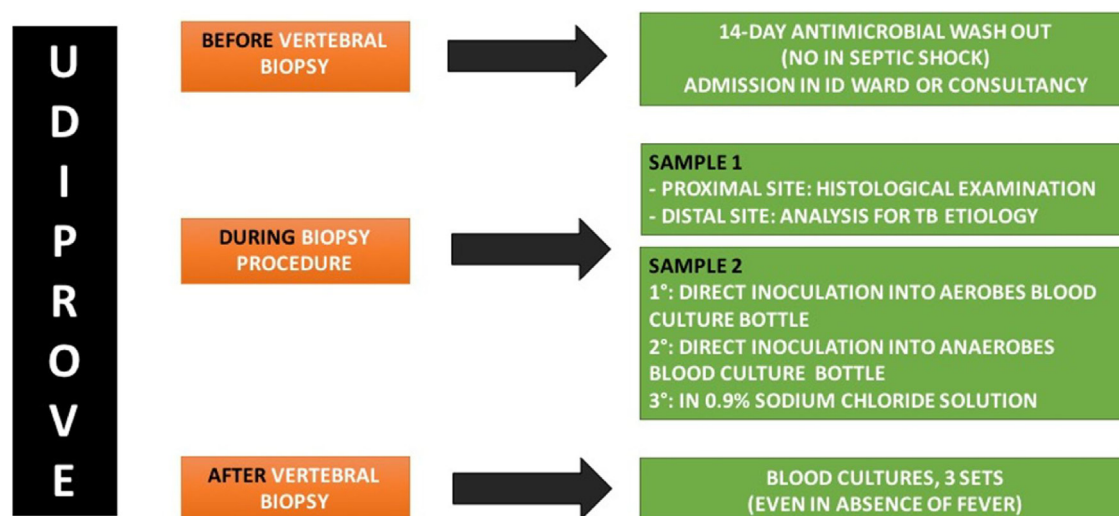


Figure 1. The UDIPROVE algorithm.

ID: infectious diseases; TB: tuberculosis.

Table 1
Etiology of vertebral osteomyelitis.

Etiology	N = 98 (%)
Gram-positive	69 (70.5)
MRSA	19 (19.4)
MSSA	5 (5.1)
CoNS	13 (13.3)
<i>Streptococcus</i> spp	24 (24.4)
<i>Enterococcus</i> spp	4 (4.1)
Others	4 (4.1)
Gram-negative	16 (16.3)
<i>Escherichia coli</i>	8 (8.1)
<i>Klebsiella pneumoniae</i>	4 (4.1)
Others	4 (4.1)
<i>Mycobacterium tuberculosis</i>	13 (13.3)

MRSA, methicillin-resistant *Staphylococcus aureus*; MSSA, methicillin-sensitive *Staphylococcus aureus*; CoNS, coagulase-negative staphylococci.

determine the effects of different variables on an undiagnosed etiology of VO, clinical treatment failure, and clinical success in the study population. Possible confounding factors and interactions were weighted during analyses with a backward stepwise selection and considering $p \leq 0.05$ for all variables, to determine the effects of all anamnestic, clinical, and therapeutic variables on the outcomes. All reported p -values are two-tailed. Wald confidence intervals (CI) and odd ratios (OR) were computed based on estimated standard errors. All analyses were done using IBM SPSS Statistics version 20.0 (IBM Corp., Armonk, NY, USA).

Results

During the study period, 133 episodes of confirmed VO were observed. As reported in Table 1, the etiology of infection was obtained in 98 cases (73.6%) (BC+vertebral biopsy/drainage) according to the UDIPROVE algorithm (Figure 1). The most frequently isolated bacteria were gram-positive (70.5%), followed by gram-negative (16.3%) and mycobacteria (13.2%). Among the gram-positive bacteria, *Streptococcus* spp accounted for 24.4% of cases, followed by methicillin-resistant *Staphylococcus aureus* (MRSA) (19.4%). Biopsy results with or without antimicrobial washout are reported in Figure 2.

The mean standard uptake value (SUV), CRP, and white blood cell count (WBC) values at the time of diagnosis (first visit) and at follow-up (second visit) are reported in Figure 3. Statistically

significant differences were observed for SUV ($p < 0.001$) and CRP ($p < 0.001$) values.

Finally, the SUV values in subgroups of patients with VO at follow-up (second visit) are reported in Figure 4: patients with or without a tubercular etiology, the presence or absence of endocarditis, *Staphylococcus aureus* etiology or others, and two or more than two vertebrae involved in infection. Statistically significant differences in SUV values were observed for tubercular etiology or not ($p < 0.001$) at follow-up.

Table 2 reports the baseline characteristics and outcomes of the study population along with the univariate analysis of risk factors for clinical success or failure. Vertebral biopsy/drainage was performed in 101 patients (75.9%), and 14-day antimicrobial treatment discontinuation before vertebral biopsy was obtained in 98 patients (73.7%). Concomitant endocarditis was observed in 18 cases (13.5%). The mean SUV value was 7.2 ± 3.3 , and diagnosis and follow-up with FDG-PET/CT was performed in 59 patients (44.3%). All patients underwent MRI at the time of diagnosis and at follow-up. Clinical cure at the end of therapy was reported in 114 patients (85.7%), and 30-day mortality was 10.5%.

Univariate analysis of risk factors for clinical success or failure showed that the involvement of more than two vertebrae (94.7% vs. 24.5%, $p < 0.001$), mean SUV value (7.6 ± 3.8 vs. 7 ± 3.6 , $p = 0.03$), and inadequate source control of infection (84.2% vs. 7.9%, $p < 0.001$) were more frequently observed in patients with failure of therapy, compared with the clinical cure group. Conversely, targeted antibacterial therapy (78.9% vs. 42.1%, $p < 0.001$) and follow-up with FDG-PET/CT (50% vs. 10.5%, $p < 0.001$) were more frequently reported in the clinical cure group. No differences in 30-day mortality were observed. Follow-up with FDG-PET/CT showed that a decrease in the SUV of $>30\%$ from the baseline value was associated with clinical cure at the end of therapy. For tubercular VO, the mean SUV at the time of diagnosis was higher when compared with those of VO caused by other bacteria (11.4 ± 3.7 vs. 7 ± 2.3 , $p < 0.001$).

Logistic regression analysis showed that previous antimicrobial therapy and a delay of more than 5 days in performing biopsy were associated with an undiagnosed etiology of VO, as reported in Table 3A. Targeted antibacterial therapy and follow-up with FDG-PET/CT were associated with clinical cure at the end of therapy, while the involvement of more than two vertebrae and inadequate drainage of infection were associated with failure of therapy (Table 3B).

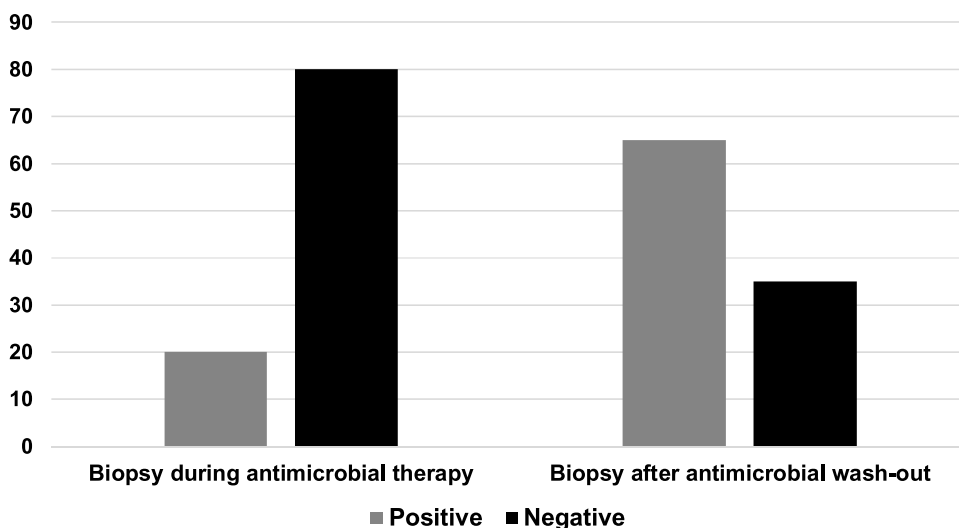


Figure 2. Biopsy results with and without antimicrobial washout.

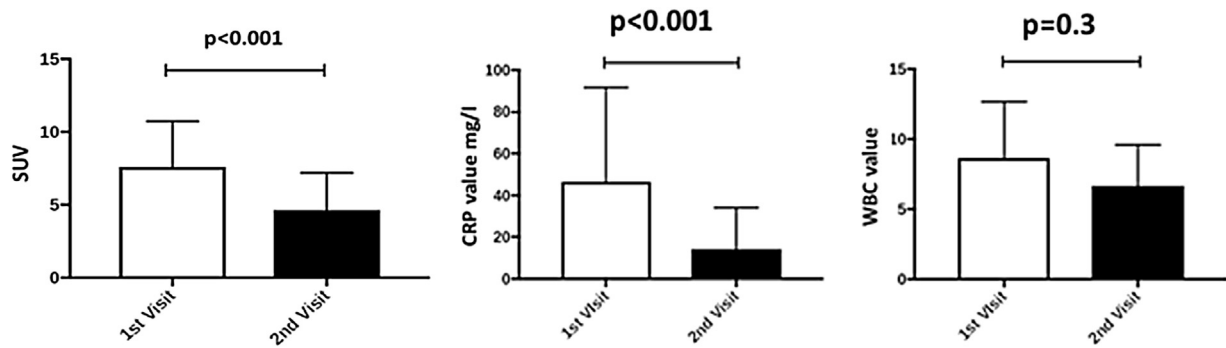


Figure 3. Mean SUV, CRP, and WBC values at the time of diagnosis (first visit) and at follow-up (second visit). SUV: standard uptake value; CRP: C-reactive protein; WBC: white blood cell count.

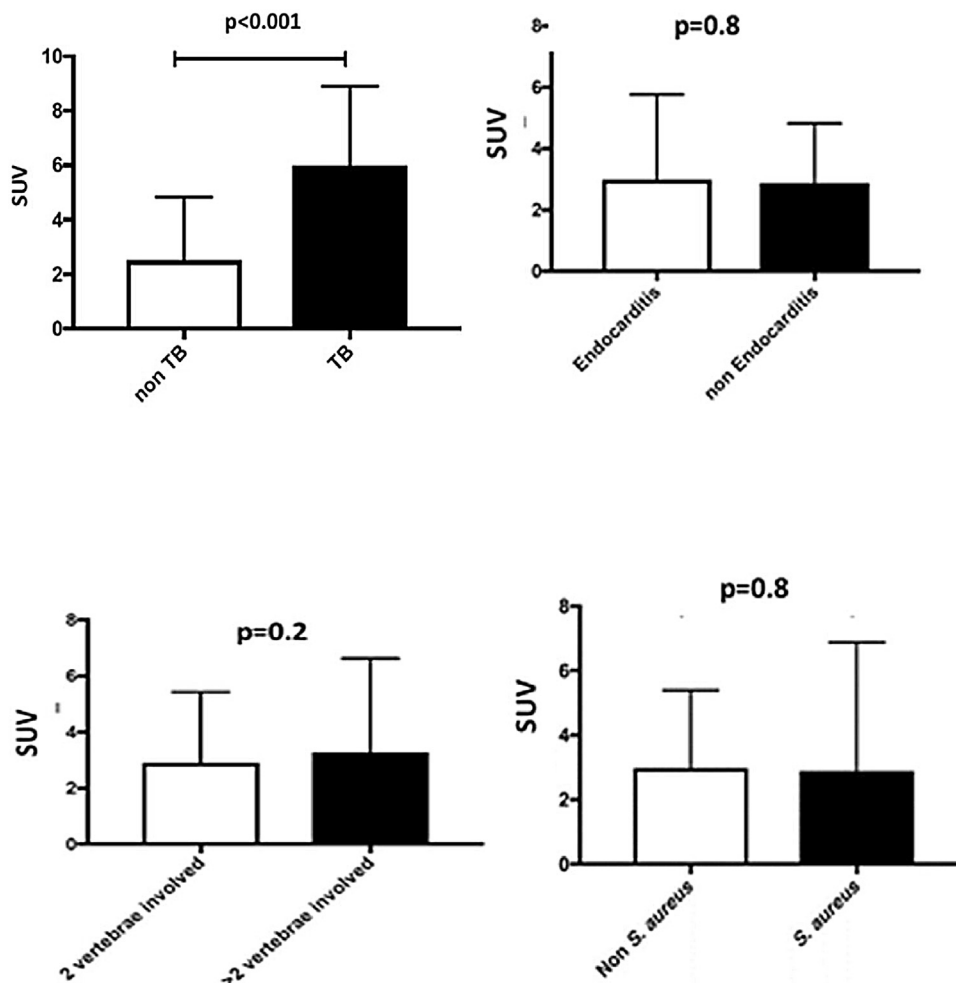


Figure 4. SUV values in subgroups of patients with vertebral osteomyelitis at follow-up (second visit). SUV: standard uptake value; VO: vertebral osteomyelitis; TB: tuberculosis.

Discussion

The study data showed that the rigorous application of the UDIPROVE protocol allowed the causative pathogens of VO to be obtained in almost 75% of cases, a higher rate when compared with data reported in the literature (Berbari et al., 2015). Of importance, the use of FDG-PET/CT was more reliable for the follow-up of infection when compared to MRI. As a consequence, targeted antibacterial therapy was independently associated with clinical cure of VO. Finally, previous antimicrobial therapy and a delay of

more than 5 days in performing biopsy were associated with an undiagnosed etiology of VO, while the involvement of more than two vertebrae and inadequate drainage of infection were associated with treatment failure.

The UDIPROVE protocol was associated with a high rate of diagnosis in patients with VO. In the literature, the sensitivity of image-guided biopsy in evaluated studies is about 40% (Sehn and Gilula, 2012). Bhavan et al. showed that the yield of causative pathogens increased with open biopsy (93%) compared with needle aspiration biopsy (48%) (Bhavan et al., 2010). Of note, VO is

Table 2

Baseline characteristics and outcomes of the study population, and univariate analysis of risk factors for clinical cure or failure of therapy.

Variables	Total population N = 133 (%)	Clinical cure n = 114 (%)	Failure of therapy n = 19 (%)	p-Value
Age (years), mean ± SD	65.7 ± 13.9	66.3 ± 14.1	65.6 ± 13.4	0.94
Male sex	68 (51.1)	58 (50.8)	10 (52.6)	1.0
Charlson Comorbidity Index, mean ± SD	2.5 ± 1.4	2.4 ± 1.5	2.5 ± 1.6	1.0
Previous spinal surgery	20 (15)	18 (15.7)	2 (10.5)	0.73
Previous antimicrobial therapy (30 days)	112 (84.2)	95 (83.3)	17 (89.4)	0.74
14-day antimicrobial treatment discontinuation before vertebral biopsy	98 (73.7)	85 (74.5)	13 (68.4)	0.58
>2 vertebrae involved	46 (34.5)	28 (24.5)	18 (94.7)	<0.001
Endocarditis	18 (13.5)	15 (13.1)	3 (15.7)	0.91
Other localization of infection	41 (30.8)	30 (26.3)	11 (57.8)	0.01
Biopsy/drainage performed	101 (75.9)	88 (77.1)	13 (68.4)	0.34
Blood culture positivity	34 (25.5)	30 (26.3)	4 (21)	0.62
SUV value, mean ± SD	7.2 ± 3.3	7 ± 3.6	7.6 ± 3.8	0.03
CRP concentration (mg/l), mean ± SD	42.2 ± 32.9	40.2 ± 31.7	44.9 ± 33.9	0.04
WBC count ($\times 10^9/l$), mean ± SD	8.3 ± 5.7	8.4 ± 5.2	8.1 ± 5	0.81
Inadequate source control of infection	25 (18.8)	9 (7.9)	16 (84.2)	<0.001
Time to biopsy, mean ± SD	11.6 ± 7.8	10.5 ± 8.2	12.9 ± 9.2	0.03
Targeted antibacterial therapy	98 (73.6)	90 (78.9)	8 (42.1)	<0.001
Time to definitive therapy, mean ± SD	10.9 ± 8.9	11.2 ± 9.2	10.2 ± 8.7	0.81
Length of definitive therapy, mean ± SD	41.9 ± 26.3	43.2 ± 27	40.1 ± 24.9	0.07
Length of hospitalization, mean ± SD	34 ± 17.2	33.6 ± 15.1	34.2 ± 20.5	0.92
Use of FDG-PET/CT	59 (44.3)	57 (50)	2 (10.5)	<0.001
30-day mortality	14 (10.5)	12 (10.5)	2 (10.5)	1.0

SD, standard deviation; SUV, standard uptake value; CRP, C-reactive protein; WBC, white blood cell; FDG-PET/CT, ^{18}F -fluorodeoxyglucose positron emission tomography/computed tomography.

Table 3

Variables independently associated with an undiagnosed etiology of vertebral osteomyelitis (A), clinical cure and failure of therapy (B).

A				B			
Variables	OR	95% CI	p-Value	Variables	OR	95% CI	p-Value
Previous antimicrobial therapy	2.3	1.98–3.12	<0.001	Targeted antibacterial therapy	0.34	0.21–0.54	0.01
>5 days delay in performing biopsy	4.2	3.12–7.23	<0.001	Follow-up with FDG-PET/CT	0.45	0.31–0.78	0.02
				>2 vertebrae involved	2.87	1.89–4.2	<0.001
				Inadequate drainage of infection	4.21	2.87–8.23	<0.001

OR, odds ratio; CI, confidence interval; FDG-PET/CT, ^{18}F -fluorodeoxyglucose positron emission tomography/computed tomography.

an infection that is very difficult to diagnose and treat, considering also the high rate of patients on antibiotic therapy at the time of diagnosis. The latter results in a low rate of positivity for BC and vertebral biopsy to determine the etiology of infection (Saeed et al., 2019). As reported in Figure 2, vertebral biopsy without antimicrobial discontinuation, according to the protocol, was associated with a high rate of negative results in the present study.

No studies have been performed that have helped guide the clinician managing patients with significant clinical or radiographic evidence of VO who also have sterile blood cultures and an initial non-diagnostic spinal aspiration biopsy result. Obtaining systemic inflammatory marker levels and diagnosis and follow-up with MRI may confirm the infection and help monitor the response to therapy, clarify the presence of abscess in need of drainage, and identify spinal instability that could benefit from surgical correction. In previous studies, patients with evidence of progressive epidural and/or paraspinal soft tissue infection on follow-up MRI have appeared to be at greater risk of treatment failure (Kowalski et al., 2007). The frequency and utility of obtaining follow-up inflammatory laboratory markers (like CRP) while patients are receiving antimicrobial therapy for VO have not been established. MRI has some value in assessing the response of soft tissue infections, but bone and disk abnormalities typically appear to worsen even in successfully treated patients (Zarrouk et al., 2007; Carragee, 1997). In the present study, the combination of FDG-PET/CT plus CRP values at the time of diagnosis and follow-up seems to be associated with higher accuracy in the monitoring of the response to therapy. FDG-PET/CT could be used in association with MRI for the detection of VO, but could also

contribute to the early determination of the response to therapy. The study data are in line with those of previous attempts to assess the treatment response that have relied on quantification of the SUV value before and after treatment in patients with VO (Nanni et al., 2012; Kim et al., 2009).

Of interest, the mean SUV was higher for tubercular VO when compared with pyogenic spondylodiscitis. Delayed diagnosis of a tubercular etiology may lead to severe consequences, including permanent spinal damage, and although spinal biopsies often represent the most accurate diagnostic method, low microbiological yields can be associated with tubercular VO. In this setting, imaging represents a key diagnostic tool to achieve early diagnosis of the disease and to monitor the response to antibiotic treatment. As observed previously (Bassetti et al., 2017), the association of specific FDG-PET/CT features, such as high SUV, with tubercular VO has been reported but remains to be determined definitively (Bakheet et al., 1998; Trecarichi et al., 2012). Then, the confirmation of high SUV values could allow physicians to consider a tubercular etiology for VO in a more timely manner (Heysell et al., 2013).

In this study population, failure of therapy for VO was observed in 19 patients (14.3%). The failure rate of patients treated for VO in most clinical studies has varied between 10% and 30% (Berbari et al., 2015; Ohtori et al., 2010; Hungenbach et al., 2013; Sehn and Gilula, 2012; Bhavan et al., 2010; Saeed et al., 2019; Kowalski et al., 2007; Zarrouk et al., 2007; Carragee, 1997; Nanni et al., 2012; Kim et al., 2009; Bassetti et al., 2017; Bakheet et al., 1998; Trecarichi et al., 2012; Heysell et al., 2013; Rissing, 1997). The therapeutic management of VO patients with treatment failure should be tailored to the suspected reason for failure. Consultation with a

surgeon and infectious disease physician experienced in the treatment of spinal infections may be warranted in those with suspected or proven treatment failure. The decision regarding whether a surgical intervention is warranted needs to be individualized and should incorporate similar principles as to whether to perform surgery at the time of VO diagnosis or not (Valancius et al., 2013).

Some important limitations of this study should be highlighted. First of all, there was no pre-intervention period, which reduces the quality of the evidence, since this is a descriptive analysis of patients managed according to the UDIPROVE protocol. Second, this was a single-center study with a short follow-up period (3 months), reducing the generalizability and comparability of the results. Finally, FDG-PET/CT was not performed for all of the study population and its routine use could be limited due to the high costs.

In conclusion, an etiology of infection was obtained in 73.6% of cases (combination of BC plus vertebral biopsy/drainage), according to the UDIPROVE algorithm. Moreover, the combination of the protocol with the use of FDG-PET/CT for diagnosis and follow-up was associated with a high rate of clinical cure (85.7%) in this very difficult-to-treat infection. Finally, antimicrobial therapy at the time of vertebral biopsy negatively influenced the possibility of obtaining an etiology of infection.

The rigorous application of antimicrobial washout in combination with vertebral biopsy and the collection of BC greatly increased the rate of diagnosis of VO causative pathogens. Finally, higher SUV values could be associated with a tubercular etiology, and the combination of SUV plus CRP values could be helpful in monitoring the response to therapy in all patients.

Author contributions

AR and MB designed the study; EG, AC, MS, BC, ER collected data; AR, ER, MB wrote the manuscript.

Funding

None.

Ethical approval

The study was preapproved by the local ethics committee.

Conflict of interest

None.

References

- Bakheet SM, Powe J, Ezzat A, Rostom A. F-18-FDG uptake in tuberculosis. *Clin Nucl Med* 1998;23:739–42.
- Bassetti M, Merelli M, Di Gregorio F, Della Siega P, Screm M, Scarparo C, et al. Higher fluorine-18 fluorodeoxyglucose positron emission tomography (FDG-PET) uptake in tuberculous compared to bacterial spondylodiscitis. *Skeletal Radiol* 2017;46(June):777–83.
- Berbari EF, Kanj SS, Kowalski TJ, Darouiche RO, Widmer AF, Schmitt SK, et al. 2015 Infectious Diseases Society of America (IDSA) clinical practice guidelines for the diagnosis and treatment of native vertebral osteomyelitis in adults. *Clin Infect Dis* 2015;61:e26–46.
- Bhavan KP, Marschall J, Olsen MA, Fraser VJ, Wright NM, Warren DK. The epidemiology of hematogenous vertebral osteomyelitis: a cohort study in a tertiary care hospital. *BMC Infect Dis* 2010;10:158.
- Carragee E. The clinical use of magnetic resonance imaging in pyogenic vertebral osteomyelitis. *Spine (Phila Pa 1976)* 1997;22(7):780–5.
- Chew FS, Kline MJ. Diagnostic yield of CT-guided percutaneous aspiration procedures in suspected spontaneous infectious diskitis. *Radiology* 2001;218:211–4.
- Gupta A, Kowalski TJ, Osmon DR, Enzler M, Steckelberg JM, Huddleston PM, et al. Long-term outcome of pyogenic vertebral osteomyelitis: a cohort study of 260 patients. *Open Forum Infect Dis* 2014;1:8.
- Heysell SK, Thomas TA, Sifri CD, Rehm PK, Houpt ER. 18-fluorodeoxyglucose positron emission tomography for tuberculosis diagnosis and management: a case series. *BMC Pulm Med* 2013;13:14.
- Hungenbach S, Delank KS, Dietlein M, Eysel P, Drzezga A, Schmidt MC. 18F-fluorodeoxyglucose uptake pattern in patients with suspected spondylodiscitis. *Nucl Med Commun* 2013;34:1068–74.
- Kim S-J, Kim I-J, Suh KT, Kim Y-K, Lee JS. Prediction of residual disease of spine infection using F-18 FDG PET/CT. *Spine (Philadelphia, Pa 1976)* 2009;34:2424–30.
- Kowalski TJ, Layton KF, Berbari EF, Steckelberg JM, Huddleston PM, Wald JT, et al. Follow-up MR imaging in patients with pyogenic spine infections: lack of correlation with clinical features. *AJNR Am J Neuroradiol* 2007;28:693–9.
- Nanni C, Boriani L, Salvadori C, Zamparini E, Rorato G, Ambrosini V, et al. FDG PET/CT is useful for the interim evaluation of response to therapy in patients affected by haematogenous spondylodiscitis. *Eur J Nucl Med Mol Imaging* 2012;39(10):1538–44.
- Ohtori S, Suzuki M, Koshi T, Yamashita M, Yamauchi K, Inoue G, et al. 18F-fluorodeoxyglucose-PET for patients with suspected spondylitis showing Modic change. *Spine* 2010;35:E1599–603.
- Rissing JP. Antimicrobial therapy for chronic osteomyelitis in adults: role of the quinolones. *Clin Infect Dis* 1997;25:1327–33.
- Saeed K, Esposito S, Ascione T, Bassetti M, Bonnet E, Carnelutti A, et al. Hot topics on vertebral osteomyelitis from the international society of antimicrobial chemotherapy. *Int J Antimicrob Agents* 2019;(June). doi:http://dx.doi.org/10.1016/j.ijantimicag.2019.06.013 pii: S0924-8579(19)30166-9. [Epub ahead of print].
- Sehn JK, Gilula LA. Percutaneous needle biopsy in diagnosis and identification of causative organisms in cases of suspected vertebral osteomyelitis. *Eur J Radiol* 2012;81:940–6.
- Trecarichi EM, Di Meco E, Mazzotta V, Fantoni M. Tuberculous spondylodiscitis: epidemiology, clinical features, treatment, and outcome. *Eur Rev Med Pharmacol Sci* 2012;16 Suppl 2:58–72.
- Valancius K, Hansen ES, Hoy K, Helmig P, Niedermann B, Bunge C. Failure modes in conservative and surgical management of infectious spondylodiscitis. *Eur Spine J* 2013;22:1837–44.
- Zarrouk V, Feydy A, Sallès F, Dufour V, Guigui P, Redondo A, et al. Imaging does not predict the clinical outcome of bacterial vertebral osteomyelitis. *Rheumatology (Oxford, England)* 2007;46(2):292–5.
- Zimmerli W. Clinical practice. Vertebral osteomyelitis. *N Engl J Med* 2010;362:1022–9.