Università degli studi di Udine

# Rainbow trout (Oncorhynchus mykiss) red mark syndrome - a standardised approach to histopathological scoring

*Original*

*Availability:*
This version is available http://hdl.handle.net/11390/1191067 since 2023-09-04T19:45:41Z

*Publisher:*

*Published*
DOI:

*Terms of use:*
The institutional repository of the University of Udine (http://air.uniud.it) is provided by ARIC services. The aim is to enable open access to all the world.

*Publisher copyright*

(Article begins on next page)

05 June 2025

UNIVERSITÀ DEGLI STUDI DI UDINE
hic sunt futura

19th International Conference on Diseases of Fish and Shellfish

DTU

# Rainbow trout Red Mark Syndrome - a standardised approach to histopathological classification


**Massimo Orioles*, Jacob G. Schmidt **, Tine M. Iburg**, Marco Galeotti ***

** Dipartimento di Dipartimento di Scienze Agroalimentari, Ambientali e Animali, Sezione di Scienze Animali e Veterinarie, Unità di Patologia Veterinaria;*

*** Unit for Fish and Shellfish Diseases, National Institute of Aquatic resources, Technical University of Denmark, Denmark.*


**BACKGROUND:** Red Mark Syndrome (RMS) is an infectious disease found to affect salmonids in the *Oncorhynchus* genus. No aetiological agent has been unequivocally identified for RMS, which is thus presently defined by histopathological features.

**METHODOLOGY :** We propose a semi-quantitative classification based on 5 categories (**negative to mild, mild, moderate, severe, regenerative**) of RMS lesions using samples from a cohabitation infection model established at DTU-Aqua. In 87 cases RMS was followed from early lesion development until late healing stages, and samples were taken at several time-points. Histological samples were analysed blindly at the University of Udine. Histological classification is based on severity of inflammatory infiltrate in the dermis spongiosus and scale pockets and a semi-quantitative description of each layer including integrity of the layer, presence of necrosis, oedema, congestions, haemorrhages, absence of scale pockets and scale pockets resorption.

**RESULTS AND CONCLUSIONS :** No bacteria were observed in any of the lesion sections. Lymphocytic and macrophagic (lympho-monocytic) inflammatory infiltrate was identified. **Negative to mild** cases showed focal mild infiltrate of the dermis spongiosum with frequent dilation of the scale pockets. **Mild** cases showed multifocal mild inflammation of the dermis spongiosum and mild inflammatory infiltrate of the hypoderma. Epidermis may show infiltration as well. **Moderate** and **Severe** cases showed an increased lympho-monocytic inflammation involving all skin layers. Epidermis showed a progressive loss of integrity and ulceration. Frequent scale resoprtion is observed. Muscle remained mildly to moderately involved even in most severe cases. Microscopically, **Regenerative** cases showed features typical of mild cases, but with scales in regenerative phases. We identified evident correspondences between macroscopic and microscopic categories.
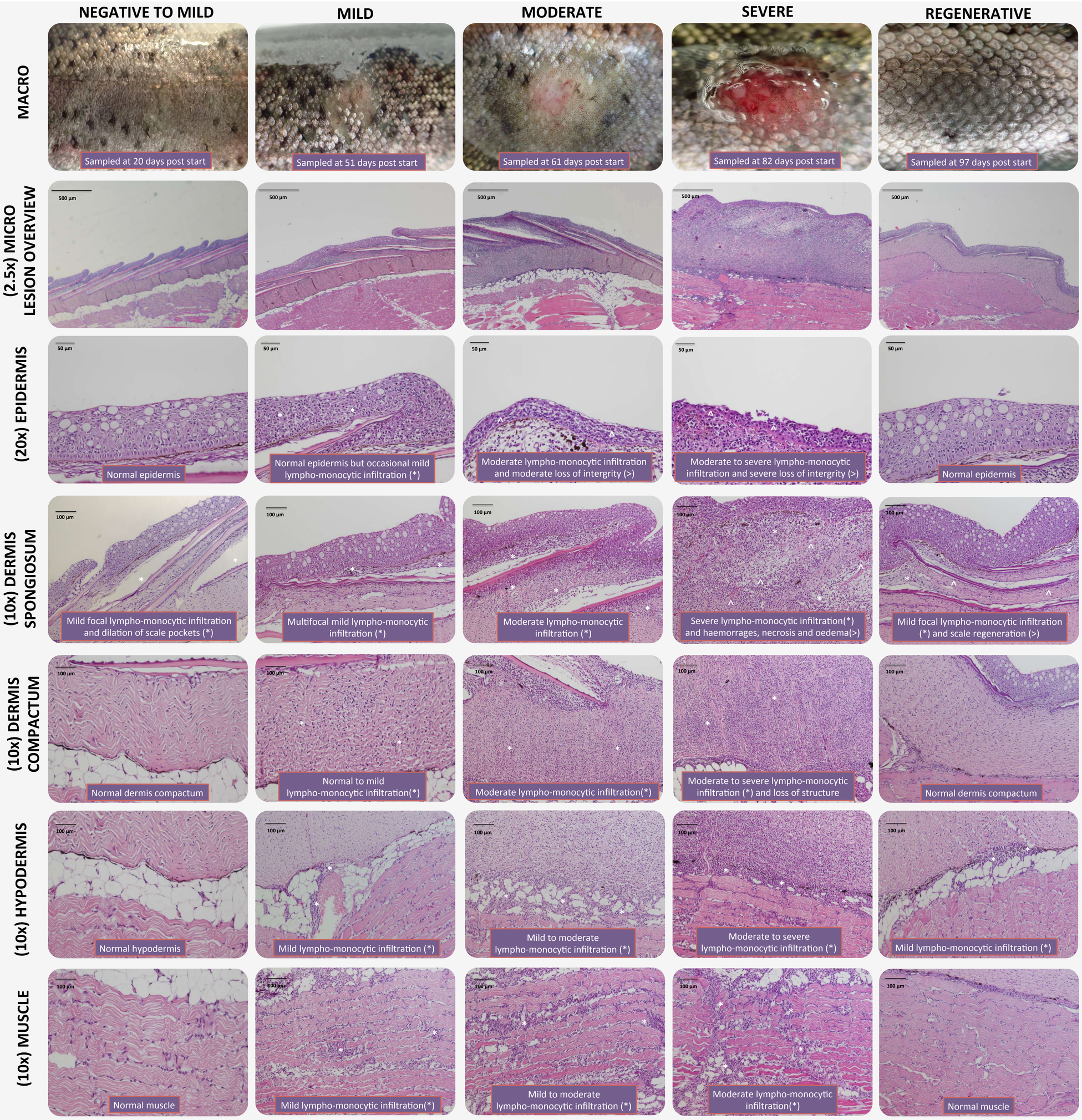
This classification can provide a valuable standardized approach and guide the pathologist in the analysis and definition of suspected RMS lesions. Further studies are needed to validate statistically the results and evaluate interobserver agreement.