Regenerative Therapy 15 (2020) 169–172

Contents lists available at ScienceDirect

Regenerative Therapy

journal homepage: http://www.elsevier.com/locate/reth

Letter to the editor

Dermatofibrosarcoma protuberans arising in post-mastectomy irradiated breast after autologous fat-transfer reconstruction

Keywords:
Dermatofibrosarcoma protuberans
Cancer radiation induced
Breast reconstruction
Autologous transplantation

Key points

- Ionizing radiation is a known risk factor for malignant neoplasms, including sarcomas.
- The increasing use of Autologous Fat Transfer in breast cancer patients has raised concerns regarding its oncologic safety.
- The regenerative effects of Autologous Fat Transfer are based on the same hormones, growth factors and stem cells that stimulate neoplastic angiogenesis and cancer progression.
- One must consider a possible synergism between radiotherapy and Autologous Fat Transfer that promote tumour growth.

Dear editor,

Dermatofibrosarcoma protuberans (DFSP) is a rare soft tissue sarcoma involving dermis, subcutaneous fat, and rarely fascia/muscle. Such tumours are locally aggressive, marked by high local recurrence rates and low metastatic potential [1]. DFSP may arise within surgical scars, old burns, previous traumatic injuries, radiation dermatitis, vaccinations, central venous line puncture sites, and even insect bites. Herein, we describe a patient with post-mastectomy DFSP occurring after breast irradiation and reconstruction by autologous fat transfer (AFT).

A 53-year-old woman was diagnosed with breast mucinous carcinoma on November 2014 (Fig. 1). Magnetic resonance imaging confirmed a right breast tumour of outer quadrants and an axillary mass. Ultrasound – guided axillary fine-needle aspiration provided a cytological diagnosis of metastatic breast cancer. The patient received neoadjuvant chemotherapy (paclitaxel, adriamycin, cyclophosphamide) and in January 2015 underwent nipple-sparing mastectomy with axillary lymph node dissection. Given the limited volume of contralateral breast, multistage fat grafting was the chosen means of reconstruction. The first lipoinjection was performed at the time of mastectomy; 180 g of fat were introduced into Pectoralis Major muscle. Radiotherapy (50 Gy in 25 fractions of 2 Gy over 5 weeks) was then delivered, during March and April 2015, to the chest wall and the supraclavicular lymph nodes (Fig. 2). Between 2015 and 2018, six fat grafting procedures (230 g, 200 g, 195 g, 210 g, 160 g, and 170 g, respectively) took place, completing the reconstruction (Fig. 3); the fat tissue was injected subcutaneously, in front of the Pectoralis Major muscle, in all quadrants of the right breast. The entire postoperative course was uneventful. The patient returned in September 2019 with a lump beneath the skin of upper right breast that had enlarged in the preceding 4 months. She denied any recent weight loss, fever, night sweats, or chills. By physical examination, a firm but painless mass (2.5 cm) was detected, unaccompanied by heat or redness. An incisional biopsy was performed. In sections stained with hematoxylin and eosin, the highly proliferative spindle-shaped cells characteristic of DFSP were identified. Plain chest X-ray and ultrasonography of abdomen and regional lymph nodes were clear. In December 2019, the mass

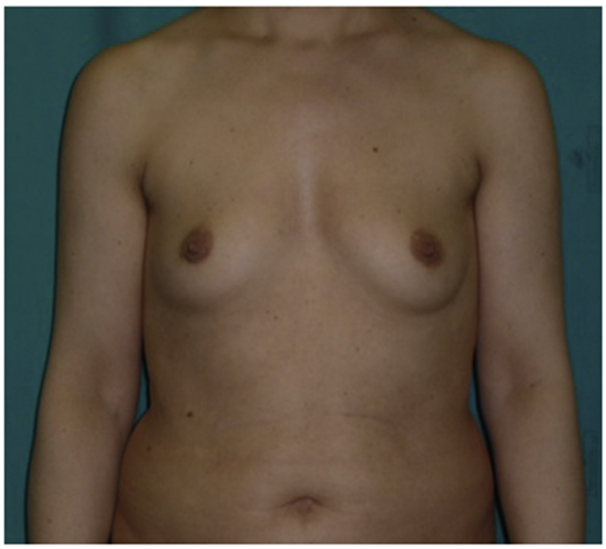

Fig. 1. Pre-mastectomy picture.

Peer review under responsibility of the Japanese Society for Regenerative Medicine.

https://doi.org/10.1016/j.reth.2020.08.002
2352-3204/© 2020, The Japanese Society for Regenerative Medicine. Production and hosting by Elsevier B.V. This is an open access article under the CC BY-NC-ND license (http://creativecommons.org/licenses/by-nc-nd/4.0/).

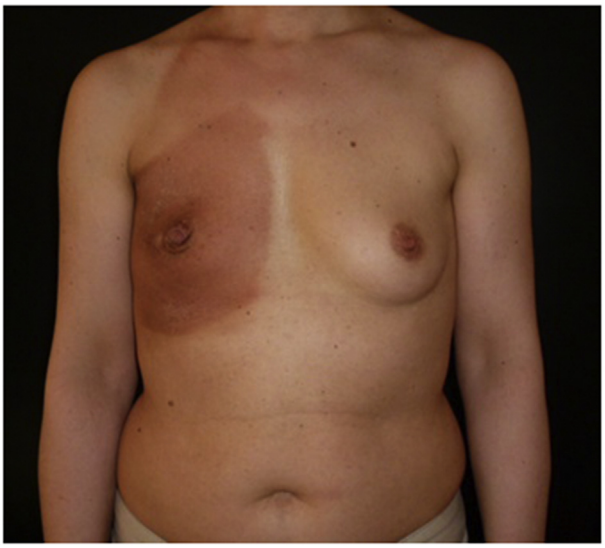

Fig. 2. Two weeks after term of radiotherapy. This last was delivered to the right chest wall and the supraclavicular lymphnodes.

Fig. 4. Surgical excision of DFSP with 3 cm-safe margin.

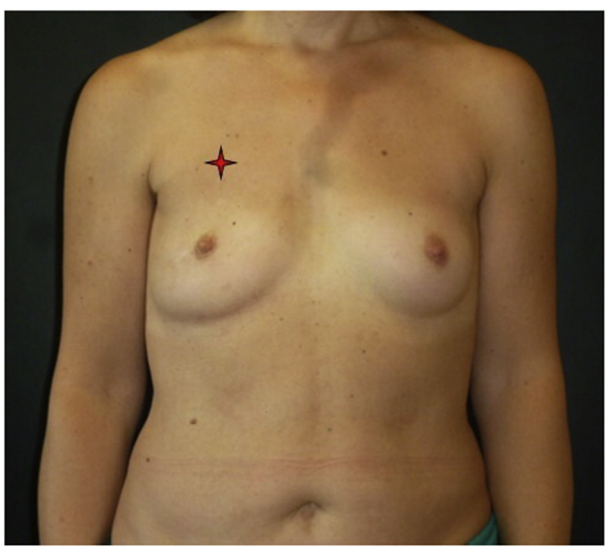

Fig. 3. Final result six months after seventh fat grafting session. Red cross indicates the location of DFSP.

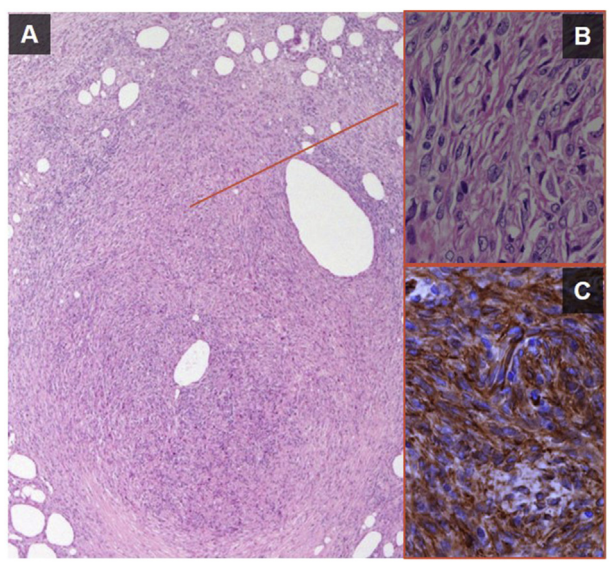

Fig. 5. Histologic appearance of DFSP: low-power view (H&E stain 2X) of tumor cells (A); high magnification (H&E stain 40X) shows spindle-shaped tumor cells arranged in irregular intertwining bands (B). Immunohistochemistry of the tumor cells (magnification 40X) showing diffuse positivity for CD34 (C).

was surgically excised, with a 3-cm margin, including underlying muscular fascia (Fig. 4). The defect was covered by a partial-thickness skin graft. Tissue examination revealed multiple foci of DFSP deep within dermis. Immunohistochemical stains were positive for Vimentin and CD34 (Fig. 5). Ki-67 positivity was at 25%. Three months after excision, no local recurrence or metastasis was evident.

AFT has become increasingly common for breast reconstructions or other reasons [2]; advantages include no risk of rejection, relative abundance of adipose tissue in most patients, ease of obtaining fat by lipoaspiration, minimal donor-site morbidity. There is an increasing belief that fat grafting under radiated skin can reverse the damage caused by radiotherapy. These clinical benefits were attributed to the regenerative properties of undifferentiated multi-potent adipose tissue-derived stem cells (ADSCs) within the stromal vascular fraction (SVF) of lipoaspirate [3]. ADSCs are able to secrete multiple growth factors (GFs) including platelet-derived growth factor (PDGF), vascular endothelial growth factor (VEGF), insulin-like growth factor 1 (IGF-1), hepatocyte growth factor (HGF), and transforming growth factor (TGF)-β. This last plays a central role in tumor suppression and yet, paradoxically, in tumor promotion. Concerning molecular signals implicated in the pathogenesis of radiotherapy-injury, up-regulation of the TGF-β signaling is a mechanism common to numerous conditions of pathological fibrosis [4]. Radiotherapy, particularly associated with surgery, creates tissue hypoxia. ADSCs' secretion of aforementioned pro-angiogenetic, anti-apoptotic and immunomodulatory growth factors is useful to increase blood supply in poorly vascularized tissues, but at the same time can promote malignant transformation and cancer progression. ADSCs are indeed able to affect the epithelial

to mesenchymal transition (EMT). This essential step in tumour progression determines the shift of the tumour toward a more invasive phenotype [5]. The effects of ADSCs on EMT and cellular migration are mediated, among other, by the Wnt pathway. There is also a reverse influence, as breast tumor-derived factors are able to promote ADSCs transformation into tumor-associated fibroblasts, through the inhibition of Wnt-signaling [6]. As aforementioned, ADSCs release TGF-β, which is responsible for collagen deposition and extra-cellular matrix remodeling. However, TGF-β secretion promote EMT in cancer cells. Parallelly, TGF-β signaling is able to induce myofibroblastic differentiation in ADSCs exposed to breast cancer exosomes, thus promoting desmoplastic transformation of the tumor microenvironment [7]. In earlier reports, DFSP plausible aetiologies are largely ignored. It is reasonable to question whether fat grafting played a role in predisposing to DFSP. The cellular origin of soft tissue sarcomas is not fully understood. According to "cancer stem cell hypothesis", tumours originate from the malignant transformation of stem cells; it is true that multipotent stem cells can differentiate into diverse cellular lineages and can be recruited to areas of severe tissue injury, but in some settings they may also initiate malignant transformation. Nowadays, the original belief that tumours might originate from the malignant transformation of their tissue-specific stem cells is largely abandoned. It was observed that ADSCs may represent potential initiating cells of malignancy, including soft tissue sarcomas. Chen et al. [8] treated ADSCs from mice with 3-methycholanthrene, a potent carcinogen. The resultant transformed ADSCs were then injected subcutaneously into immunocompromised mice; they found that they generated several types of soft tissue sarcomas (synovial sarcoma, malignant fibrous histiocytoma, fibrosarcoma). Oncological concerns have been raised regarding the use of AFT in patients with previous breast cancer. Currently, there is no clinical evidence of oncologic risk associated with fat grafting [9]. Sarcomas, on the other hand, are biologically quite different from breast carcinoma. An unexpected local recurrence of osteosarcoma, 13 years after definitive surgery and 18 months after lipofilling, caused Perrot et al. [10] to pursue a possible link. Using preclinical models of osteosarcoma, they ultimately demonstrated that fat grafts or progenitor cells were capable of promoting tumour growth. Pennati et al. [11] gauged the oncologic safety of fat grafting in patient with sarcomas, including seven cases with DFSP. Two lesions recurred locally prior to fat grafting, none developing thereafter. Having observed no heightened risk of malignancy, they still suggested a pause of at least 12 months between last oncologic surgery and procedures of this type. Also ionizing radiation is known to induce various malignant neoplasms [12], including sarcomas. The following features generally apply to post-radiation soft tissue sarcomas: (i) history of prior irradiation, (ii) origination in field of radiation, (iii) 2-year minimum latency from radio exposure to onset, (iv) histopathology unlike that of irradiated antecedent. All stipulations above applied to our patient. McLoughlin et al. [13] were the first to chronicle post-radiation DFSP, but cases published since then have been scarce [14–17]. The pathogenesis of radiation-induced soft tissue sarcomas has yet to be fully explained. Meehan & LeBoit [18] examined a possible correlation between spindle cells of DFSP and radiation fibroblasts, as hallmarks of chronic radiation dermatitis. Based on their immunohistochemical analysis, it appears the two are unrelated. Aiba et al. [19] also examined CD34 expression by various fibrohistiocytic tumours, discovering that DFSP is unique in this regard. In normal tissues, CD34-positive dendritic cells surround blood vessels, nerves, hair follicles, and sweat glands; and circulating intravascular fibroblast-like cells (fibrocytes), staining positive for CD34 and Vimentin, have been reported [20]. These cells comprise a subpopulation of leukocytes that mediate tissue repair. Ostensibly, direct irradiation or long-term stimulation by cytokines, especially transforming growth factor (TGF)-β secreted by radiation-damaged tissues [10], may trigger their malignant transformation. Studies have shown that DFSP demonstrates the chromosomal translocation t (17; 22) (q22; q13) between chromosome 17 and chromosome 22. This translocation results in the collagen 1A1 (COL1A1) gene from chromosome 17 fusing with the platelet-derived growth factor (PDGF)-β gene on chromosome 22. COL1A1 encodes a major component of type 1 collagen, the most abundant collagen in humans. PDGFβ is a tyrosine kinase that acts as a growth factor for connective tissue cells, normally under negative control. The gene rearrangement upregulates PDGFβ, resulting in overproduction of PDGF, continuous autocrine activation of PDGF receptor (PDGFR)-β, cellular proliferation and tumour formation. Kikuchi et al. [21] established fibroblast-like cell strains from DFSP and investigated their response to various growth factors, including PDGF, compared with normal fibroblasts. They found increased expression of PDGFβ receptors in DFSP cells; they did not observe spontaneous production of PDGF protein in the cytoplasmic extracts of normal fibroblasts or DFSP cells, suggesting that TGF-β, which is also known as an inducer of PDGF-like peptides in fibroblasts, could induce the expression of PDGF-like peptides on tumour cells *in vivo*. Finally, because the first lipoinjection in our patient was prior to radiotheraphy, one must consider the effects of radiotherapy on adipose tissue. Can radiotherapy induce malignant transformation in mesenchymal stem cells? Recent findings suggest that ADSCs display radio-resistance compared with other components of SVF. This may be explained by a greater ability of mesenchymal stem cells to retain their proliferative capacity due to superior DNA damage repair mechanisms, compared with those found in terminally differentiated cells. Additionally, reduced metabolic demands of steady-state ADSCs may protect them from hypoxia and subsequent apoptosis, enabling their preservation [22]. Although mesenchymal stem cells are radio-resistant in terms of cellular survival, radiotherapy may result in irreversible injury in terms of the potential for cellular differentiation, as observed by Schönmeyr et al. [23]. On the other hand, Christensen et al. [24] described how bone marrow-derived human mesenchymal stem cells were capable of exhibiting a malignant phenotype when irradiated with a low (2.5 Gy) and a high (15 Gy) dose of gamma-rays and followed for up to 6 months after radiation. Inoculation of the transformed mesenchymal stem cells on immunocompromised mice resulted in tumours of primitive mesenchymal origin. It is very complex to trace the exact origin of DFSP in this patient; we are not able to ascribe it to radiotherapy only rather than AFT only, or a possible synergic action of both, but the events that transpired underscore a need for additional studies. We also acknowledge the limitation of a 3-month follow-up, presuming a 3-year window for recurrent disease. Long-term monitoring of these patients is imperative.

Funding

No specific funding was received from any public, commercial, or not-for-profit sources to conduct the work herein.

Informed consent

The patient provided written consent for the inclusion of material pertaining to himself, and she understood that she was fully anonymized and could not be identified via this report.

Declaration of competing interest

None.

References

[1] Lin CT, Chang SC, Chen TM, Lin HC, Chen SG. Postradiation dermatofibrosarcoma protuberans: case report and literature review. Acta Chir Belg 2015 Jan;115(1):87–90 (PMID: 27384904).

[2] Mura S, Fin A, Parodi PC, Denton CP, Howell KJ, Rampino Cordaro E. Autologous fat transfer in the successful treatment of upper limb linear morphoea. Clin Exp Rheumatol 2018 Jul-Aug;36(4):183. Suppl 113(PMID: 29465364).

[3] Rigotti G, Marchi A, Galiè M, Baroni G, Benati D, Krampera M, et al. Clinical treatment of radiotherapy tissue damage by lipoaspirate transplant: a healing process mediated by adipose-derived adult stem cells. Plast Reconstr Surg 2007 Apr 15;119(5):1409–22 (PMID: 17415234).

[4] Stone HB, Coleman CN, Anscher MS, McBride WH. Effects of radiation on normal tissue: consequences and mechanisms. Lancet Oncol 2003 Sep;4(9):529–36 (PMID: 12965273).

[5] Campbell K. Contribution of epithelial-mesenchymal transitions to organogenesis and cancer metastasis. Curr Opin Cell Biol 2018 Dec;55:30–5 (PMID: 30006053).

[6] Visweswaran M, Keane KN, Arfuso F, Dilley RJ, Newsholme P, Dharmarajan A. The influence of breast tumour-derived factors and Wnt antagonism on the transformation of adipose-derived mesenchymal stem cells into tumour-associated fibroblasts. Cancer Microenviron 2018 Jun;11(1):71–84 (PMID: 29637435).

[7] Scioli MG, Storti G, D'Amico F, Gentile P, Kim BS, Cervelli V, et al. Adipose-derived stem cells in cancer progression: new perspectives and opportunities. Int J Mol Sci 2019 Jul;20(13):3296 (PMID: 31277510).

[8] Chen H, Zhang S, Wen JC, Zheng JK, Chen Q, Li WY, et al. Several types of soft tissue sarcomas originate from the malignant transformation of adipose tissue-derived stem cells. Mol Med Rep 2010 May - Jun;3(3):441–8 (PMID: 21472259).

[9] Semprini G, Cattin F, Lazzaro L, Cedolini C, Vaienti L, Parodi PC. About locoregional recurrence risk after lipofilling in breast cancer patients: our experience. Minerva Chir 2014 Apr;69(2):91–6 (PMID: 24847895).

[10] Perrot P, Rousseau J, Bouffaut AL, Rédini F, Cassagnau E, Deschaseaux F, et al. Safety concern between autologous fat graft, mesenchymal stem cell and osteosarcoma recurrence. PloS One 2010 Jun 8;5(6):e10999 (PMID: 20544017).

[11] Pennati A, Riggio E, Marano G, Biganzoli E. Autologous fat grafting after sarcoma surgery: evaluation of oncological safety. J Plast Reconstr Aesthetic Surg 2018 Dec;71(12):1723–9 (PMID: 30224167).

[12] Anania G, Parodi PC, Sanna A, Rampino E, Marcotti E, Di Loreto C, et al. Radiation-induced angiosarcoma of the breast: case report and self-criticism of therapeutic approach. Ann Chir 2002 May;127(5):388–91 (PMID: 12094424).

[13] McLoughlin PM, Girach M, Wood GA. Dermatofibrosarcoma protuberans of the scalp. Br J Oral Maxillofac Surg 1992 Dec;30(6):401–3 (PMID: 1450166).

[14] Argiris A, Dardoufas C, Aroni K. Radiotherapy induced soft tissue sarcoma: an unusual case of a dermatofibrosarcoma protuberans. Clin Oncol 1995;7:59–61 (PMID: 7727312).

[15] Kamiya T, Saga K, Kaneko R, Ono I, Kawada M, Maeda Y. Postradiation dermatofibrosarcoma protuberans. Acta Derm Venereol 2006;86:152–3 (PMID: 16648920).

[16] Kumar R, Rodriguez V, Khan SP, Laack NN, Arndt CA. Postradiation dermatofibrosarcoma protuberans in a patient with Wilms tumor. J Pediatr Hematol Oncol 2011;33:635–6 (PMID: 21423044).

[17] Huber GF, Matthews TW, Dort JC. Radiation-induced soft tissue sarcomas of the head and neck. J Otolaryngol 2007;36:93–7 (PMID: 17459279).

[18] Meehan SA, LeBoit PE. An immunohistochemical analysis of radiation fibroblasts. J Cutan Pathol 1997;24:309–13 (PMID: 9194585).

[19] Aiba S, Tabata N, Ishii H, Ootani H, Tagami H. Dermatofibrosarcoma protuberans is a unique fibrohistiocytic tumour expressing CD34. Br J Dermatol 1992;127:79–84 (PMID: 1382538).

[20] Bucala R, Spiegel LA, Chesney J, Hogan M, Cerami A. Circulating fibrocytes define a new leukocytes subpopulation that mediates tissue repair. Mol Med 1994;1:71–81 (PMID: 8790603).

[21] Kikuchi K, Soma Y, Fujimoto M, Kadono T, Sato S, Abe M, et al. Dermatofibrosarcoma protuberans: increased growth response to platelet-derived growth factor BB in cell culture. Biochem Biophys Res Commun 1993;196(1):409–15 (PMID: 8216321).

[22] Shukla L, Morrison WA, Shayan R. Adipose-derived stem cells in radiotherapy injury: a new frontier. Front Surg 2015 Jan 28;2:1 (PMID: 25674565).

[23] Schönmeyr BH, Wong AK, Soares M, Fernandez J, Clavin N, Mehrara BJ. Ionizing radiation of mesenchymal stem cells results in diminution of the precursor pool and limits potential for multilineage differentiation. Plast Reconstr Surg 2008 Jul;122(1):64–76 (PMID: 18594388).

[24] Christensen R, Alsner J, Brandt Sorensen F, Dagnaes-Hansen F, Kolvraa S, Serakinci N. Transformation of human mesenchymal stem cells in radiation carcinogenesis: long-term effect of ionizing radiation. Regen Med 2008 Nov;3(6):849–61 (PMID: 18947308).

Sebastiano Mura*, Giovanni Miotti, Filippo Contessi Negrini, Emanuele Rampino Cordaro

Plastic and Reconstructive Surgery, Academic Hospital of Udine, DAME (Department of Medical Area), University of Udine, Italy

Laura Mariuzzi

Institute of Pathology, Academic Hospital of Udine, DAME (Department of Medical Area), University of Udine, Italy

Pier Camillo Parodi

Plastic and Reconstructive Surgery, Academic Hospital of Udine, DAME (Department of Medical Area), University of Udine, Italy

* Corresponding author. Department of Plastic and Reconstructive Surgery, Ospedale "Santa Maria della Misericordia", Piazzale Santa Maria della Misericordia 15, 33100, Udine (UD), Italy.
E-mail address: banomu88@live.it (S. Mura).

8 July 2020