




ELSEVIER

Contents lists available at ScienceDirect

Oral and Maxillofacial Surgery Cases

journal homepage: www.oralandmaxillofacialsurgerycases.com

A case report of chondrocalcinosis of the temporomandibular joint: Surgical management and literature review

Serena Brontoladi^a, Salvatore Sembronio^a, Alessandro Tel^a, Andrea Lazzarotto^a, Massimo Robiony^{a,*}

^a Maxillofacial Surgery Department, Academic Hospital of Udine, Department of Medicine, University of Udine, Italy

ARTICLE INFO

Keywords:

Chondrocalcinosis
TMJ replacement
Custom-made
Facial care
Project

ABSTRACT

Background: Chondrocalcinosis is a metabolic disorder characterized by non-infectious joint inflammation with intra- or periarticular calcification. Temporomandibular (TMJ) chondrocalcinosis is rare and not usually included in the differential diagnosis of TMJ and facial pain disorders.

Case report: A 67-year-old woman presented with a calcified mass in the right TMJ between the condyle and glenoid fossa, eroding into the floor of the middle cranial fossa due to calcium pyrophosphate deposition in the TMJ. She underwent surgical excision of the mass with immediate reconstruction with a custom-made prosthesis. On follow-up, there was complete clinical resolution, with no evidence of recurrence. Literature related to surgical treatment of chondrocalcinosis of TMJ and its treatment was reviewed. Surgery is the most commonly used treatment. A custom-made device allowed us to bridge the defect caused by the destructive disease process.

Conclusion: Custom-made prostheses can be considered a safe and effective solution in erosive forms of chondrocalcinosis, replacing the TMJ to restore functionality and correct the anatomical defect.

1. Background

Chondrocalcinosis is a rare disease that has been reported infrequently, characterized by noninfectious joint inflammation with intra- or periarticular calcification, caused by calcium pyrophosphate dihydrate (CPPD) crystal deposition. “Pyrophosphate arthropathy” is an alternative term used to describe the structural damage to the joint caused by deposition of CPPD crystals simulating degenerative joint disease; “pseudogout” refers to intermittent acute attacks of arthritis [1]; “tophaceous pseudogout” characterizes lesions that have massive or tumoural CPPD crystal deposition and is one of the rarest forms of CPPD deposition disease, however, it should be mentioned because of its clinical and radiological resemblance to cartilaginous tumors [2]. Pathogenesis is not clear. Synovial fluid levels of inorganic pyrophosphate (PPi) are higher than plasma levels in these patients, and this gap might indicate a local origin of PPi. Chondrocytes are believed to overproduce PPi since microscopic cartilage examination reveals the initial presence of crystals at the lacunar margin of these cells. Various conditions have been associated with CPPD crystal deposition disease such as hemochromatosis, hemosiderosis, familiar hypocalciuric hypercalcemia, hyperparathyroidism, hypothyroidism, hypophosphatasia,

* Corresponding author. Head of Maxillofacial Surgery Department, Academic Hospital of Udine, Department of Medicine University of Udine, P. le S. Maria della Misericordia, 133100, Udine, Italy.

E-mail address: massimo.robiony@uniud.it (M. Robiony).

<https://doi.org/10.1016/j.omsc.2020.100180>

Received 18 June 2020; Received in revised form 20 July 2020; Accepted 22 July 2020

Available online 26 July 2020

2214-5419/© 2020 The Authors. Published by Elsevier Inc. This is an open access article under the CC BY-NC-ND license

(<http://creativecommons.org/licenses/by-nc-nd/4.0/>).

hypomagnesemia, diabetes, chronic renal dialysis, gout, aging, amyloidosis, neuropathic joint disease, oral parafunctional habits, trauma and surgery [3]. Deposition of CPPD crystals is more common in large fibrocartilaginous joints than in hyaline cartilage. It is characterized by linear and punctate radiodensities in fibrocartilaginous structures, such as meniscus or articular fibrocartilage, and most commonly affects the knee meniscus and triangular ligament of the wrist [4]. Radiological diagnosis is essential, but definitive diagnosis comes from analysis of the crystals: a differential diagnosis from other crystalline-induced arthritis or tumors with calcification in the TMJ must be made. CPPD crystals are rhomboid and display weak positive birefringence and for a definite diagnosis of CPPD arthropathy a demonstration of rhomboidal crystals on polarized light microscopy is required. Temporomandibular (TMJ) chondrocalcinosis was first described in 1976 [5]. Chondrocalcinosis is not usually included in the differential diagnosis of TMJ and facial pain disorders, unless the diagnosis has been established in other joints. CPPD may mimic other joint affections, such as gout, rheumatoid arthritis, degenerative joint disease, neoplastic or infectious conditions, further delaying the diagnosis [6]. Common signs and symptoms of TMJ chondrocalcinosis include pain, joint swelling, trismus, limited mouth opening, malocclusion, and hearing loss due to middle ear effusion. These symptoms are very common in many TMJ disorders, including both inflammatory and neoplastic processes [7]. Since chondrocalcinosis can lead to significant alterations of normal TMJ anatomy, treatment of advanced stages might be challenging. Surgical treatment is the most commonly described approach to TMJ chondrocalcinosis, and many approaches have been described. We report a case of chondrocalcinosis of the TMJ that required an immediate alloplastic total joint replacement in a one-stage surgical approach. A review of the literature related to surgical treatment of chondrocalcinosis is also presented.

2. Case report

A 67-year-old woman with a three-year history of pain in the right preauricular area and progressive reduction of mandibular opening was referred to Maxillofacial Surgery Department (Academic Hospital, University of Udine). On examination, she had no facial swelling or asymmetry, and no tenderness of the masticatory muscles on palpation was appreciated. There was tenderness on the lateral pole of the right TMJ. Mouth opening was limited to 25 mm, causing right TMJ pain. The patient did not complain about any modification of the occlusion, although an expansive lesion of TMJ was present. Moreover, the patient was edentulous in the posterior mandible and even if there were any tendencies to posterior open bite, this was not reported by the patient, nor did it appear at the physical examination. She had no history of other joint disease conditions. Computed tomography (CT) showed a destructive process with a calcified mass in the right TMJ between the condyle and glenoid fossa with erosion into the floor of the middle cranial fossa and extending laterally and medially into the infratemporal fossa (Fig. 1). Virtual surgical planning of the resection was based on the preoperative CT images (Fig. 2). Resection was simulated, enabling finalization of the design of the joint prosthesis. Preauricular and retro-submandibular approach were performed to gain access to the angle and ramus of the mandible. The entire joint space appeared to be filled with granulomatous tissues eroding the glenoid fossa and disrupting the TMJ capsule. The mass was resected and extensive debridement was performed. Condylectomy was performed before removing the tumor, to provide a wider access to the medial compartment of the joint. Moreover, coronoidectomy was also performed based on the following assumptions: 1) the lesion extended up to the infratemporal fossa and, although it was not a malignant neoplasm, coronoidectomy was necessary to completely remove it; 2) since a long time, the patient reported a reduced mouth opening: for this reason, we performed coronoidectomy to provide a further improvement of mouth opening. Remarkably, coronoidectomy is commonly accomplished in the treatment of ankyloses, where there is a shortening of temporalis muscle fibers owing to the chronic reduction of mouth opening. The custom-made prosthesis (SINTAC Biomedical Engineering, Trento, Italy) was then inserted. This device consists of a titanium mandibular implant and a polyethylene fossa; titanium screws were used to attach both the condylar and fossa implants to the bone (Fig. 3). A histopathological examination of the specimens supported the diagnosis of chondrocalcinosis. The patient recovered without complications and was discharged on the third postoperative day. At 1-year follow-up, the patient was free of disease and marked improvement in the subjective and objective clinical parameters was noticed. Joint function had improved to 35-mm interincisal opening and occlusion was maintained. 1-year postoperative CT confirmed complete removal of the lesion, with no signs of relapse (see Fig. 4).

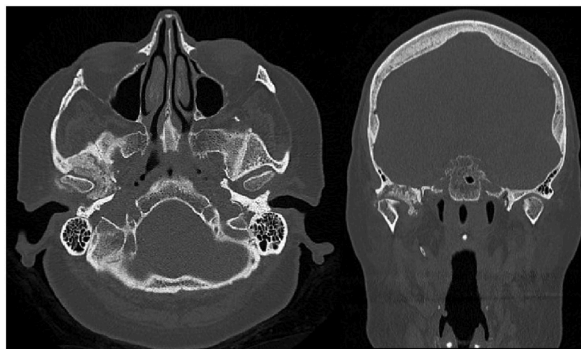


Fig. 1. Axial and Coronal CT scan demonstrating the presence of a calcified mass centered in the right TMJ extending medially into the infratemporal fossa and mass eroding into the floor of the middle cranial fossa.

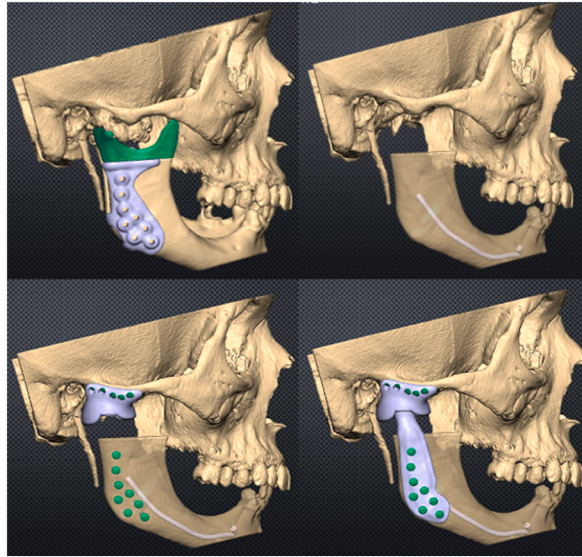


Fig. 2. Virtual surgical planning.

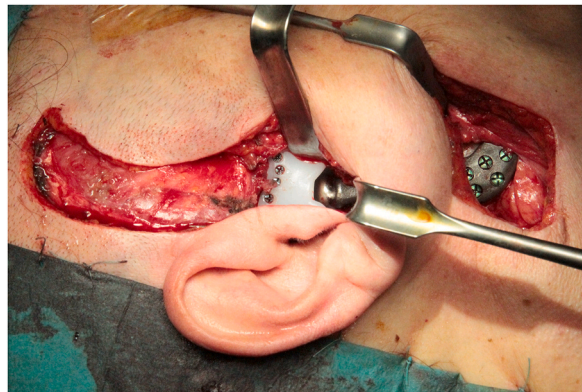


Fig. 3. Intraoperative view of the right temporomandibular joint, total joint prosthesis components in place after complete removal of lesion.

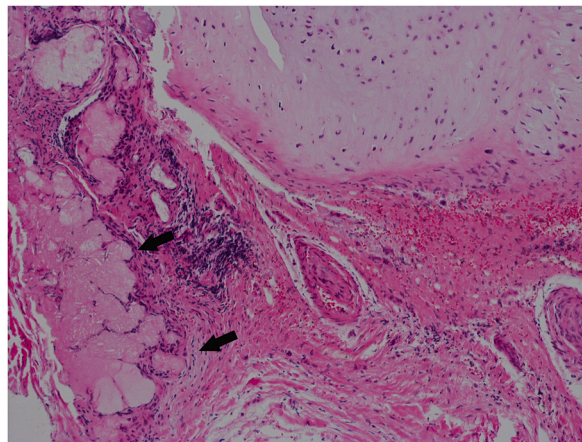


Fig. 4. Histologic section showing aggregations of crystals embedded into fibrocartilage tissue and chronic inflammation (Hematoxylin-eosin).

3. Discussion

CPPD crystal deposition disease of TMJ is rare, and approximately 60 cases have been reported to our knowledge [4]. Treatment for pseudogout should be related to the clinical manifestation of the condition and the severity of symptoms. We performed careful literature review starting over the last 30 years, searching for modalities of treatment of TMJ chondrocalcinosis. Pharmacological treatment is based on steroids, colchicine, nonsteroidal anti-inflammatory drugs (NSAIDs), triamcinolone, and acetylsalicylic acid, which can provide symptomatic relief for acute attacks of pseudogout with the sole involvement of synovial membrane and no bone erosion happening [8]. In literature surgery is reported as the preferred treatment of this pathological condition. Arthrocentesis is reported to have a role to reduce joint pressure resulting from inflammation as well as to lavage CPPD crystals and inflammatory agents out of the joint space for patients with more severe symptoms [9]. Arthroscopy is described as a treatment modality for TMJ chondrocalcinosis and allows to diagnose the pathology and to perform biopsies of intrarticular deposits. Arthroscopic findings commonly reveal fronds of thickened gray synovial tissue with white crystalline matter, which are typical of pseudogout in other joints [10]. However, the gold standard treatment for tophaceous pseudogout in presence of large deposits and massive involvement of peri-articular structures requires surgical excision to meticulously remove crystal deposits and should be performed due to potential for significant bony involvement [7,11]. In 2012 Zweifel and colleagues found 58 patients with reported cases of tophaceous pseudogout of the TMJ. Of these 58 patients, 33 patients received total removal of the lesion, with a good outcome. Literature reports several techniques, such as condylectomy and discectomy, which are frequently combined. In some cases, wide resection of the surrounding tissue can be required, including parotidectomy, middle ear resection and more invasive surgical approaches through a craniotomy. After excision, relief of symptoms and increased mouth opening are usually reported by patients. Mass resections may require grafting or prosthetic devices to reconstruct the joint. In the past years, reconstructive options with interposition materials such as Silastic block, Teflon implant and temporal fascia flap were described [12]. Different reconstructive options have been reported in literature: costochondral graft allows for autologous TMJ reconstruction but is associated with concomitant donor site morbidity and a risk of graft resorption or fibrosis, as well as higher instability. Kathju et al. report the use of a stock TMJ prosthesis placed for reconstruction. The TMJ prosthesis placed for reconstruction was a Christensen TMJ implant [13]. Recently, both Pellecchia and Ahmad K. Abou-Foul report, in two different studies, a case of tophaceous pseudogout affecting the TMJ with destruction of the condyle, glenoid fossa and middle cranial base involvement, that was reconstructed with a TMJ custom-made prosthesis in 2- staged surgical approach using a silicone spacer as a temporary space maintainer and in single approach [14,15]. Alloplastic reconstruction is useful for maintaining the patient's vertical mandibular height and normal occlusion, permitting immediate physiotherapy. Furthermore, no autologous component is required, decreasing surgical time and the possibility of donor site morbidity. In our case report, patient suffered of TMJ chondrocalcinosis with bony erosion of the glenoid fossa and protection of the middle cranial fossa contents was not guaranteed therefore a simple mass excision was not possible, but a reconstruction was mandatory. Modern three-dimensional (3D) computer-aided design (CAD) and computer-aided manufacturing (CAM) technologies are important to shape prostheses according to the native anatomy of the patient and allowed to perform a one-stage surgical approach by simultaneously planning resection of articular mass and joint reconstruction. For the presented case, after simulating virtual excision of the articular mass, we created prosthetic fossa with regard to the middle skull base and zygomatic arch anatomy. In particular, restoration of an extremely thinned glenoid fossa by a custom-made polyethylene neofossa was important to prevent condyle dislocation in the middle skull base, at the same time allowing to perform wide resection of the articular calcified mass. In addition, the neocondyle was modeled to fit the neofossa and was helpful to correct the posterior height defect that long-standing situation of edentulous jaws had caused. Another advantage supporting the use of custom-designed devices is the fact that stock prostheses might not be suitable to fit the distorted anatomy caused by massive calcification of articular surfaces and periarticular soft tissues.

4. Conclusion

Chondrocalcinosis is a rare disease caused by calcium pyrophosphate dihydrate crystal depositions causing structural damage to the joint and can cause associated TMJ symptoms. A case report is presented of a 67-year-old female diagnosed with right TMJ chondrocalcinosis and successfully treated by removal of the lesion and reconstruction of the right TMJ with a custom-fitted total joint prosthesis.

Proof consent

Formal consents are not required for the use of entirely anonymised images from which the individual cannot be identified.

Declaration of competing interest

The authors declare that they have no conflict of interest.

References

- [1] Ryan LM, Wortmann RL, Karas B, Lynch MP, McCarty DJ. Pyrophosphohydrolase activity and inorganic pyrophosphate content of cultured human skin fibroblasts. Elevated levels in some patients with calcium pyrophosphate dihydrate deposition disease. *J Clin Invest* 1986;77(5):1689–93. <https://doi.org/10.1172/JCI112487>.

- [2] Kudoh K, Kudoh T, Tsuru K, Miyamoto Y. A case of tophaceous pseudogout of the temporomandibular joint extending to the base of the skull. *Int J Oral Maxillofac Surg* 2017;46(3):355–9. <https://doi.org/10.1016/j.ijom.2016.08.018>.
- [3] Dijkgraaf LC, Liem RSB, de Bont LGM, Boering G. Calcium pyrophosphate dihydrate crystal deposition disease: a review of the literature and a light and electron microscopic study of a case of the temporomandibular joint with numerous intracellular crystals in the chondrocytes. *Osteoarthritis Cartilage* 1995;3(1):35–45. [https://doi.org/10.1016/S1063-4584\(05\)80036-6](https://doi.org/10.1016/S1063-4584(05)80036-6).
- [4] Ascani G, Pieramici T, Filosa A, Balercia P, Messi M. Pseudogout of the temporomandibular joint: a case report. *J Oral Maxillofac Surg* 2008;66(2):386–8.
- [5] Pritzker KP, Phillips H, Luk SC, Koven IH, Kiss A, Houpt JB. Pseudotumor of temporomandibular joint: destructive calcium pyrophosphate dihydrate arthropathy. *J Rheumatol*. doi:3(1):70–81.
- [6] Chuong R, Piper MA. Bilateral pseudogout of the temporomandibular joint. *J Oral Maxillofac Surg* 1995;53(6):691–4. [https://doi.org/10.1016/0278-2391\(95\)90173-6](https://doi.org/10.1016/0278-2391(95)90173-6).
- [7] Sklenicka S, Dierks EJ, Jarmin J, Miles C. Pseudogout of the temporomandibular joint: an uncommon cause of temporomandibular joint pain and swelling. *Oral Surg Oral Med Oral Pathol Oral Radiol Endod* 2011;111(6):709–14. <https://doi.org/10.1016/j.tripleo.2010.07.018>.
- [8] Nicholas BD, Smith JL, Kellman RM. Calcium pyrophosphate deposition of the temporomandibular joint with massive bony erosion. *J Oral Maxillofac Surg* 2007;65(10):2086–9. <https://doi.org/10.1016/j.joms.2006.02.030>.
- [9] Nakagawa Y, Ishii H, Shimoda S, Ishibashi K. Pseudogout of the temporomandibular joint. *Int J Oral Maxillofac Surg* 1999;28(1):26–8. [https://doi.org/10.1016/S0901-5027\(99\)80671-7](https://doi.org/10.1016/S0901-5027(99)80671-7).
- [10] Laviv A, Sadow PM, Keith DA. Pseudogout in the temporomandibular joint with imaging, arthroscopic, operative, and pathologic findings. Report of an unusual case. *J Oral Maxillofac Surg* 2015;73(6):1106–12. <https://doi.org/10.1016/j.joms.2014.12.041>.
- [11] Meul B, Ernestus K, Neugebauer J, Kuebler A. A case of chronic calcium pyrophosphate dihydrate crystal disease (tophaceous pseudogout) in the temporomandibular joint. *Oral Dis* 2005;11(2):113–5. <https://doi.org/10.1111/j.1601-0825.2004.01075.x>.
- [12] Zweifel D, Ettlin D, Schuknecht B, Obwegeser J. Tophaceous calcium pyrophosphate dihydrate deposition disease of the temporomandibular joint: the preferential site? *J Oral Maxillofac Surg* 2012;70(1):60–7. <https://doi.org/10.1016/j.joms.2011.06.207>.
- [13] Kathju S, Cohen R, Lasko L-A, Aynechi M, Dattilo DJ. In: Rosenthal EL, editor. Pseudogout of the temporomandibular joint: immediate reconstruction with total joint arthroplasty. *Head neck*; 2009. <https://doi.org/10.1002/hed.21074>. NA-NA.
- [14] Pellecchia R PR. Treatment of tophaceous pseudogout with custom-fitted temporomandibular joint: a two-staged approach. *Oral Maxillofac Surg Cases*. doi: 10.1016/j.
- [15] Abou-Foul AK, Saeed NR. Treatment of calcium pyrophosphate deposition in the temporomandibular joint with resection and simultaneous reconstruction using a custom joint prosthesis. *Oral Maxillofac Surg*. December 2019. <https://doi.org/10.1007/s10006-019-00825-7>.