

CASE REPORT

Placenta accreta in the first trimester: A case report

Elena De Gennaro¹  | Maria Orsaria² | Lorenza Driul¹

¹Clinic of Obstetrics and Gynecology, Hospital of Udine, DAME, University of Udine, Udine, Italy

²Institute of Pathology, Hospital of Udine, DAME, University of Udine, Udine, Italy

Correspondence

Elena De Gennaro, Clinic of Obstetrics and Gynecology, Hospital of Udine, University of Udine, Piazzale S. Maria della Misericordia, 33100 Udine, Italy. Email: degennaro.elena@spes.uniud.it

Abstract

Placenta accreta is a severe complication of pregnancy normally diagnosed during the second trimester. Early detection could reduce the risk of hemorrhage during abortion or miscarriage; however, guidelines on first-trimester diagnosis are lacking. We describe a case of placenta accreta during the first trimester with its sonographic and histological features.

KEYWORDS

abortion, first-trimester, hemorrhage, miscarriage, placenta accreta

1 | INTRODUCTION

Placenta accreta is a complication of pregnancy commonly diagnosed during the second trimester. Identifying it during the first trimester could prevent severe emergencies; however, a consensus on diagnostic criteria is lacking. We report a case of placenta accreta in the first trimester associated with miscarriage, and we highlight its features and complications.

Placenta accreta is a rare, potentially fatal disease of the pregnancy, characterized by an invasion of placenta into the myometrium, sometimes extending through the myometrium (placenta increta), or even reaching the uterine serosa (placenta percreta). The penetration of placenta into the myometrium leads to the failure of the placenta to separate from the uterus during the second stage of delivery, causing a severe post-partum hemorrhage with shock and coagulation disorders, and leading to emergent hysterectomy.¹

The incidence of placenta accreta has been increasing rapidly in the last years due to the high number of cesarean sections, surgery on the uterus, and the rising cases of advanced maternal age of pregnancy, all risk factors associated with placenta accreta.

The diagnosis of placenta accreta is often made during the second-trimester sonography, with sonographic signs including thin uterine-placental interface, vascular anechoic lacunae, and a turbulent blood flow.

Placenta accreta can also occur during the first trimester; however, it is much more difficult to diagnose because of the lack of standard sonographic guidelines. The diagnosis is often made by complication of miscarriage or abortion, for instance, massive blood loss during curettage. Here, we describe a case of placenta accreta during the first trimester with no risk factor associated.

2 | CASE PRESENTATION

A 33-year-old woman from Bangladesh, G3P2, presented to the emergency department referring to a 14-day history of vaginal bleeding and lower abdominal pain. Her last menstrual period was 7 weeks and 2 days before. Her menstrual cycles were usually regular, every 28 days, with a normal blood flow and duration of bleeding (about 5–6 days). Laboratory tests showed a β -human chorionic gonadotropin (β -hCG) of 129,725.4 mUI/ml. Her past medical and surgical history was unremarkable, she

This is an open access article under the terms of the Creative Commons Attribution-NonCommercial-NoDerivs License, which permits use and distribution in any medium, provided the original work is properly cited, the use is non-commercial and no modifications or adaptations are made.

© 2021 The Authors. *Clinical Case Reports* published by John Wiley & Sons Ltd.

didn't declare any illness nor did take any medications, she didn't undergo surgery. She had two previous spontaneous vaginal deliveries in 2009 for 35-week of gestation p-PROM with trachelorrhaphy and a full-term pregnancy in 2013 reportedly with no complications. Her last gynecological visit was in 2013. Pelvic examination showed a blood discharge from the cervix, and the uterus volume was as increased as in a 4 months-pregnancy, painless. Transvaginal sonography revealed no uterine pregnancy or ectopic pregnancies but confirmed an increased uterine size. The endometrium was hypervascularized (Figure 1), with anechoic lacunae and irregular thickness, measuring 15 mm at the fundus and 57 mm at the isthmus. No pelvic effusion.

The woman was admitted with a diagnosis of suspect molar pregnancy, for which curettage was indicated. Laboratory findings were Hb 11.2 g/dl, PLT 112×10^3 /mcl, D-dimer 5022 FEU ng/ml. During the operation, non-responsive massive hemorrhage (1200 cc in 5 min) required emergency laparotomy with hysterectomy and bilateral salpingectomy. Peritoneal cavity inspection revealed abnormalities in both shape and size of the uterus, with cervical and isthmic vascularization. The total blood loss was 2300 cc, and a consumptive coagulopathy soon developed, requiring a transfusion of 2 units of packed red cells and of colloid solutions. Blood testing during the operation returned Hb 10.2 g/dl, a drop of platelets to $76 \times 10^3/\mu\text{l}$, INR 1.23, Antithrombin 50%, Fibrinogen 117 mg/dl. First/day post-operative examinations showed an Hb 7.5 g/dl, PLT 83, Antithrombin 62%, D-dimer 1040 FEU ng/ml, β -hCG 25,199.8 mUI/ml.

The histopathology report described a 6 cm long hemorrhagic formation extending through 2/3 of the inferior portion of the uterus and invading beyond the external half of the myometrium, and a myometrial thinning over the isthmus, and reaching the internal os of the uterus

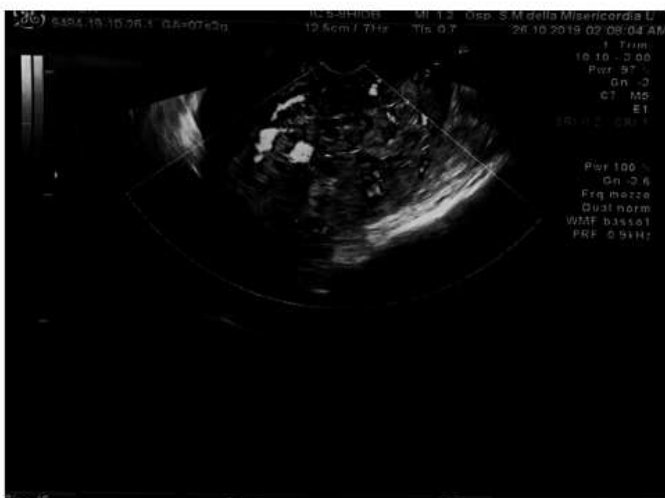


FIGURE 1 Sonographic features

(Figure 2). The microscopic examination revealed the presence of extravillous trophoblastic cells into the superficial myometrium and occasional chorionic villi attached to the myometrium (Figures 3–5). The diagnosis was a miscarriage with no alterations to the chorionic villi and with decidualization deficiency, suggestive of placenta previa accreta and uterine atony.

3 | DISCUSSION

The incidence of placenta accreta diagnosed in the first trimester has been increasing during the last decades. Major risk factors include previous cesarean section, advancing maternal age, and placenta previa. Other risk factors include curettage, IVF, and other types of uterine surgery.²

Placenta accreta is mainly diagnosed during the second and third trimesters of pregnancy, and sonographic signs include abnormally thin myometrium, absence of the dark line dividing placenta and the myometrium, supposing the loss of decidua basalis, bulging of the placenta into the bladder (especially in previous C-sections), placental lacunae with a chaotic, turbulent blood flow.³

Here, we have reported a rare case of placenta accreta in the first semester with no associated risk factors.

Similar to most of the cases reviewed by Wang et al.,⁴ the patient presented with vaginal bleeding followed by a massive hemorrhage after curettage. However, in opposition to previous reports, the patient had not undergone previous uterine surgery, therefore, was not supposed to have an increased risk of accretism. For this reason, a molar pregnancy was initially suspected on the basis of the patient's signs and symptoms.

Some main sonographic features described in other reports were present in our findings, such as anechoic lacunae and low-gestational sac implantation.

The massive hemorrhage brought to a rapid consumption of coagulation factors, and a coagulopathy was installed. This has also been seen in a case described by Papadakis et al.⁵ Although this is a complication of hemorrhage regardless of its cause, it is worth mentioning that treating placenta accreta should be considered an emergency and, therefore, the necessary personnel and resources, such as blood units and fresh frozen plasma, must be readily available.

A novelty in our report could be represented by the increase in placental size. However, the gestational age was only referred by the patient and could not be determined with certainty by crown-to-rump length because of the absence of an embryo, therefore, an increase in placental size can only supposedly be attributed to accretism.

Since preoperative β -hCG levels were high and no embryo was identified, differential diagnosis had to be

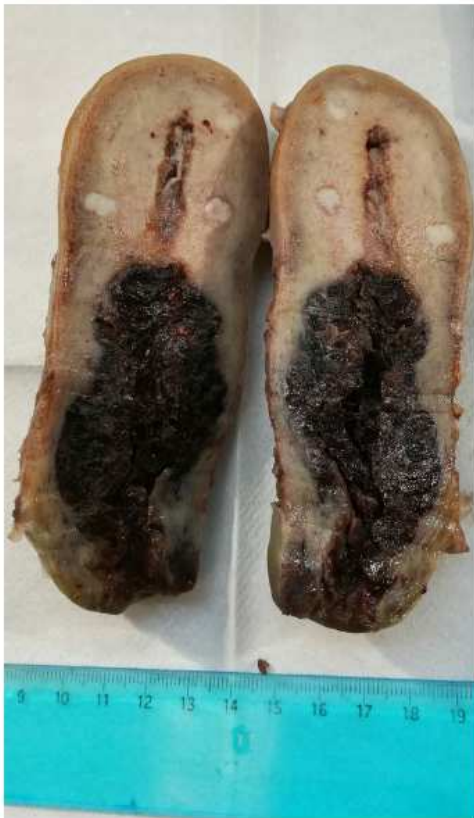

FIGURE 2 Macroscopy of the hysterectomy specimen. The placenta is located over the internal os (placenta previa) and a myometrial thinning is evident

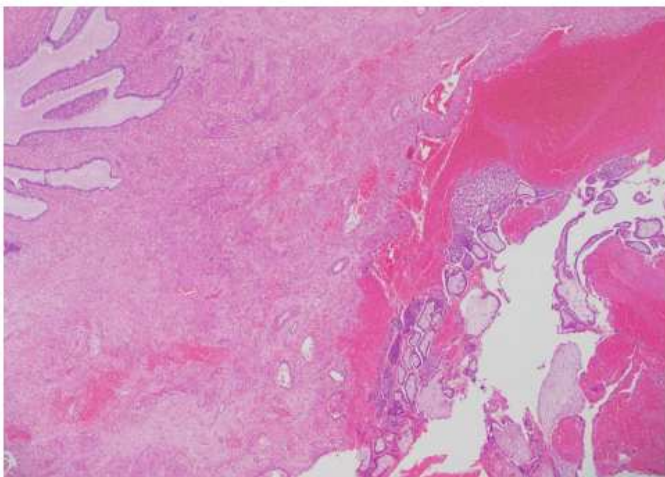


FIGURE 3 Histology. The placenta is located over the internal os with visible adjacent cervical glands (Hematoxylin-Eosin, 2x)

made with placental site trophoblastic tumor (PSTT) and invasive mole, based on histological features. Both are aggressive trophoblastic lesions with myometrial and/or vascular invasion. While they form a mass lesion involving and infiltrating endomyometrium, in this case, the placenta was attached to the myometrium with no signs of infiltration. Furthermore, chorionic villi did not have the classical findings of those in invasive mole or PSTT, such

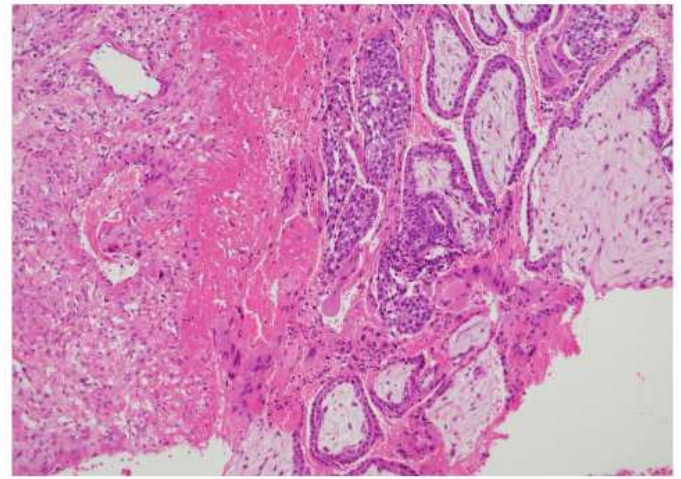


FIGURE 4 Histology. Presence of chorionic villi attached to the myometrium (Hematoxylin-Eosin, 10x)

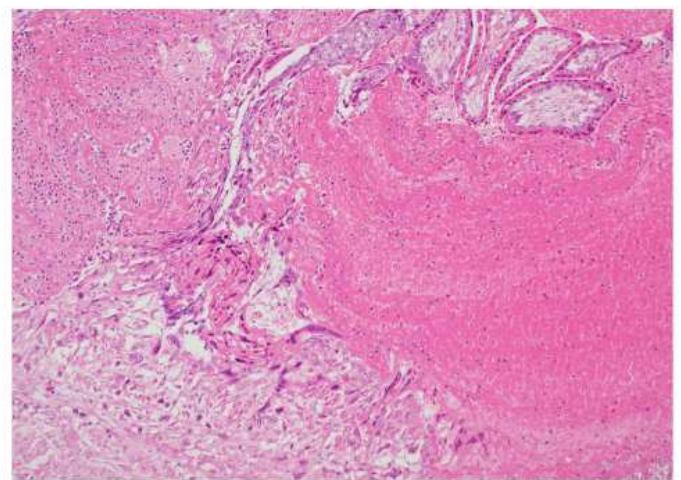


FIGURE 5 Histology. Presence of extravillous trophoblastic cells into the superficial myometrium; villi are present adjacent to fibrinoid; decidualization is deficient (Hematoxylin-Eosin, 10x)

as nuclear pseudoinclusions, and altered shape. Instead, decidualization was deficient, which is a risk factor for placental accretism.

There are no sonographic standardized criteria for the first-trimester placenta accreta because of its uncommon occurrence. Among reported sonographic criteria, there are low gestational sac implantation, presence of sub placental anechoic areas, and irregular placental-myometrium interface.⁶ MRI has been recommended to confirm a suspect of placenta accreta.⁷

Standardized procedures for the early diagnosis of placenta accreta could prevent obstetric emergencies in women at risk of abnormal placental invasion.

Although hysterectomy cannot be prevented entirely, more conservative treatments as uterine artery embolization, cytotoxic therapy with methotrexate, and hysterotomy with removal of the placenta⁴ can reduce bleeding and avoid emergencies. Increasing the reported cases of

placenta accreta can, therefore, improve the management of such cases and eventually lead to a broader consensus and standardized care.

ACKNOWLEDGMENT

Published with written consent of the patient.

CONFLICT OF INTEREST

None declared.

AUTHOR CONTRIBUTIONS

EDG: contributed to the evaluation and management of the patient, collected information, and was the writer of the manuscript. LD: contributed to the evaluation and management of the patient and reviewed the manuscript. MO: assessed the histopathology and reviewed the manuscript.

ETHICAL APPROVAL

Written informed consent for publication was obtained from the patient.

DATA AVAILABILITY STATEMENT

The data that support the findings of this study are available from the corresponding author upon reasonable request.

ORCID

Elena De Gennaro  <https://orcid.org/0000-0002-9190-0578>

REFERENCES

1. Wu S, Kocherginsky M, Hibbard JU. Abnormal placentation: twenty-year analysis. *Am J Obstet Gynecol*. 2005;192:1458-1461.
2. Jauniaux E, Jurkovic D. Placenta accreta: pathogenesis of a 20th century iatrogenic uterine disease. *Placenta*. 2012;33:244-251. <https://doi.org/10.1016/j.placenta.2011.11.010>
3. Comstock CH, Bronsteen RA. The antenatal diagnosis of placenta accreta. *BJOG*. 2014;121(2):171-182. <https://doi.org/10.1111/1471-0528.12557>
4. Wang Y-L, Weng S-S, Huang W-C. First-trimester abortion complicated with placenta accreta: a systematic review. *Taiwan J Obstet Gynecol*. 2019;58:10-14. <https://doi.org/10.1016/J.TJOG.2018.11.032>
5. Papadakis JC, Christodoulou N, Papageorgiou A, Rasidaki M. Placenta percreta presenting in the first trimester and resulting in severe consumption coagulopathy and hysterectomy: a case report. *Clin Exp Obstet Gynecol*. 2008;35:225.
6. Ballas J, Pretorius D, Hull AD, Resnik R, Ramos GA. Identifying sonographic markers for placenta accreta in the first trimester. *J Ultrasound Med*. 2012;31:1835-1841. <https://doi.org/10.7863/jum.2012.31.11.1835>
7. Matsubara S, Takahashi H, Takei Y. Magnetic resonance imaging for diagnosis of placenta accreta spectrum disorders: still useful for real-world practice. *Am J Obstet Gynecol*. 2018;219:312-313. <https://doi.org/10.1016/j.ajog.2018.04.058>

How to cite this article: De Gennaro E, Orsaria M, Driul L. Placenta accreta in the first trimester: A case report. *Clin Case Rep*. 2021;9:e04615. <https://doi.org/10.1002/ccr3.4615>