



Double trouble: Co-infection of *Angiostrongylus vasorum* and *Dirofilaria immitis* in golden jackal (*Canis aureus*) in Friuli Venezia Giulia, Italy

Massimo Orioles^a, Daniele Fabbri^a, Giovanna Miani^a, Stefano Pesaro^a, Luca Dorigo^b, Marco Bregoli^c, Elena Saccà^a, Paolo Tomè^a, Paola Beraldo^{a,*}

^a Dipartimento di Scienze AgroAlimentari, Ambientali e Animali, Università degli Studi di Udine, Via Sondrio, 33100, Udine, Italy

^b Museo Friulano di Storia Naturale, Via C.G. Sabbadini, 33100, Udine, Italy

^c Istituto Zooprofilattico Sperimentale delle Venezie, Viale dell'Università, 35020, Legnaro, Italy

ARTICLE INFO

Keywords:

Mesocarnivore
Cardiopulmonary nematodes
Pathology
Wildlife diseases

ABSTRACT

This study reports the first co-infection of *Angiostrongylus vasorum* and *Dirofilaria immitis*, two nematodes affecting canid cardiopulmonary systems, in golden jackals (*Canis aureus*) in Italy. Data on golden jackal carcasses, recovered in Friuli Venezia Giulia (Italy) from 2020 to 2023, were recorded using InfoFaunaFVG wildlife monitoring network. Out of 60 necropsied golden jackals, 24 tested positive for either pathogen, with 3 animals displaying co-infection. Pathological findings included verminous pneumonia, abdominal and thoracic bleeding, and adult individuals in the heart and pulmonary arteries. The recent expansion of the golden jackal in northern Italy may favour the establishment and spread of these nematodes, posing challenges for disease containment and surveillance. Given the increasing prevalence of angiostrongylosis and cardiopulmonary dirofilariosis in Europe, health monitoring of wild canids is essential to reduce their potential impact.

1. Introduction

The golden jackal (*Canis aureus*), a mesocarnivore, has recently experienced a rapid large-scale geographic expansion, originating in southeastern Europe and the Caucasus and expanding westward into the Balkans and parts of Central Europe (Ranc et al., 2022). This species established in Friuli Venezia Giulia (FVG), a region in north-eastern Italy, in the mid-1980s (Lapini et al., 2009). Several factors may be behind the recent expansion in distribution, primarily, changes in land use and absence of apex predators (Fabbri et al., 2014; Ranc et al., 2022). Alongside the expansion of golden jackal's range and density within FVG (Lapini et al., 2018) and the whole Italian peninsula, its epidemiological role as reservoir in the transmission of parasitic pathogens increases, justifying an intensification of health surveillance of this species. Parasitic infections, particularly helminths, are frequent in golden jackals and are reported across multiple locations (Gavrilović et al., 2019; Gherman and Mihalca, 2017; Veronesi et al., 2023). *Angiostrongylus vasorum* (Rhabditida, Metastrongylidae) and *Dirofilaria immitis* (Spirurida, Onchocercidae) are two of the prevalent nematodes affecting these canids. Both pathogens share target organs, clinical signs, and endemic region distribution in host species. Co-infection with

A. vasorum and *D. immitis* in golden jackals has been previously described in northern Serbia (Gavrilović et al., 2017), yet occurrence beyond this instance remains largely unreported. Hosts infected by *A. vasorum* may develop granulomatous pneumonia and inflammation during L1 migration in lung tissue, leading to symptoms such as gagging, coughing, dyspnea, and bleeding disorders (Koch and Willeßen, 2009). The prevalence of *A. vasorum* has increased in domestic and wild canids across Europe in recent decades, with some regions experiencing a fourfold increase in reported infections (Gillis-Germitsch et al., 2020). This nematode is present in Italy and angiostrongylosis has been recently confirmed in golden jackals in FVG (Beraldo et al., 2022).

D. immitis is the etiological agent of canine heartworm disease, primarily affecting dogs but also has a broad host range (wild canids, felids, mustelids, primates, marine mammals, rodents, and ungulates). The disease is characterized by vascular and pulmonary pathology, initiated by pulmonary endarteritis and progressing to pulmonary hypertension and right-sided congestive heart failure, which is a severe and potentially fatal condition (Morcón et al., 2022). Despite prevention and control efforts, particularly in dogs, canine heartworm disease has exhibited a northward expansion over the past decade, with the emergence of new endemic foci in Eastern and Northeastern Europe (Genchi

* Corresponding author. Dipartimento di Scienze AgroAlimentari, Ambientali e Animali (DI4A), Via Sondrio 2/A, Udine, 33100, Italy.

E-mail address: paola.beraldo@uniud.it (P. Beraldo).

<https://doi.org/10.1016/j.ijppaw.2024.100969>

Received 4 June 2024; Received in revised form 24 July 2024; Accepted 25 July 2024

Available online 26 July 2024

2213-2244/© 2024 Published by Elsevier Ltd on behalf of Australian Society for Parasitology. This is an open access article under the CC BY-NC-ND license (<http://creativecommons.org/licenses/by-nc-nd/4.0/>).

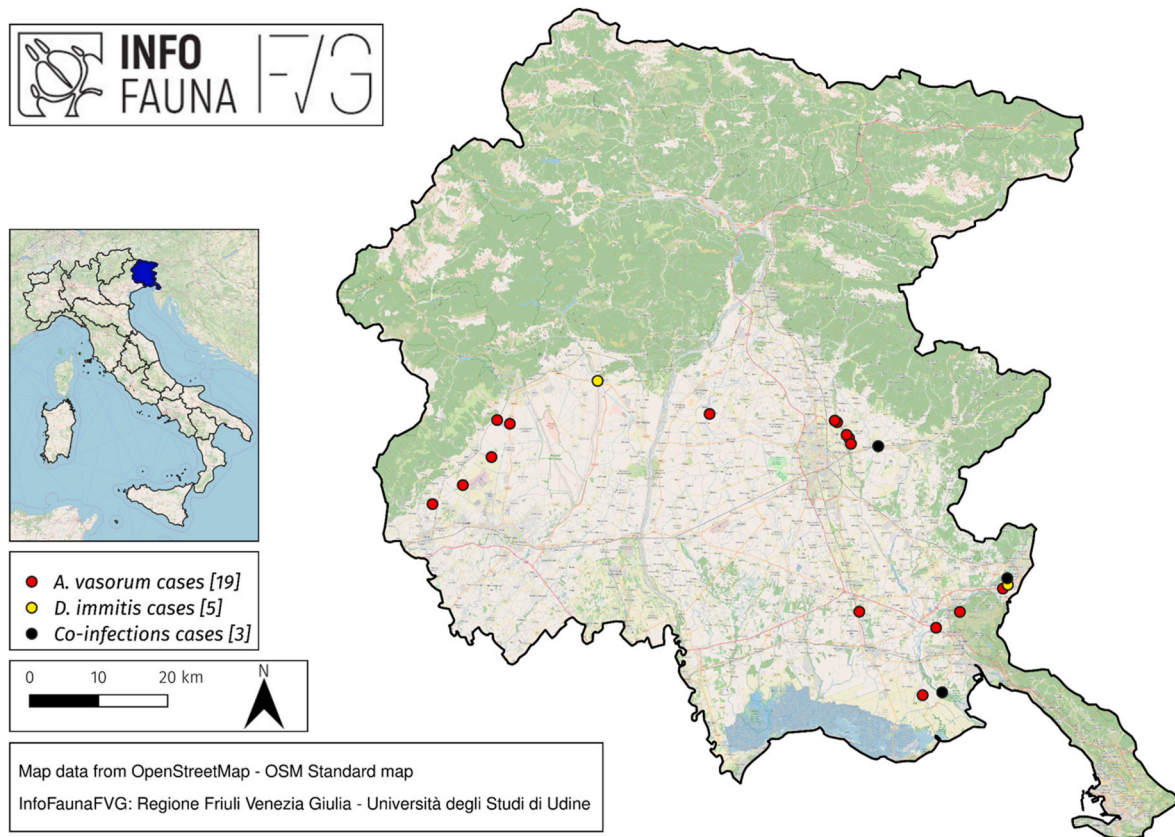


Fig. 1. Georeferencing of recovery sites of golden jackal infected by *A. vasorum* (red dots), *D. immitis* (yellow dots) and co-infections (black dots) in the period between 2020 and 2023 in FVG region.

and Kramer, 2020; Morchón et al., 2022). The expansion of potentially microfilaremic wild canids across Europe poses a significant risk for the dissemination of *D. immitis*, in association to the presence of competent vector mosquito species and favourable climatic conditions simultaneously. In that regard, the golden jackal might play a role in the transmission of this parasite due to the expected increase in its distribution in Europe and being a potential reservoir (Cunze and Klimpel, 2022). The highest prevalence of *D. immitis* infection in golden jackals has been recorded in Bulgaria, Serbia, Hungary, and Romania, with infection rates reaching up to 35% of the population (Veronesi et al., 2023). Jackals from these regions disperse significantly to new breeding areas, contributing to the spread of the infection. While *A. vasorum* infections have been previously reported in golden jackal in Italy, there are no reports of *D. immitis* infections. The aim of this study is to report the first cases of golden jackal co-infection of *A. vasorum* and *D. immitis* in Italy and to describe the parasitological and anatomopathological findings.

2. Material and methods

From January 2020 to December 2023, data regarding golden jackal carcasses retrieved in FVG were recorded in the InfoFaunaFVG regional wildlife health surveillance network (Tomè et al., 2023). Among 109 golden jackals (primarily killed by vehicle collision) undergoing necropsy, 60 animals were deemed suitable for anatomopathological and parasitological examinations of the cardiopulmonary system at the University of Udine, jointly with the Istituto Zooprofilattico Sperimentale delle Venezie and Museo Friulano di Storia Naturale (Udine). Heart, pulmonary arteries, and lungs were macroscopically examined for evidence of gross lesions and the presence of adult nematodes. Furthermore, the pulmonary vascular system was opened under a stereomicroscope and visible worms were extracted; additional adult

nematodes were also recovered after thoroughly washing lung tissue. The adults collected were identified based on their morphological and morphometric features, using keys published in the international literature (Costa et al., 2003; Furtado et al., 2010; Yamaguti, 1961). Lung and heart samples were collected, fixed in 4% buffered formaldehyde, and automatically processed for histopathological evaluation.

Parasites were morphologically identified and DNA was extracted using QIAmp DNA Mini Kit (Qiagen, Hilden, Germany) following the tissue protocol with 3 h of lysis in ATL buffer. The concentration and purity of the extracted DNA were assessed using a NanoDrop One spectrophotometer (Thermo Scientific, Waltham, MA, USA). Extracted DNA was then amplified in both directions using the same primers as for PCR using HotStartTaq Plus DNA Polymerase (Qiagen), and the reaction included: 2.5 µl of PCR buffer, 0.5 µl of dNTP mix, 0.75 µl of each forward and reverse primer, 0.125 µl of DNA polymerase, 15.4 µl of water and 5 µl of sample DNA. Thermal cycling conditions followed the manufacturer's instructions. The target gene was 18S rRNA (Forward primer: GGCGATCAGATACCGCCCTAGTT, Reverse primer: TACAAAGGGCAGGGACGTAAT; annealing temperature: 53 °C; amplicon length: 620 bp (Guardone et al., 2013). DNA amplification and amplicons dimensions were verified by 1.5% agarose gel and molecular weight standards. Amplified DNA was purified using QIAquick PCR Purification Kit (Qiagen) and the purified DNA was sent to be sequenced to Genewiz company (Leipzig, Germany). Parasite identification was made using by Mega-X software, 10.2.5 version, doing a Blast (NLM, Bethesda, USA) search on the alignments.

3. Results

Nematodes collected from the right ventricle and pulmonary arteries of golden jackals were identified on their morphological criteria as *A. vasorum* and *D. immitis*, and for the molecular identification, the

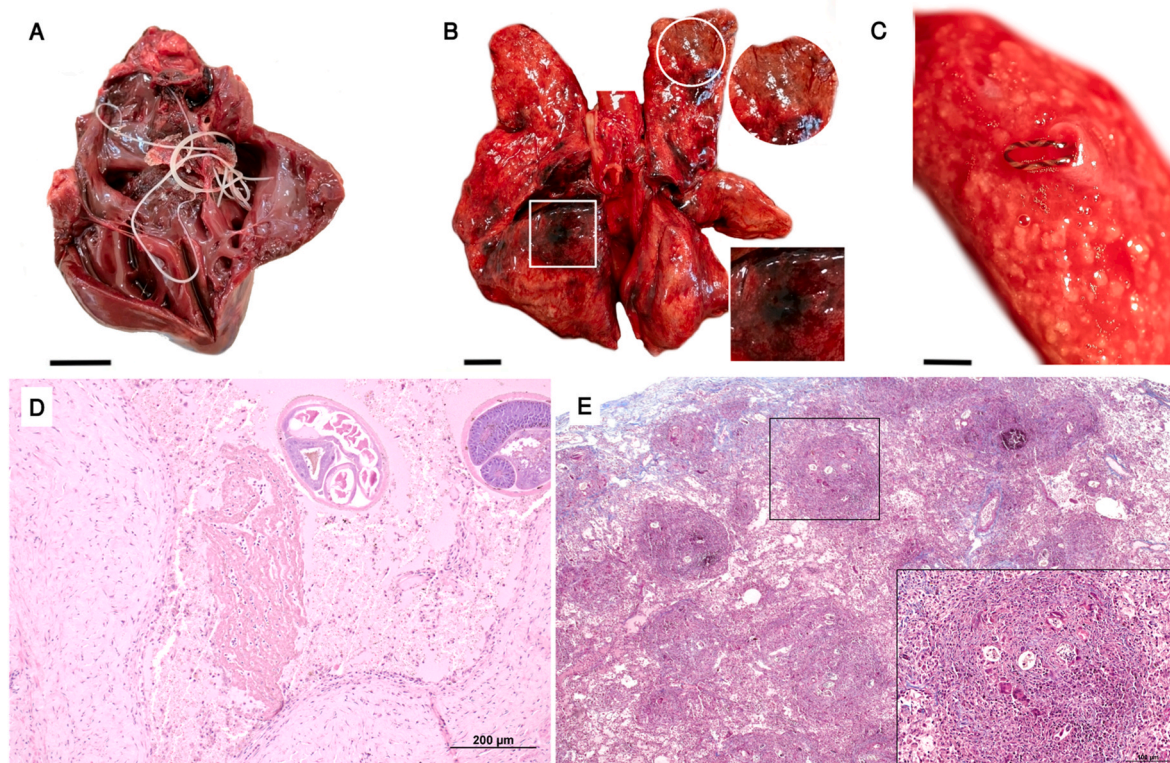


Fig. 2. Pathological findings in case of co-infection with *D. immitis* and *A. vasorum* in a golden jackal. (A) Presence of adult *D. immitis* within the right cardiac chambers (bar = 1 cm). (B) Lung parenchyma show multifocal poorly defined red to yellow-brown nodular firmer areas in the ventral edges of lung lobes (white circle and inset). Multifocal dark brown-black areas representing thrombotic infarcts are also often visible (white square and inset). (bar = 2 cm). (C) Female adult of *A. vasorum* nematode within a small pulmonary artery (bar = 1 cm). (D) Cross section of adult *A. vasorum* (black stars) and a thrombus (Th) in the lumen of a small pulmonary artery. Hematoxylin and eosin. (E) Lung parenchyma show multifocal granulomatous interstitial pneumonia. The granulomatous areas contained small central necrotic tissue and occasionally small, calcified areas. Giant macrophagic cells are visible within granulomatous areas (white circle). Embryonated eggs and first-stage larvae of *A. vasorum* are embedded within these inflammatory foci (black arrows). Masson's trichrome.

alignment percentage in Blast was greater than 99% for both *A. vasorum* and *D. immitis*.

Twenty-one out of 60 golden jackal specimens examined harboured either *A. vasorum* or *D. immitis* infections in their cardiopulmonary systems. Prevalence of *A. vasorum* and *D. immitis* was 31.7% (95% CI: 20.3–45.0) and 8.3% (95% CI: 2.0–18.4%) and mean intensity was 8 (95% CI: 3.42–18.2; range 1–56) and 4 (95% CI: 3–4.2; range 3–6) respectively. Notably, in the last two years, 3 out of 60 animals (all male adults) were co-infected with both *A. vasorum* and *D. immitis*. Fig. 1 depicts the recovery locations of all parasitized animals, including those co-infected in FVG region.

Macroscopic and microscopic lesions in the lung parenchyma were similar in all co-infected cases (Fig. 2). *D. immitis* adults were mainly located in the right heart atrium and ventricle and, in one case, in both heart and pulmonary arteries. *A. vasorum* adults were all recovered in lung arterial system. The infected lungs of golden jackals appeared generally haemorrhagic, with multifocal poorly defined red to yellow-brown nodular firmer areas in the ventral edges of lung lobes. The caudal lung lobes were most affected. Multifocal dark brown-black areas representing thrombotic infarcts were also often visible. Tracheobronchial lymph nodes were often haemorrhagic and oedematous. Commonly visible lesions included right-sided cardiomegaly with flaccid chambers. In one animal, with no evidence of head traumatic injury, the presence of diffuse haemorrhage within subdural meningeal was observed.

Most consistent microscopic findings were compatible with multifocal granulomatous interstitial pneumonia. The granulomatous areas contained small central necrotic tissue and occasionally small, calcified areas. Giant macrophagic cells were often visible within granulomatous

areas. Embryonated eggs and first-stage larvae of *A. vasorum* were often embedded within these inflammatory foci. The alveolar septa were thickened by lymphohistiocytic infiltration. In addition, adult nematodes were found in blood vessels concurrently with thrombotic lesions (Fig. 2). Proliferative villous endarteritis associated with the presence of *D. immitis* was also observed.

4. Discussion

Unsurprisingly, this report confirms that golden jackal is prone to potentially life-threatening cardiovascular and pulmonary complications due to co-infestations of *A. vasorum* and *D. immitis* parasites. The pathological findings observed align with previous studies, demonstrating typical lesions induced by these nematode species in other wild canids (Bourque et al., 2008; Gavrilović et al., 2014, 2017; Gredal et al., 2011; Mircean et al., 2017). Non-traumatic bleeding within the abdominal and thoracic cavities might stem from a multifactorial indirect response of the host to *A. vasorum* infection (Gillis-Germitsch et al., 2021), but other differentials are definitively possible.

Notably, the cases presented mark the first documented report of *D. immitis* infection of this species in Italy. Parasitological and anatomopathological findings described here corroborate the presence of sylvatic cycle for both angiostrongylosis and cardiopulmonary dirofilariosis in FVG, also confirming the epidemiological role of golden jackal for both etiological agents.

The golden jackal is an opportunistic omnivore, its diet is seasonally flexible and diverse, predominantly composed by animal-derived foods supplemented with fruits (Lange et al., 2021). Additionally, golden jackal often displays scavenging behavior, readily utilizing

anthropogenic food sources. This broad dietary niche, coupled with its extensive territorial mobility (ranging from 1 to 20 km²) and adaptability to novel habitats (including peri urban and urban environments), facilitates contact between golden jackals and synanthropic, domestic, and wild animals (Fenton et al., 2021).

The golden jackal may play a role as reservoir and bridge hosts for emerging parasites in Europe. The distribution expansion of this species may introduce parasites into new areas, facilitating transmission to sympatric domestic animals. Notably, some of these parasites have zoonotic potential, such as *D. immitis*, highlighting the importance of a One Health approach to their management. This approach is particularly relevant considering the ongoing environmental transitions driven by climate change, land-use alterations, habitat degradation, and the rewilding of urban spaces. To effectively address this challenge, broad surveys and continuous monitoring are crucial to elucidate the prevalence and epidemiology of both *A. vasorum* and *D. immitis* in golden jackals and other wild canids (e.g. foxes).

CRedit authorship contribution statement

Massimo Orioles: Writing – original draft, Investigation, Conceptualization. **Daniele Fabbri:** Writing – original draft. **Giovanna Miani:** Investigation. **Stefano Pesaro:** Resources. **Luca Dorigo:** Investigation. **Marco Bregoli:** Investigation. **Elena Sacca:** Investigation. **Paolo Tomè:** Visualization, Data curation. **Paola Beraldo:** Writing – review & editing, Methodology, Data curation.

Declaration of competing interest

The authors declare no conflict of interest.

Acknowledgements

We would like to thank Dr Isabella Perlin for her valuable help in collecting data during the necropsies of golden jackals and subsequently uploading them to InfoFaunaFVG. We would also like to thank all the students and trainees at the University of Udine for their help during the necropsies. This research did not receive any specific grants from public and commercial funding sources.

Appendix A. Supplementary data

Supplementary data to this article can be found online at <https://doi.org/10.1016/j.ijppaw.2024.100969>.

References

- Beraldo, P., Pesaro, S., Sacca, E., Dorigo, L., Lapini, L., Bregoli, M., Filacorda, S., 2022. First parasitological data of golden jackal (*Canis aureus moreoticus* I. Geoffroy saint hilaire, 1835) in Friuli Venezia Giulia region (FVG). In: Proceedings of the XXXII National Congress of the Italian Society of Parasitology, Napoli, Italy, pp. 27–30.
- Bourque, A.C., Conboy, G., Miller, L.M., Whitney, H., 2008. Pathological findings in dogs naturally infected with *Angiostrongylus vasorum* in Newfoundland and Labrador, Canada. *J. Vet. Diagn. Invest.* 20 (1), 11–20. <https://doi.org/10.1177/104063870802000103>.
- Costa, J.O., Costa, H.M., Guimaraes, M., 2003. Redescription of *Angiostrongylus vasorum* (baillet, 1866) and systematic revision of species assigned to the genera *Angiostrongylus* kamensky, 1905 and *angiocaulus* schulz, 1951. *Rev. Med. Vet.* 154, 9–16.
- Cunze, S., Klimpel, S., 2022. From the Balkan towards Western Europe: range expansion of the golden jackal (*Canis aureus*)—A climatic niche modeling approach. *Ecol. Evol.* 12 (7), e9141 <https://doi.org/10.1002/ece3.9141>.

- Fabbri, E., Caniglia, R., Galov, A., Arbanasić, H., Lapini, L., Bošković, I., Florijančić, T., Vlasseva, A., Ahmed, A., Mirchev, R.L., Randi, E., 2014. Genetic structure and expansion of golden jackals (*Canis aureus*) in the north-western distribution range (Croatia and eastern Italian Alps). *Conserv. Genet.* 15 (1), 187–199. <https://doi.org/10.1007/s10592-013-0530-7>.
- Fenton, S., Moorcroft, P.R., Čirović, D., Lanszki, J., Heltai, M., Cagnacci, F., Breck, S., Bogdanović, N., Pantelić, I., Ács, K., Ranc, N., 2021. Movement, space-use and resource preferences of European golden jackals in human-dominated landscapes: insights from a telemetry study. *Mamm. Biol.* 101 (5), 619–630. <https://doi.org/10.1007/s42991-021-00109-2>.
- Furtado, A.P., Melo, F.T.V., Giese, E.G., Santos, J. N. dos, 2010. Morphological redescription of *Dirofilaria immitis*. *J. Parasitol.* 96 (3), 499–504. <https://doi.org/10.1645/GE-2178.1>.
- Gavrilović, P., Blitva-Robertson, G., Özvegy, J., Kiskároly, F., Becskei, Z., 2014. Case Report of dirofilariasis in grey wolf in Serbia. *Acta Parasitol.* 60 (1), 175–178. <https://doi.org/10.1515/ap-2015-0025>.
- Gavrilović, P., Marinković, D., Todorović, I., Gavrilović, A., 2017. First report of pneumonia caused by *Angiostrongylus vasorum* in a golden jackal. *Acta Parasitol.* 62 (4), 880–884. <https://doi.org/10.1515/ap-2017-0107>.
- Gavrilović, P., Marinković, D., Vidanović, D., Dobrosavljević, I., Gavrilović, A., 2019. Are golden jackals (*Canis aureus*) definitive hosts for *Angiostrongylus vasorum*? *Transbound. Emerg. Dis.* 66 (6), 2305–2310.
- Genchi, C., Kramer, L.H., 2020. The prevalence of *Dirofilaria immitis* and *D. repens* in the old world. *Vet. Parasitol.* 280, 108995 <https://doi.org/10.1016/j.vetpar.2019.108995>.
- Gherman, C.M., Mihalca, A.D., 2017. A synoptic overview of golden jackal parasites reveals high diversity of species. *Parasites Vectors* 10, 1–40.
- Gillis-Germitsch, N., Kockmann, T., Asmis, L.M., Tritten, L., Schnyder, M., 2021. The *Angiostrongylus vasorum* Excretory/Secretory and Surface Proteome contains putative modulators of the host coagulation. *Front. Cell. Infect. Microbiol.* 11 <https://doi.org/10.3389/fcimb.2021.753320>.
- Gillis-Germitsch, N., Tritten, L., Hegglin, D., Deplazes, P., Schnyder, M., 2020. Conquering Switzerland: the emergence of *Angiostrongylus vasorum* in foxes over three decades and its rapid regional increase in prevalence contrast with the stable occurrence of lungworms. *Parasitology* 147 (10), 1071–1079. <https://doi.org/10.1017/S0031182020000700>.
- Gredal, H., Willesen, J.L., Jensen, H.E., Nielsen, O.L., Kristensen, A.T., Koch, J., Kirk, R. K., Pors, S.E., Skerriit, G.C., Berendt, M., 2011. Acute neurological signs as the predominant clinical manifestation in four dogs with *Angiostrongylus vasorum* infections in Denmark. *Acta Vet. Scand.* 53 (1), 43. <https://doi.org/10.1186/1751-0147-53-43>.
- Koch, J., Willesen, J.L., 2009. Canine pulmonary angiostrongylosis: an update. *Vet. J.* 179 (3), 348–359. <https://doi.org/10.1016/j.tvjl.2007.11.014>.
- Lange, P., Lelieveld, G., De Knecht, H.J., 2021. Diet composition of the golden jackal *Canis aureus* in south-east Europe – a review. *Mamm. Rev.* 51 (2), 207–213. <https://doi.org/10.1111/mam.12235>.
- Lapini, L., Dreon, A., Caldana, M., Villa, M., Luca, M., 2018. Distribuzione, espansione e problemi di conservazione di *Canis aureus* in Italia (Carnivora: Canidae). *Distribution, expansion and conservation of Canis aureus in Italy (Carnivora: Canidae)*. Quaderni del Museo Civico di Storia Naturale di Ferrara 6, 89–96.
- Lapini, L., Molinari, P., Dorigo, L., Are, G., Beraldo, P., 2009. Reproduction of the golden jackal (*Canis aureus moreoticus* I. Geoffroy Saint Hilaire, 1835) in Julian pre-Alps, with new data on its range-expansion in the high-Adriatic hinterland (Mammalia, Carnivora, Canidae). *Boll. Mus. civ. St. nat. Venezia* 60, 169–186.
- Mircean, M., Ionică, A.M., Mircean, V., Györke, A., Codea, A.R., Tăbăran, F.A., Taulescu, M., Dumitrache, M.O., 2017. Clinical and pathological effects of *Dirofilaria repens* and *Dirofilaria immitis* in a dog with a natural co-infection. *Parasitol. Int.* 66 (3), 331–334. <https://doi.org/10.1016/j.parint.2017.02.003>.
- Morchón, R., Montoya-Alonso, J.A., Rodríguez-Escobar, I., Carretón, E., 2022. What has happened to heartworm disease in Europe in the last 10 years? *Pathogens* 11, 1042. <https://doi.org/10.3390/pathogens11091042>.
- Ranc, N., Acosta-Pankov, I., Baly, V., Bučko, J., Čirović, D., Fabijanić, N., Filacorda, S., Giannatos, G., Guimaraes, N., Hatlauf, J., Heltai, M., Ionescu, O., Ivanov, G., Jansman, H., Kowalczyk, R., Krefel, M., Kutal, M., Lanszki, J., Lapini, L., et al., 2022. Distribution of large carnivores in Europe 2012–2016: distribution map for golden jackal (*Canis aureus*). *Zenodo*. <https://doi.org/10.5281/zenodo.6382216>.
- Tomè, P., Pesaro, S., Orioles, M., Pascotto, E., Cadamuro, A., Galeotti, M., 2023. InfoFaunaFVG: a novel progressive web application for wildlife surveillance. *Eur. J. Wildl. Res.* 69 (2), 38. <https://doi.org/10.1007/s10344-023-01664-4>.
- Veronesi, F., Deak, G., Diakou, A., 2023. Wild mesocarnivores as reservoirs of endoparasites causing important zoonoses and emerging bridging infections across Europe. *Pathogens* 12 (2). <https://doi.org/10.3390/pathogens12020178>. Article 2.
- Yamaguti, S., 1961. *Systema Helminthum. The Nematodes of Vertebrates, Pt. II & I, vol. III*. Interscience Publishers, New York & London.